

A Rare Case of Ventricular Standstill and High-Grade AV Block in Patient with Thyrotoxicosis

Achmad Bima Aryaputra¹, Hendry Purnasidha Bagaswoto²

Abstract

Background: Loss of consciousness by the decrease in cardiac output can be caused by high-grade AV Block, ventricular tachycardia, and one of the uncommon causes, ventricular standstill. Even though these disorders are commonly caused by ischemic heart disease, we discovered this condition in patients with hyperthyroidism. Although thyrotoxicosis is commonly presented as tachycardia, it's unusual for AV blocks to occur, especially a high-grade one.

Case Illustration: A 45-year-old female was admitted with fatigue, dizziness, and recurrent episodes of unconsciousness. She had a history of hyperthyroid, routinely managed with Propylthiouracil and Propranolol. Physical examination showed HR: 30 x/min, and other unremarkable systemic examinations. Initial ECG showed 3:1 AV Block. The patient was managed with Dopamin and moved to the ICU for further observation. In the ICU, suddenly she had a seizure, her monitor showing P waves with an absence of ventricular activity lasting for a few seconds. Due to the condition of ventricular standstill, a Temporary Pacemaker (TPM) was installed urgently, so the patient's vital sign was stable with a pacing rhythm. We found a Free Thyroxine (T4) level of 46.85 pmol/l, TSH of 0.005 uIU/ml, and unremarkable echocardiographic findings. Considering these results, we suspect that the cause of the ventricular standstill was due to thyrotoxicosis. Propylthiouracil and dexamethasone were given to manage the disease. After 7 days of treatment, she was discharged with sinus rhythm on her ECG.

Conclusion: Ventricular standstill is frequently associated with conduction blockages, but it can sometimes occur without them. Ventricular standstill treatment often necessitates the use of temporary pacing wires or a pacemaker. In thyroid crises, high-degree AV-block is uncommon, but when the euthyroid condition is restored, clinical status and conduction problems can be reversible.

(Indonesian J Cardiol. 2022;43:159-167)

¹ General Practitioner RSU Islam Klaten, Klaten, Indonesia.

² Department of Cardiology and Vascular Medicine, Faculty of Medicine, Public Health, and Nursing, Universitas Gadjah Mada – Dr. Sardjito Hospital, Yogyakarta, Indonesia.

Correspondence:

Hendry Purnasidha Bagaswoto,

Department of Cardiology and Vascular Medicine, Faculty of Medicine, Public Health and Nursing, Universitas Gadjah Mada-Dr Sardjito General Hospital, Yogyakarta, Indonesia.

Email: arsyadhiracarissa@gmail.com

Keywords: Ventricular standstill, AV Block, Thyrotoxicosis, Pacemaker.

Introduction

Ventricular standstill can manifest as seizure-like activity and unconsciousness that can cause diagnostic dilemmas as reported by Adegoke in 2020. Misdiagnosing cardiac arrhythmia for epilepsy could lead to severe consequences for the patient.¹ If not treated promptly, ventricular standstill (also known as ventricular asystole) is a potentially fatal arrhythmia. The absence of any ventricular activity despite the presence of atrial activity, with or without ventricular escape rhythm, is a typical ECG presentation of a ventricular standstill.² As the name suggests, the ventricles come to a standstill with an almost immediate cessation of cardiac output, the patient will lose consciousness and with no palpable pulse. If this persists for more than a few seconds, cardiopulmonary resuscitation may be needed.³ If the return of circulation is achieved, pacemaker insertion is usually required.⁴

Today, the prevalence of ventricular standstill is unclear. However, it has been noted in several case reports. Ventricular standstill occurs in the presence of profound vagal tone caused by massive bleeding,⁵ REM sleep,⁶ pregnancy, Takotsubo cardiomyopathy, pre-existing high-degree AV block, masquerading as ventricular fibrillation, and digoxin toxicity.⁷ Thyrotoxicosis or hyperthyroidism is commonly presented as tachycardia, sweating, and palpitation. It's quite unusual for hyperthyroidism to present as bradycardia due to an AV Block, especially a high-grade one.⁸

We present an interesting case of a patient with a history of hyperthyroidism, who was presented with recurring episodes of unconsciousness with a high-grade AV Block on initial ECG. She suffered seizures and unconsciousness during her hospital stay with the monitor displayed P waves with no QRS complex, reflecting a condition of Ventricular Standstill

Case Presentation

Mrs. B, a 45-year-old female was admitted to ER with the chief complaint of dizziness. Over the last 9 hours, she had a recurrent episode of syncope lasting for several seconds, accompanied by diaphoresis. She also felt breathlessness even on rest. There's neither nausea, chest pain, nor vomiting reported. She had a

history of hyperthyroid for a long time, but she didn't take medicine routinely, and the last time she visited her doctor for hyperthyroid medication was 1 and a half years before admission. The patient came to our hospital in the internal medicine clinic 12 days before her admission to the Emergency Room, at that time she had her first PTU and propranolol after a long time of abstinence. The last routine check-up was 4 days prior. On arrival, the patient was fully alert, Vital signs showed a heart rate of 30 bpm, blood pressure of 120/87 mmHg, respiration rate of 24 x/min, and peripheral oxygen saturation was 99%. Heart examination revealed normal first and second heart sounds. Lung examination revealed vesicular pulmonary sounds on both lungs. Abdominal and extremity examination finding was unremarkable. Initial lab workup revealed a normal electrolyte level (**Table 1**). Initial ECG showed sinus rhythm with 3:1 AV Block, a high-grade AV Block. Due to the condition of unstable bradycardia, propranolol was discontinued and 1 mg of atropine sulfate was given but showed no response. When we switched to Dopamin maintained at 5 mcg/kg/min, there was an improvement in hemodynamic profile. Then, the patient was transferred to ICU for further observation.

A few hours later in ICU, suddenly she had an episode of clonic seizure with the bedside monitor showing P waves with an absence of QRS complex. This phenomenon lasted for a few seconds and was

Table 1. Complete laboratory findings.

Laboratory variable	Result	Unit
Haemoglobin	10.5	g/dL
Leukocyte	16.6	10 ³ /uL
Thrombocyte	318	10 ³ /uL
Ureum	38	mg/dL
Creatinin	1.3	mg/dL
Sodium (Na)	138	mmol/L
Potassium (K)	4.23	mmol/L
Chloride (Cl)	108	mmol/L
Blood glucose	344	Mg/dL
HbA1c	7.00	%
Free T4	46.85	pmol/l
TSH	<0.005	uIU/ml
Troponin I	20	ng/L

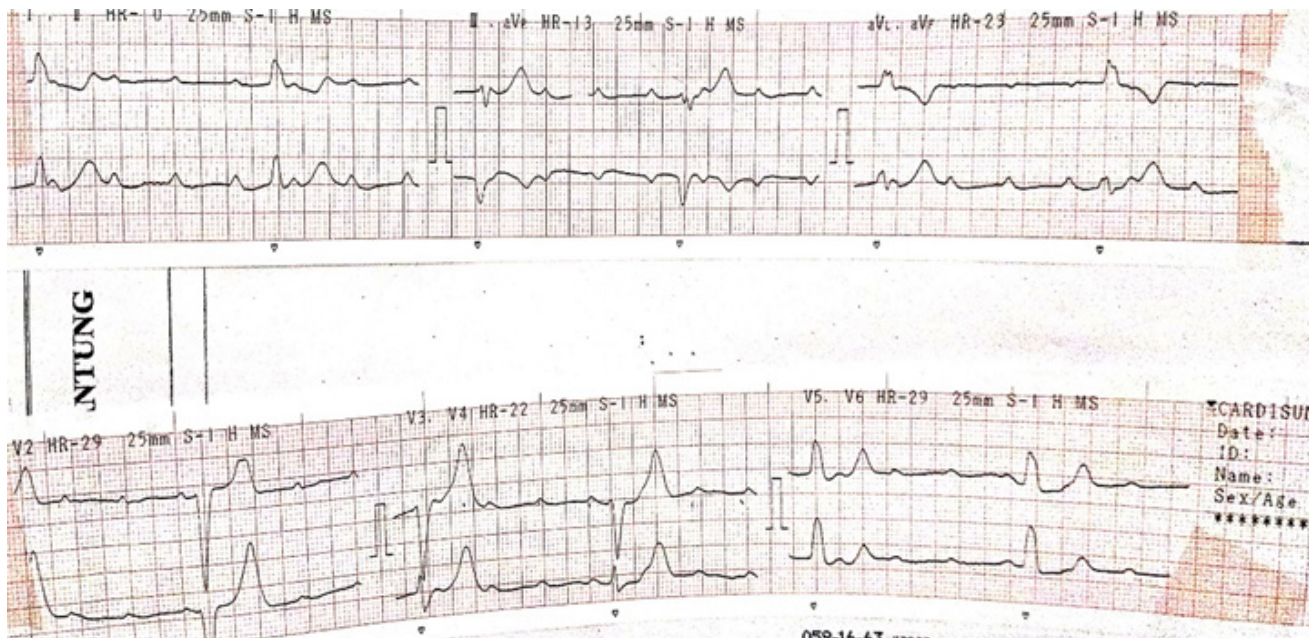


Figure 1. Initial ECG showed sinus rhythm, normoaxis, with 3:1 AV Block, a high-grade AV Block.

consistent with Ventricular Standstill. After the seizure ceased, the pulse was returned. The bedside monitor showed sinus rhythm with a high-grade AV Block. Due to the condition of the ventricular standstill, a Temporary Pacemaker (TPM) was installed urgently on the apex of the right ventricle with an initial setting of Threshold 0.8 mA, HR 80 bpm, output 2 mA, sensitivity 2 mA. After the TPM installation, the patient was stabilized with a pacing rhythm on ECG. We did further investigation to find the source of the Ventricular Standstill. Echocardiography showed normal cardiac dimension, ejection fraction of 67%, TAPSE of 12 mm, global neurokinetic, and no structural heart disease was found. Further laboratory tests revealed a Free thyroxine (T4) level of 46.85 pmol/l (normal 9.0-20.0) and a TSH level of <0.005 uIU/ml (normal 0.27-4.70). From these findings, we suspect that the thyroid level was the cause of the ventricular standstill. Thus propylthiouracil and dexamethasone were given to manage the disease.

A day after the start of thyroid therapy, we tried to taper off the TPM rate and the patient seemed to have adapted well, showing a good outcome of the thyroid therapy. A day later, when TPM was uninstalled, the ECG showed a sinus rhythm AV Block grade 1. After a total of six days of treatment, she was discharged with

sinus rhythm on her ECG. She was monthly controlled in the outpatient clinic and for 3 months after being discharged from the hospital, she had no complaints about dizziness or syncope.

Discussion

We found the episode of seizure and loss of consciousness for a few seconds caused by a ventricular standstill. Ventricular standstill is a potentially lethal electrophysiological phenomenon when ventricles stop beating and result in decreasing cardiac output and perfusion leading to an episode of syncope. However, if it is persistent for more than a few seconds, it can progress to cardiovascular collapse and sudden cardiac death.⁹ Our patient was having brief periods of ventricular standstill presenting as seizure-like activities, while the monitor showed multiple P waves without the QRS complex following. The Same pattern was found by Adegoke and Moles whereas it's important to distinguish ventricular standstill from a neurologic disorder to prevent a misdiagnosis.^{1,10} The ECG may show that after the atrial depolarization, the depolarization and repolarization of the ventricular fail to present. Episodes of ventricular

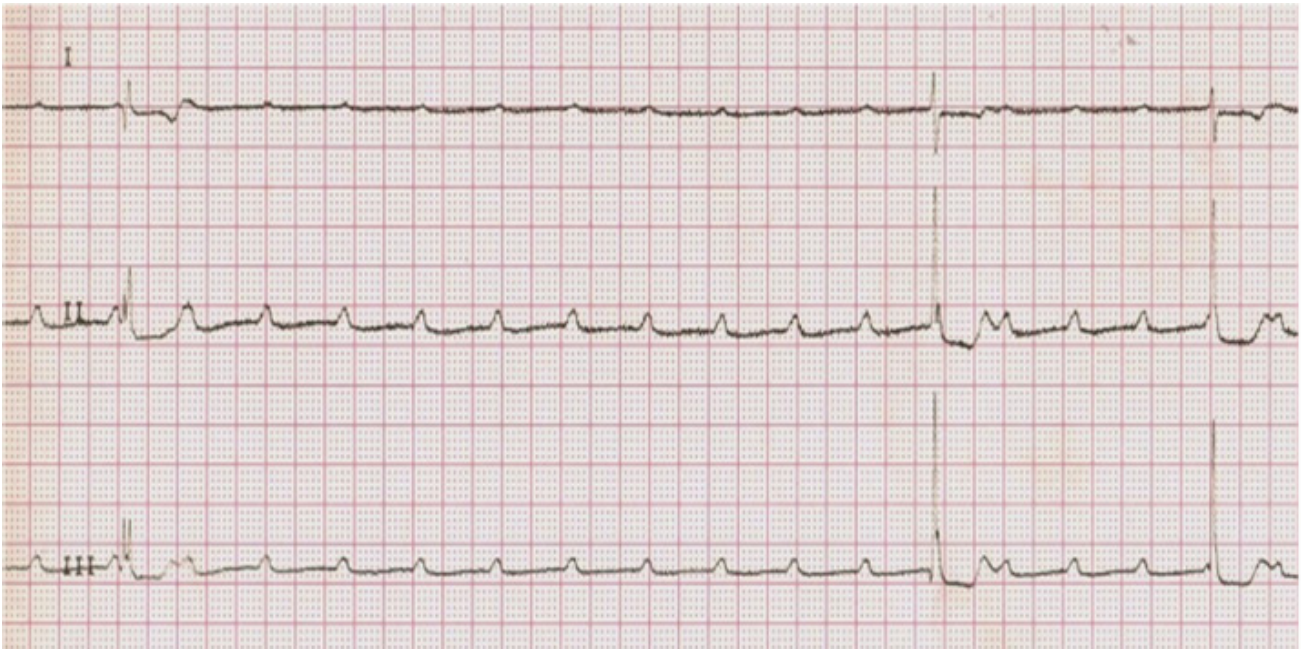


Figure 2. Monitor capture of Ventricular standstill, showing P waves without QRS Complex followed for a few seconds.

standstill are so transient that in most cases, any clinical evidence of absence of pulse is often not confirmed before the patient makes a full neurological or cardiac recovery.⁷

AV Block and Thyrotoxicosis

Thyrotoxicosis is commonly presented as sinus tachycardia or atrial fibrillation due to the intrinsic effect of thyroxine in SA Node. It affects the heart in adrenergic, chronotropic, and inotropic ways. Though the mechanisms of tachyarrhythmias in hyperthyroidism are well established, the mechanism of hyperthyroidism-related bradyarrhythmia and AV block are less well understood.⁸ The majority of complete heart block cases associated with thyrotoxicosis have been associated with additional risk factors for conduction abnormalities, such as concomitant cardiac anomalies, digoxin use, and electrolyte abnormalities including hypercalcemia and hypokalemia. However, in some cases, no underlying disease was discovered and subsequent treatment of the thyrotoxicosis resulted in restoration of normal AV conduction.¹¹ Interestingly, our patient lacked any of the previously identified risk factors for the development of complete heart block associated with thyrotoxicosis.

The data in the literature that address the

pathogenesis of high-grade AV block in the context of hyperthyroidism are primarily speculative. Some autopsies found on patients with thyrotoxicosis were pretty intriguing. Autopsies in patients with hyperthyroidism with prolongation of PR Interval during hospitalization and mimicking clinical presentation on VS, revealed a continuous interstitial inflammation of the AV-node, the bundle branches, and most severely of the His-bundle, and fibrosis of the endocardium.¹² Another post-mortem autopsies in a patient with severe thyrotoxicosis with no pre-existing cardiac anomaly, showed myocyte hypertrophy, myocyte necrosis, interstitial and perivascular fibrosis, and myocardial edema, which has been postulated to result in AV block.¹³ Our patient had a 3:1 AV Block, a high-grade AV Block based on the criteria of AHA.⁴ This condition may be caused by inflammation or fibrosis of cardiac tissue.

One study, by Ozcan and colleagues, monitored 21 patients with AV block associated with hyperthyroidism, of whom 20 patients (95.2%) underwent pacemaker implantation. TSH level was normalized in seven patients, and 3 of those patients had resolved AV block. Meanwhile, 12 patients had persistently low TSH levels despite the treatment and all of those patients had persistent AV block during the initial hospital follow-

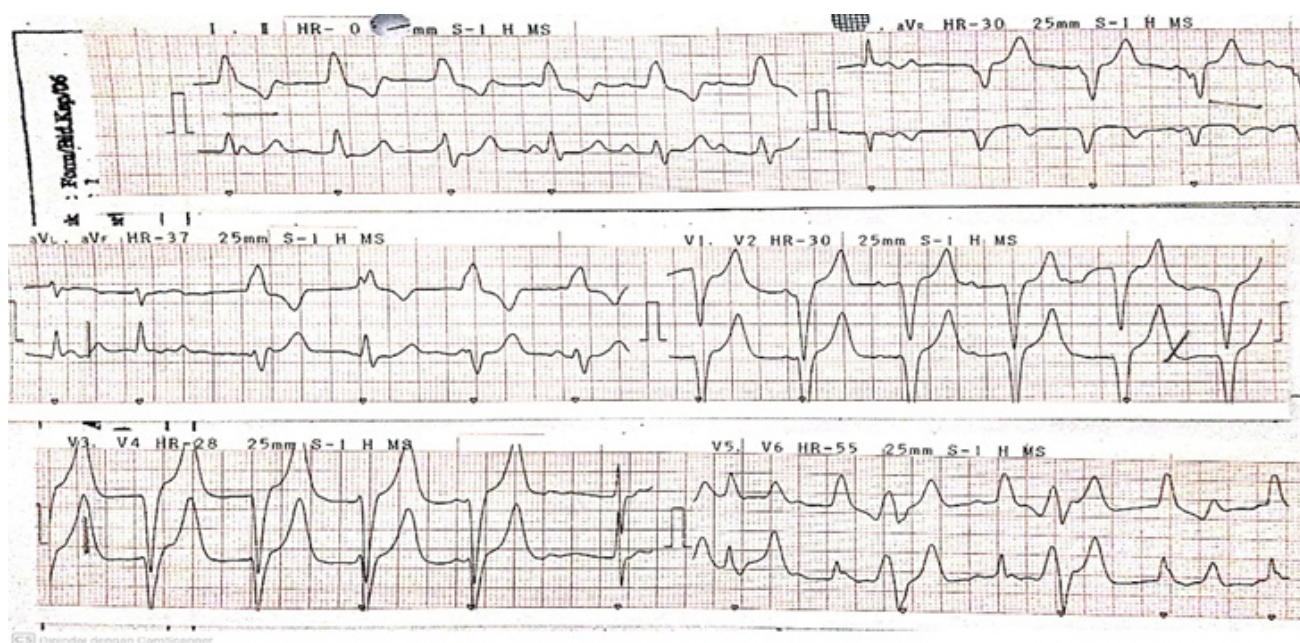


Figure 3. ECG after the temporary pacemaker was installed showing a pacing rhythm.

up period (21 days). Because of the small sample size and short follow-up period in this study, it needs to be replicated in bigger populations in the future. If thyroid dysfunction medication does not improve AV block, there are two possibilities: no relationship to thyroid dysfunction or irreparable harm caused by the disease.¹⁴

Ventricular Standstill

The mechanism of ventricular standstill entails either an absence of supra-ventricular conduction or a complete conduction failure between the AV node and the His-Purkinje system. During complete AV Block, an electrical impulse from the sinus was blocked, so the idioventricular pacemaker played a role by its automaticity trait to sustain the contractility of the ventricle. The Purkinje fibers can become automatic under abnormal conditions (e.g.: complete AV block), but their pacemaker activity is vulnerable to those influences that normally keep it in check. Because of this, the Purkinje fibers may produce too slow discharge or fail to discharge, and then a ventricular standstill occurs. Some of the factors that were responsible for this incident, presumably, were damaged specialized tissue, ionic concentrations, overdrive suppression, administration of drugs, or vagal reflex.²

Taking an example from sick sinus syndrome, the sinus arrest is often not terminated by the ventricular escape but instead by a resumed sinus beat. Therefore, a decrease in sinus node activity may involve a complete cardiac standstill. The finding implies that the structural damage involves not only the sinus node but subsidiary pacemakers as well. Similarly, if the idioventricular pacemakers are physically or functionally disrupted, an abrupt block of AV conduction may not be accompanied by ventricular escape. Even if the idioventricular pacemakers do commence spontaneous discharge, it may be too sluggish to avoid anoxia, which could exacerbate the condition. Excitation of the vagus nerve will show such a depression if ventricular automaticity is depressed, and in certain cases may even contribute to it.²

One of the postulated causes of the ventricular standstill was electrolyte imbalance. One element that decreases the slope of the diastolic potential is a higher extracellular potassium concentration. As indicated during vagal stimulation, a decrease in idioventricular automaticity is one of the first events induced in vivo by a progressively increasing plasma potassium level. By shifting the threshold to a less negative potential, a high level of calcium ion [Ca] has been reported to increase overdrive suppression and lower the spontaneous rate of

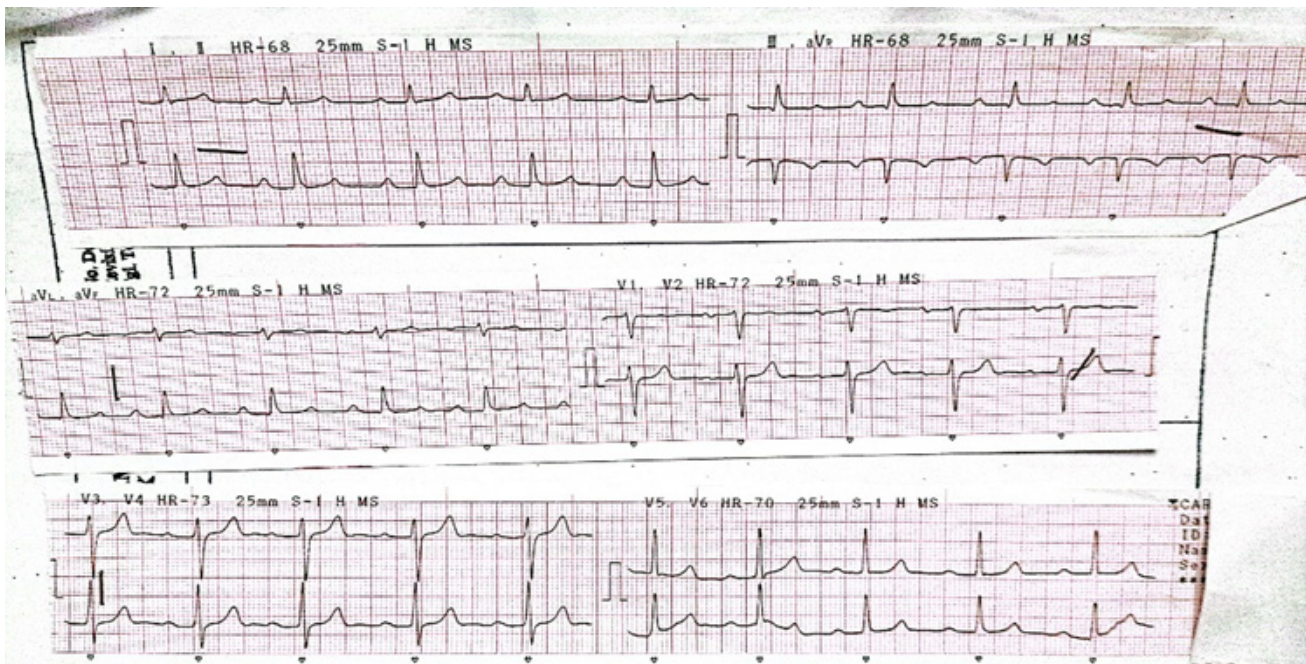


Figure 4. Resting ECG after the temporary pacemaker was uninstalled, showing sinus rhythm with AV Block gr 1.

Purkinje fibers perfused in vitro.²

A ventricular standstill can be the result of an exaggeration of the normal inhibitory process when the idioventricular pacemaker (slower rate) was suppressed by the sinoatrial pacemaker (the faster rate, namely, overdrive suppression). This can happen because the overdriven tissues are diseased, or because the factors that promote overdrive suppression are exaggerated (by hyperkalemia, alkalosis, anoxia, hypothermia, obstructive jaundice) causing a reduction in idioventricular automaticity before the occurrence of overdrive, or factor that oppose overdrive suppression are inhibited (decrease in adrenergic action). Overdrive suppression becomes more pronounced in the presence of adrenergic blockade (particularly in β -blocker consumption) and is significantly reduced when the sympathetic nerves are excited or catecholamines are given. As long as the sinus node rhythm is present and the Purkinje fibers are only involved in conducting impulses, substances that lower idioventricular automaticity by overdrive suppression may not affect the heart's performance. If AV block occurs, however, the increased suppression will manifest as ventricular arrest.²

Some case reports describe ventricular standstill and AV block induced by vagal reflex. Latt et al report a case

of ventricular standstill that happened in a patient with severe gastrointestinal bleeding. As a result, in the case of acute GI hemorrhage and severe anemia, elevated vagal cholinergic tone (bradycardia as a defensive reflex to improve ventricular filling) leads to a prolonged ventricular standstill.⁵ Uniformly, Jaiswal et al described a case of Ventricular Standstill induced at the condition of REM Sleep. The move from sympathetic to vagal predominance during REM sleep or the withdrawal of sympathetic activity during phasic REM events may cause REM sleep bradyarrhythmia, according to certain theories. Tilt test, carotid sinus massage, swallowing, vomiting, and left cardiac catheterization have all been reported to cause vagally mediated paroxysmal AV block.⁶ Some medications used in clinical practice to prevent or cure arrhythmias are also key regulators of cardiac automaticity. β -Blockers and digitalis are examples of medications that reduce adrenergic impacts.²

Propranolol Usage

In an attempt to impede this hyperadrenergic state, non-cardio-selective β -blockers (NCBB) are widely employed as the standard of therapy in both thyrotoxic crisis and uncomplicated hyperthyroidism. Propranolol has been a preferred NCBB due to its additional benefit

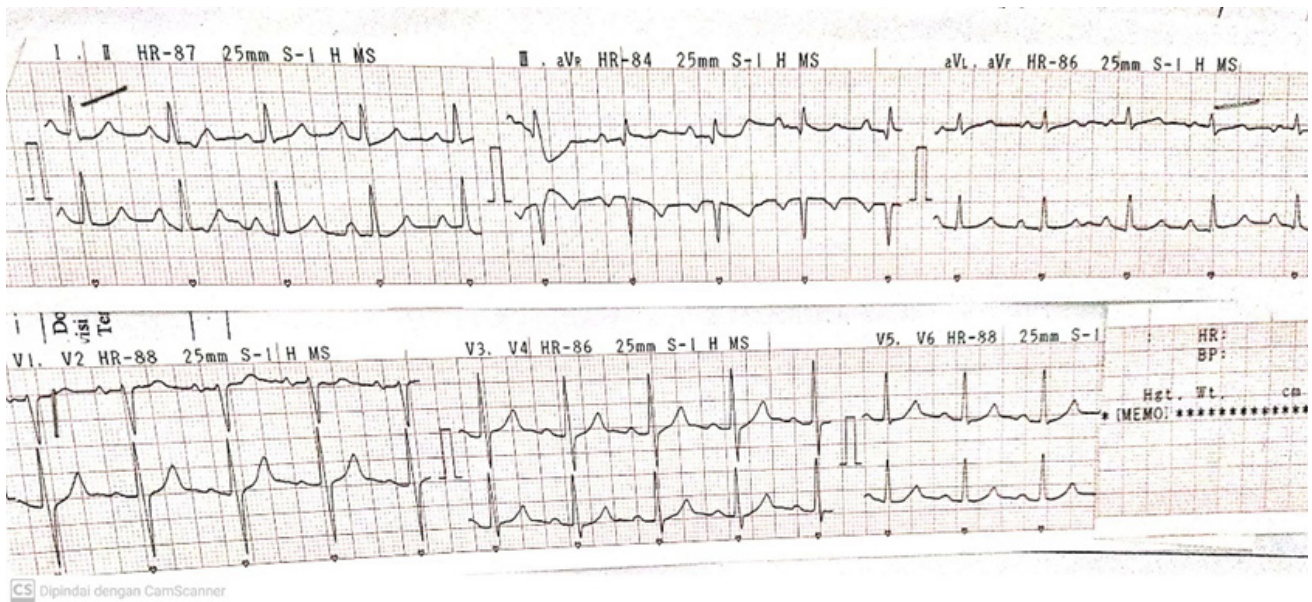


Figure 5. ECG one day after temporary pacemaker removal, showing sinus rhythm without sign of ischemia.

of inhibiting the peripheral conversion of inactive T4 to active form T3.¹⁵ Several case reports describe side effects of β -blocker in hyperthyroid settings. Ngo and Tan reported a patient with Grave disease with cardiomegaly and mild congestion, managed with propranolol 10 mg PO, later he had a hypotensive condition with post- β -blockers TTE showed EF of 25%.¹⁶ Abubakar also reported a patient with thyroid storm managed with IV Propranolol then showing a severe drop of MAP shortly following administration of IV Propranolol with reduced LVEF by 15% compared to TTE done 2 months prior.¹⁵ In the case reported by Dalan and Leow, there was no clinical evidence of HF at presentation, and yet the patient developed cardiac arrest shortly after administration of propranolol.¹⁷

Our case demonstrates a typical clinical scenario where propranolol was administered in the treatment of hyperthyroid. We believe the Ventricular Standstill in our case was caused by an injury of specialized tissue and an exaggeration of overdrive suppression. Hyperthyroidism-induced inflammation and fibrosis are thought to have caused damage to specialized tissue. Propranolol and PTU were used to manage the patient previously. Propranolol, as a β -blocker, may inhibit the adrenergic response (a factor that opposes overdrive suppression), resulting in exaggerated overdrive suppression.

Differential Diagnosis

Ictal asystole is an important differential diagnosis to ventricular standstill which also may cause sudden death. Ictal asystole is defined as the absence of ventricular complexes for more than 4 seconds accompanied by electrographic seizure onset. It is a rare condition usually associated with temporal lobe epilepsy.¹⁸ Ictal asystole, ictal bradycardia, and ictal AV block predominantly occurred during focal dyscognitive seizures in people with temporal lobe epilepsy. No deaths were reported suggesting that ictal arrhythmias are self-limiting. In contrast, postictal arrhythmias including asystole, AV block, and the less prevalent AF and VF usually occurred after a convulsive seizure and were frequently associated with Sudden Unexpected Death in Epilepsy.¹⁹

Management

We treat our patients with a temporary pacemaker, which is the quickest device available in our center for treating a high-grade AV block. Because we believe the thyroid level is responsible for the high-grade AV Block, its reversible characteristic must be considered. After the TPM was installed and the thyrotoxicosis therapy was initiated, the patient's condition improved considerably. Since the TPM was removed, the patient's heart can now accommodate its rate normally, with no dizziness for the

next three months. The current guideline recommends a permanent pacemaker for patients with high-grade AV Block not caused by reversible physiologic causes, regardless of the symptom (I). The guidelines also, however, stress that a High-grade AV Block that is potentially reversible, ideally not be treated with permanent pacing, instead a Temporary pacemaker may be an option to support cardiac rhythm before the main etiology is resolved (IIa). There is no specific mention of advanced AV block in the specific setting of thyroid dysfunction (especially a hyperthyroid) or a case of ventricular standstill. However the guideline mentions patients with symptomatic second-degree or third-degree atrioventricular block associated with thyroid function abnormalities but without clinical myxedema, permanent pacing without further observation for reversibility may be considered (IIb).⁴

Conclusion

Hyperthyroidism may cause AV Block by inducing inflammation in the AV conduction system and fibrosis in cardiac tissue. Some factors, presumably, will promote ventricular standstill from AV block condition. Idioventricular pacemaker automaticity plays a role in maintaining the contractility of the ventricle in severe AV block, and overdrive suppression may inhibit the automaticity of the idioventricular pacemaker, resulting in Ventricular Standstill. Factors that may correlate with hyperthyroid and ventricular standstill are damaged cardiac tissue by hyperthyroid-induced inflammation and exaggeration of overdrive suppression from adrenergic inhibition by β -blocker, as therapy for hyperthyroid. When the euthyroid condition is restored, clinical status and conduction problems can be reversible.

Acknowledgments

We are grateful to the patient and his family for allowing us to share information about her case with the medical community for educational purposes. We also appreciate RSU Islam Klaten for supporting us on data collection.

References

1. D. A. Adegoke, "Paroxysmal Ventricular Standstill: A Rare Cardiac," *American Journal of Case Reports*, vol. 21, p. e924381, 2020.
2. H. Cookson, "Paroxysmal Ventricular Standstill," *British Heart Journal*, vol. 14, no. 3, pp. 350-356, 1952.
3. W. J. Moles, A. A. Barnes, A. Khan, K. Patel and N. Bos, "Incidental Findings of Asystole in a Patient With Complaints of Near Syncope: A Case Report on Paroxysmal Ventricular Standstill," *Cureus*, vol. 13, no. 10, p. e18438, 2021.
4. K. Vennard and M. P. Gilbert, "Thyroid Storm and Complete Heart Block after treatment with Radioactive Iodine," *HIndawi Case Report of Endocrinology*, no. 8214169,, pp. 1-3, 2018.
5. M. A. El-Harasis, C. V. DeSimone, M. N. Stan, C. J. Mcleod and P. A. Noseworthy, "Graves' disease-induced complete heart block and asystole," *Heart Rhythm Case Reports*, vol. IV, no. 3, pp. 105-108, 2018.
6. C. Ortmann, H. Pfeiffer, A. Du Chesne and B. Brinkmann, "Inflammation of the cardiac conduction system in a case of hyperthyroidism," *International Journal of Legal Medicine*, vol. 112, pp. 271-274, 1999.
7. H. Abubakar, V. Singh, A. Arora and S. Alsunaid, "Propranolol-Induced Circulatory Collapse in a Patient With Thyroid Crisis and Underlying Thyrocardiac Disease: A Word of Caution," *Journal of Investigative Medicine High Impact Case Reports*, vol. 78, pp. 1-6, 2017.
8. A. Ngo and D. Tan, "Thyrotoxic Heart Disease," *Resuscitation*, vol. 70, pp. 287-290, 2006.
9. M. Vassalle, "On the Mechanisms Underlying Cardiac Standstill: Factors Determining Success or Failure of Escape Pacemakers in the Heart," *Journal of American College of Cardiology*, vol. 5, no. 6, pp. 35-42, 1985.
10. K. S. Ozcan, D. Osmonov, I. Erdinler, S. Altay, E. Yilidirim, T. Ceyhan and H. Hasdemir, "Atrioventricular block in patients with thyroid dysfunction: Prognosis after treatment with hormone supplementation or antithyroid medication," *Journal of Cardiology*, vol. 60, pp. 327-332, 2012.
11. S. Jaiswal, A. P. N. Aldave and K. J. Wool, "Ventricular

- standstill: An uncommon electrophysiological abnormality caused by profound vagal tone," *North American Journal of Medical Science*, vol. 6, no. 4, pp. 178-180, 2014.
12. F. H. Kusumoto, M. H. Schoenfeld, C. Barrett, J. R. Edgerton, K. A. Ellenbogen, M. R. Gold, N. F. Goldschager, R. M. Hamilton and J. A. Joglar, "2018 ACC/AHA/HRS guideline on the evaluation and management of patients with bradycardia and cardiac conduction delay : A Report of the American College of Cardiology/American Heart Association Task Force on Clinical Practice Guidelines and the Heart Rhythm," *Heart Rhythm*, vol. 16, no. 9, pp. 130-226, 2019.
 13. A. R. Panchal, J. A. Bartos, J. G. Cabanas, M. W. Donniro, I. R. Drennan, K. G. Hirsch and P. J. Kudenchuk, "2020 American Heart Association Guidelines for Cardiopulmonary Resuscitation and Emergency Cardiovascular Care," *Circulation*, vol. 142, no. 16, pp. S366-S468, 2020.
 14. H. Latt, K. Kyaw, N. M. Tun, T. T. Tun, S. Aung and H. Yin, "A Case of Ventricular Standstill in a Patient with Acute Gastrointestinal Bleeding," *Journal of Community Hospital Internal Medicine Perspective*, vol. 10, no. 3, pp. 283-286, 2020.
 15. Y. Mu and M. Supino, "A Case of Elusive Cardiac dysrhythmia in high-risk syncope," *American Journal of Emergency Medicine*, vol. 37, no. 10, pp. 1992.e1-1992.e3, 2019.
 16. J. Shirani, M. M. Barron, M. L. Y. Pierre-Louis and W. C. Roberts, "Congestive heart failure, dilated cardiac Ventricles, and Sudden Death in Hyperthyroidism," *The American Journal of Cardiology*, vol. 72, no. 3, pp. 365-368, 1993.
 17. M. Lende, R. Surges, J. W. Sanders and R. D. Thijs, "Cardiac arrhythmia during or after epileptic seizures," *J Neurol Neurosurg Psychiatry*, vol. 87, pp. 69-74, 2016.
 18. R. Dalan and M. Leow, "Cardiovascular collapse associated with beta blockade in thyroid storm," *Exp Clin Endocrinol Diabetes*, vol. 115, pp. 392-396, 2007.
 19. B. Moseley, G. Ghearing, T. Munger and J. Britton, "The treatment of ictal asystole with cardiac pacing," *Epilepsia*, vol. 52, no. 4, pp. e16-19, 2011.