

**Indonesian Journal of
Cardiology**

Indonesian J Cardiol 2023;44:suppl_A
pISSN: 2830-3105 / eISSN: 2964-7304
doi: 10.30701/ijc.1537



Abstract: Case Reports

Prolonged cardiogenic shock leading to Acute Kidney Injury and Severe Metabolic Acidosis in Patient with Multiple Valvular Heart Disease: Trouble Never Comes Alone

N. Christopher¹, P.R.K. Alfera¹, W.K. Anggoro²

General Practitioner of Hermina Tangerang Hospital, Banten, Indonesia¹
Cardiology department of Hermina Tangerang Hospital, Banten, Indonesia²

Background

Multiple valvular heart diseases (VHD) are still highly prevalent, with rheumatic heart disease (RHD) continuing to be the leading contributor, especially in developing countries. In 2019, 40.5 million people worldwide were predicted to be affected by RHD, with a 2.8 million annual incidence rate. Indonesia ranked fourth in the world in terms of prevalence, with a death rate of 4.8 per 100,000 at-risk individuals. RHD predisposes to atrial fibrillation, which increases the risk for stroke, along with heart failure, pulmonary edema, and cardiorenal syndrome, which all contribute to mortality. Furthermore, in multiple VHD, the manifestation of each valve lesion may be altered by hemodynamic interactions, which poses to diagnostic and therapeutic challenges. This case report aims to analyze and recommend courses of action and key strategies to manage a case with multiple VHD complicated by prolonged cardiogenic shock, acute kidney injury (AKI), and metabolic acidosis.

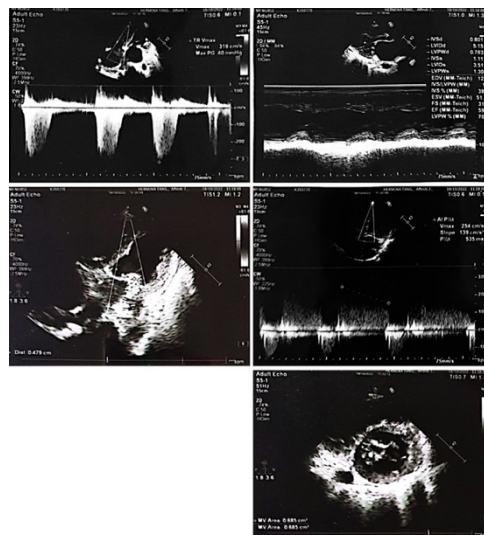
Case Illustration

A 50-year-old female patient presented to the ER with worsening dyspnea and decrease urine output. There was no prior medical history. Physical exams showed hypotension, tachycardia, tachypnea, and cold extremities. Rales and murmur were found and there was no edema in the lower limbs. The ECG showed atrial fibrillation with RVR. Laboratory evaluation presented with low blood glucose, a slight increase in ureum and creatinine, and BGA revealed metabolic acidosis. Cardiomegaly, pulmonary edema, and bilateral pleural effusion were found in CXR. Echocardiography revealed multiple valve disorders. The patient was treated with dobutamine, norepinephrine, furosemide, sodium bicarbonate, digoxin, spironolactone, and warfarin.

Conclusion

Our case highlighted the importance of improving renal perfusion with inotropic and rate control to manage multiple VHD with prolonged cardiogenic shock, AKI, and metabolic acidosis. Further treatment such as a lifelong antibiotic as a secondary prevention and valve surgery are recommended for this case.

Keywords: Multiple valvular heart disease, Rheumatic heart disease, Cardiogenic shock



ACUTE PERICARDITIS IN MILITARY TRAINEE INDONESIA AIR FORCE: IMPACT, RECOMMENDATION AND ASSIGNMENT

A. Nugraha¹, L. Pribadi², M.G. Suwandi²
dr. M. Munir Airforce Hospital, Malang, Indonesia¹
dr. S. Hardjolukito, Airforce Central Hospital, Yogyakarta, Indonesia.²

Background

This case occurs to the military trainee of the Indonesian Air Force (TNI AU) who has only attended the training for 3 weeks. It has an impact on continuing his military training and he would be dismissed of being the prospective soldier candidate of TNI AU. The case becomes the first report of the acute pericarditis in the basic military training institution of the Indonesian Armed Forces (TNI).

Case Illustration

The male trainee, 19, suffered from severe shortness of breath while doing his activities in the last 3 days before being hospitalized. He complained of cough with thick phlegm and flu, as well as a fever that has subsided. He had a history of smoking without other risk factors of a cardiovascular disease. He was diagnosed with bilateral Pneumonia, PCR Test, Gene expert MTB, blood, and sputum cultures showing the negative results. On the fourth day of the treatment, the patient complained of chest pain when taking a deep breath, a non-contrast CT scan of the thorax was performed and the results was bilateral pneumonia accompanied by pericardial effusion with a volume of 100-250cc. ECG showed (Fig. 1), normal CKMB and CRP. Echocardiography showed mild to moderate posterior pericardial effusion.

Conclusion

The prevention of relapse by optimizing OAINS and the restriction of activities become the main point of successful pericarditis treatment. The impact of pericarditis which generally occurs in a young age with arduous activities has been discussed as a consideration in the assignment of military personnel.

Keywords: Pericarditis, Pericardial Effusions, Military.

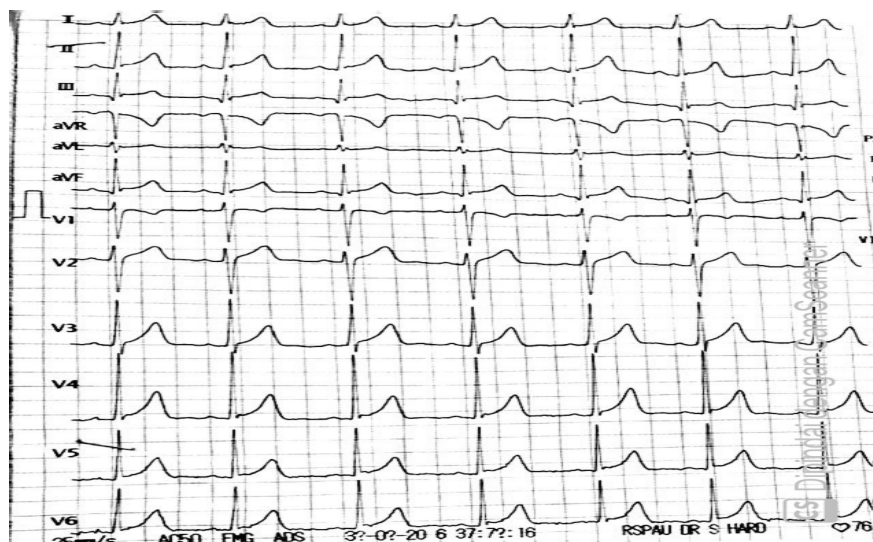


Figure 1. ECG showed Wide Spread ST Elevation

SVT in 2nd Trimester of Pregnancy – a Case Report

A.A. Modjo¹, Ahadi², I.M. Tania³

General Practitioner, 'Aisyiyah Bojonegoro Hospital¹

Department of Cardiology and Vascular Medicine, 'Aisyiyah Bojonegoro Hospital²

Department of Obstetric and Gynecology, 'Aisyiyah Bojonegoro Hospital³

Background

Cardiac disease has become a major cause of maternal death. Rheumatic Heart Disease (RHD) mostly affect women in reproductive age, linked to mitral valve disease specifically Mitral Stenosis (MS) as complication. Previous cardiac disease with changes in pregnancy including anatomy, hemodynamic, and hormonal changes may predispose pregnant women to arrhythmia. Most common arrhythmia in pregnancy is supraventricular tachycardia (SVT).

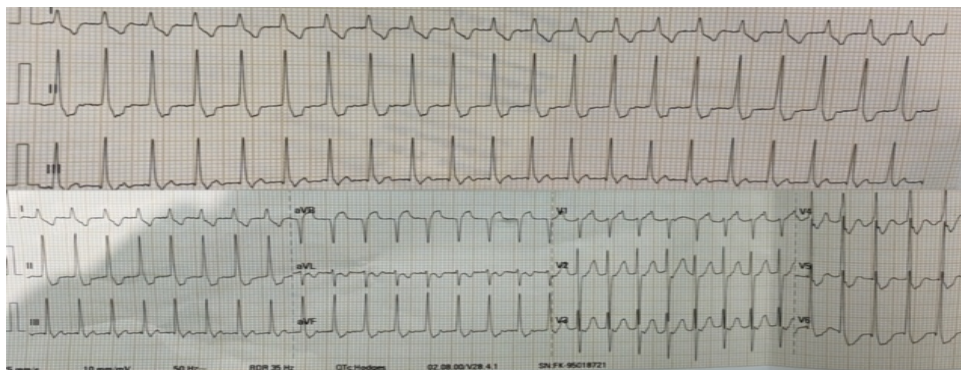
Case Illustration

A 34-year-old multigravida woman with 24-25 weeks of gestation came to ER with complaint of sudden palpitation, dull aching chest pain, dizziness and shortness of breath. She had no relevant history of cardiac disease. Vital sign at the ER with Glasgow Coma Scale (GCS) 4/5/6, Blood Pressure (BP) 95/80, Heart Rate (HR) 201, Respiratory Rate (RR) 24x/min, 98% saturation and diastolic murmur grade III-IV/VI. Laboratory examination was in normal limit. ECG showed SVT 201 bpm with narrow QRS complex. The patient was given a carotid sinus massage at first but no respond in ECG. Then patient was admitted with Bisoprolol 5 mg per oral, however there was no change in ECG. Due to the life threatening condition and drugs availability in our hospital, administration of Amiodarone 150 mg intravenous in ICU was initiated, subsequently ECG was convert to sinus rhythm with vital sign GCS 4/5/6, BP 110/70, HR 90x/min, RR 20x/min, temperature 36.7°C, 100% saturation with nasal oxygen 4 lpm, and fetal heart rate 136x/min. Echocardiography examination later revealed RHD with severe MS, moderate Mitral Regurgitation (MR), moderate Aorta Stenosis (AS), moderate Aorta Regurgitation (AR), mild Tricuspid Regurgitation (TR) and Left Atrium (LA)-Right Ventricle (RV)-Right Atrium (RA) dilation.


Conclusion

SVT in pregnancy related with Mitral Stenosis as a complication of RHD required early diagnostic and appropriate management from multidiscipline approach due to concern in maternal and fetal well-being.

Keywords: SVT, Mitral Stenosis, RHD, Pregnancy



Electrocardiography SVT



Serial Case of Premature Ventricular Contractions (PVCs) of Outflow Tract Origins

P.P. Sakti¹, A. Rizal¹

Cardiology and Vascular Medicine Department, Dr. Saiful Anwar Teaching Hospital - Medical Faculty of Universitas Brawijaya¹

Background: Premature ventricular contractions (PVCs) are defined as myocardium depolarizations that begin in the ventricle. PVCs emerge from a variety of sources, primarily the outflow tracts (OTs). Radiofrequency ablation is the standard treatment for the majority of symptomatic PVCs. Determining the origin of PVCs is critical to achieving better ablation results and lower complications. According to research, ECG features can provide accurate predictions for PVC origin.

Case Illustration: The first patient was 59-year-old man (weight 70 kg, height 165 cm) with a history palpitations. His Holter examination revealed multifocal PVCs (13%) dominant RVOT origin with episodic bigeminy and couplet multifocal, but no PVCs were found during ECG examination. The patient was diagnosed with frequent PVC septal RVOT epicardial origin. The second patient was a 39-year-old man (weight 80 kg, height 170 cm) suffered from asymptomatic arrhythmia during a routine medical checkup. His ECG examination showed sinus rhythm with PVC RBBB and multiphasic pattern in lead V1. He was diagnosed with frequent unifocal PVC posterior LVOT epicardial origin. His Holter monitoring showed episode of PVC unifocal, bigeminy, trigeminy, couplets, and occasional PAC. Both patients are planned for radiofrequency ablation.

Conclusion: A 12-lead ECG can be used to predict the origin of PVCs and is a non-invasive approach. Identifying the source of PVCs prior to radiofrequency ablation is critical for increasing procedure's success rate.

Keywords: ablation, ECG, PVC, outflow tract (OT).

Differing Tumor and Thrombus: When the Heart Explains the Brain

J. Koswara¹, D. Suwanto²

General Practitioner, Medan, Indonesia¹

Cardiologist, Efarina Etaham Hospital, Pematang Siantar, Indonesia²

Background: Primary cardiac tumors are an incredibly rare finding. Cardiac myxomas are the most common type of primary cardiac tumors in adults. 75% of myxomas originate in the left atrium. They are histologically benign but when left untreated they could potentially cause embolism at various site. Nonspecific manifestation may hinder the diagnosis, which can lead to complications.

Case Illustration: We present a case of a 57-year-old female with no risk factor for atherosclerosis, admitted at an emergency department an hour after the onset of right sided sensorimotor weakness. Chest X-ray showed an enlarged cardiac silhouette. Brain CT-scan showed normal. A transthoracic echocardiogram revealed a large mobile mass sized 3.7 x 3.7 cm attached to intra-atrial septum and prolapsing into left ventricle through mitral valve from the left atrium. A surgical approach was used to resect the mass in the left atrium and surgery went well. Symptoms were resolved and patient did not report any surgery complications.

Conclusion: Cardiac myxomas frequently present with neurological symptoms, especially ischemic events (established stroke or transient ischemic attack). Myxomas and thrombi can be differentiated using echocardiography by assessing the distinguishing features of size, origin, shape, mobility, and prolapse. Surgery should be performed following the diagnosis to prevent dreadful embolic complication of cardiac myxoma.

Keywords: Cardiac Mass, Myxoma, Thrombus, Tumor.

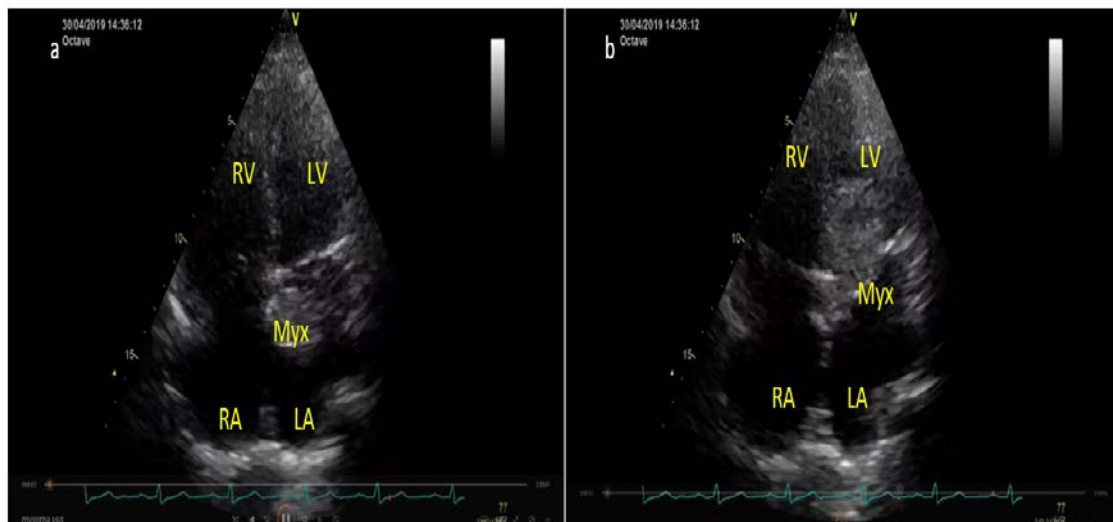


Figure 1. (a) Left atrial myxoma seen in two-dimensional trans thoracic echocardiography. (b) Left atrial myxoma seen prolapsing through the mitral valve into left ventricle.

Late Treatment of Large Swiss Cheese-like Secundum ASD: Transesophageal and Transthoracic Echocardiography Findings

S. Shadiqqa¹, R. Nurmeliiani²
RSUD Al Ihsan¹
RSUD al Ihsan²

Background :

Atrial septal defect is one of the most common congenital heart diseases. More than three-quarters of ASD cases are secundum ASDs. [1], [2] In ASD, a left-to-right (L-R) shunt occurs, causing a right-sided volume overload which leads to failure and increased pulmonary atrial pressure. Defect closure can be done surgically or through percutaneous repair, to determine which procedure to perform information about the morphology of the defect is needed. Transthoracic echocardiography (TTE) is the initial examination followed by transesophageal echocardiography (TEE). [3] Objectives assessed from TTE and TEE include the location, size and number of defects, rims deficiency, intraatrial septum and structural changes as a consequence of the hemodynamics L-R shunt.[4]

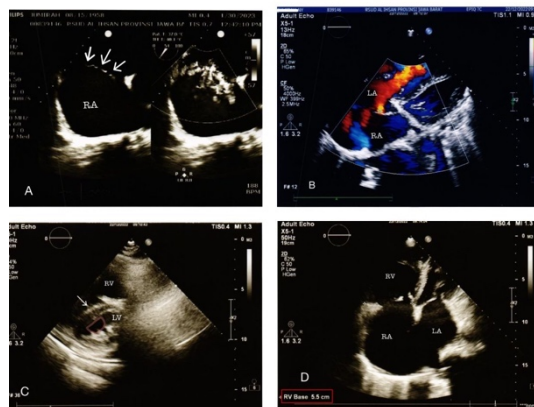
Case :

A 64-year-old woman patient complained of shortness of breath which has worsened with daily activities since a year ago. On physical examination there were crackles in both lungs, heart murmur, distention in JVP and swelling in both legs. TTE and TEE examinations revealed multiple defects of secundum ASD, the largest one measured 4-4.4 cm, the appearance of right-sided volume overload, severe tricuspid regurgitation and a high probability of pulmonal hypertension. The patient was then advised to undergo surgical defect closure.

Conclusion :

Defect closure of ASD can be done surgically or through percutaneous repair. TTE and TEE examinations are necessary to assess the defect's morphology and then consider which method should be performed. L-R shunt will eventually cause a right-sided volume overload, leading to failure and increased pulmonary atrial pressure. [3][4]

Keywords: ASD, congenital, failure, secundum



Case Report - An Incidental Findings of Lutembacher's Syndrome In Rural Areas

P.A. Simanjuntak¹, E.J.H. Sinaga¹

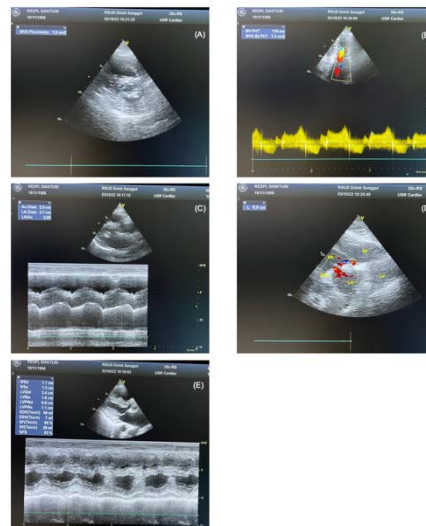
Department of Cardiology and Vascular Medicine, RSUD Dolok Sanggul, Humbang Hasundutan, Sumatera Utara, Indonesia¹

Background : Lutembacher's syndrome (LS) is a rare cardiovascular anomaly defined as any combination of congenital or iatrogenic atrial septal defect (ASD) with congenital or acquired mitral stenosis (MS). As atrial septal defect acts as a pressure relieving gateway, signs and symptoms of mitral stenosis may be attenuated or delayed in such patients. Patients with LS are often asymptomatic for many years as observed in this case, and this patient may live for up to 50 years before experiencing symptoms of cardiac decompensation. Hemodynamic expression and clinical features are affected by the combined effects of ASD size, mitral stenosis severity, and right ventricle distensibility. Early detection and treatment result in a better prognosis, but in late advanced stage, such patients develop pulmonary hypertension and heart failure with poor prognosis.

Case Illustration : Here, we report the case of a 53 years old female with Lutembacher's syndrome that was incidentally diagnosed when being consulted to cardiologist and treated conservatively for heart failure at Humbang Hasundutan Regional Hospital. Since 2018 this patient has been an internist routine outpatient and treated as congestive heart failure and hypertension. Based on history taking, physical and supporting examination, this patient is on advanced stage with pulmonary hypertension and heart failure are already developed.

Conclusion : Delay in identifying and accessing medical center, caused by transportation difficulties, inadequate cardiologists and referral facility, and delay in having prompt treatment particularly in rural areas as Humbang Hasundutan are the cause of delayed in LS diagnosis and treatment as demonstrated in our case. Echocardiography remains the modality of choice for the diagnosis and evaluation of LS. In this case report, transthoracic echocardiography along with color flow imaging, establishes the diagnosis of LS and identifies the type and size of the ASD and the presence and degree of mitral stenosis.

Keywords: Atrial Septal Defect, Heart Failure, Lutembacher syndrome, Mitral stenosis



Trans-Thoracic Echocardiography showed Mitral Valve Area by (a) planimetry and (b) pressure half-time (PHT) (c) left atrial to aortic root ratio (d) the presence of ASD (e) LV size and function

Atypical Atrial Flutter-Fibrillation and Obstructive Sleep Apneu Interconnection

D.P. Andryan¹, D.Y. Hermanto¹

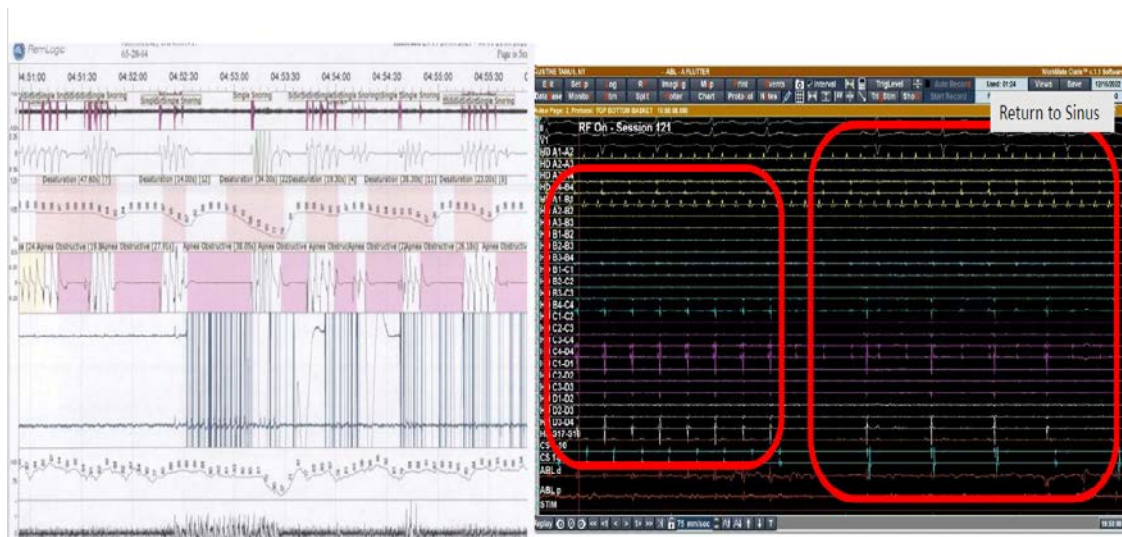
National Cardiovascular Center Harapan Kita, Faculty of Medicine, Universitas Indonesia¹

Background: Atrial Fibrillation (AF) is the most common sustained cardiac arrhythmia in adults, in the world. Obstructive Sleep Apnea (OSA) is one of the overlooked AF comorbid. Untreated OSA is an established risk factor for new-onset atrial AF, progression from paroxysmal AF to persistent AF, and Atrial arrhythmias recurrence after catheter ablation.


Case Illustration: Mrs. AT, 42 years old came to the arrhythmia outpatient clinic with complaints of palpitations that had been worse the past 1 year, previously underwent partially successful ablation of Multifocal Atrial Tachycardia. The patient had no history of hypertension, diabetes mellitus, dyslipidemia, or ex-smokers. After re-exploring the comorbid, the patient apparently had complaints of frequent snoring every night. Polysomnography revealed severe OSA. A patient was diagnosed with Atypical Atrial Flutter-Fibrillation and Severe OSA. The patient underwent CPAP therapy for 1 year before undergoing 3D ablation. ENSITE electroanatomic mapping system during tachycardia showed the earliest activation at the right carina. circumferential isolation of the right carina and right PV were delivered. Post ablation, ECG converted to sinus rhythm and resolution of symptom.

Conclusion: OSA is an important but overlooked risk factor for AF. Atrial remodeling, diastolic dysfunction, increased autonomic tone, and inflammatory mediators, are potential factors that amplify the risk of AF. Patients with OSA and AF are prone to recurrent AF after catheter ablation, therefore it is necessary to carry out appropriate management for OSA itself.

Keywords: Obstructive sleep apneu, Atrial Fibrillation, Atrial Flutter, connection, comorbid



Polysomnography & ablation of PV



Peripartum Cardiomyopathy with Complete Recovery After 2 Years of Follow Up: A Case Report

Y. Pintaningrum¹, N.N. Humaera²
Cardiology Department West Nusa Tenggara Central Hospital¹
Mataram University²

Background: Peripartum Cardiomyopathy (PPCM) is a systolic dysfunction that occurs during late pregnancy or a period of up to 5 months after delivery. PPCM patients may present symptoms earlier, especially in patients with previous cardiac comorbidities. Clinical manifestations of PPCM vary depending on the degree of disease.

Case Illustration: A 28-year-old pregnant woman admitted with shortness of breath, accompanied by a dry cough, cold sweating, and fatigue. Patient in 32 weeks of pregnancy with her second time of pregnancy. There are no significant risk factors other than hypertension and no history of other underlying clinical disease. Patient was referred with cardiogenic shock caused by Congestive Heart Failure (NYHA class IV). The results showed valvular abnormalities in the form of mild mitral regurgitation and mild to moderate tricuspid regurgitation, decreased left ventricular systolic function EF 30%, hypokinetic global left ventricle and left ventricular remodeling. Termination of the pregnancy was taken. Comprehensive monitoring was conducted, but due to neonatal complications fetal death has occurred. The patient was treated with furosemide 1x40 mg, spironolactone 1x25 mg, betade 1x2.5 mg, lisinopril 1x5 mg, N acetyl cysteine 3x200 mg, and 1x80 mg of aspirin by controlling of fluid intake 1000 cc/24 hours for the maximum intake. The treatment given was subsequently tapered off according to the patient's condition until 1 year after the onset, treatment was discontinued. After undergoing approximately 2 years of monitoring, an echocardiographic evaluation of the patient was carried out and showed normal results with EF 82%.

Conclusion : Comprehensive management can provide a good prognosis in patient with Peripartum Cardiomyopathy.

Keywords: peripartum, cardiomyopathy, complete recovery

LEFT MAIN CORONARY ARTERY ANEURYSM PRESENTING AS ANTERIOR STEMI: A RARE CLINICAL FINDING

H.A.K. Cantika¹, D.B. Lululangi¹, P.R. Dewi², U. Bahrudin³

Department of Emergency, KRMT Wongsonegoro State Hospital, Semarang, Indonesia¹

Department of Cardiology, KRMT Wongsonegoro State Hospital, Semarang, Indonesia²

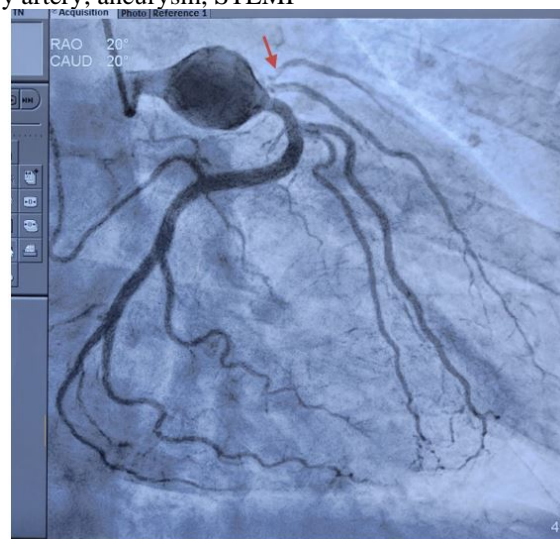Department of Cardiology and Vascular Medicine, Faculty of Medicine, Diponegoro University, Semarang, Indonesia³

Background: Aneurysm of the left main coronary artery (LMCA) in patients with ST-elevation myocardial infarction (STEMI) is unusually reported. LMCA aneurysm is an uncommon coronary disease, found incidentally in 0.1% of patients undergoing routine angiography.

Case Illustration: A 40-year-old man presented at our emergency department with a 1-hour onset of an acute typical angina. This patient had no known preexisting risk factors or past coronary artery comorbidities. The electrocardiogram showed ST-segment elevation at V2-V4 lead conforming anterior STEMI. MONACO strategy was initiated promptly upon diagnosis and followed by cardiac catheterization. Coronary angiography revealed 15 – 16 mm diameter aneurysmal dilatation of LMCA with total ostial occlusion in the left anterior descending artery (LAD) and 30% thrombus-type ostial stenosis of the left circumflex. Thrombus formation is favored at the aneurysmal site due to more sluggish flow through a dilated vessel and thus later can present as STEMI. The lack of evidence of any fundamental atherosclerotic risk factors and the presence of stenosis only in the branches of the LMCA led us to also consider possible non-atherosclerotic causes in this patient. Further history-taking acknowledged the patient's prolonged hospitalization history during childhood, which raised our suspicion of vasculitis causal. A follow-up echocardiography reported reduced left ventricular systolic function with 48% ejection fraction and regional wall motion abnormality. This patient received triple antithrombotic therapy consisting of dual antiplatelet and intravenous anticoagulant and remained stable during intra-hospital care. Antithrombotic management was continued orally in outpatient care.

Conclusion: LMCA aneurysms are rare in patients presenting with coronary syndrome. Patient-based approach with comprehensive clinical evaluation remains the management strategy due to the unavailability of a well-established consensus. In this case, the patient obtained optimal medical therapy as the treatment of choice based on clinical considerations.

Keywords: left main coronary artery, aneurysm, STEMI



Total ostial occlusion in LAD (marked with red pointer) in conjunction with LMCA aneurysm of 15 – 16 mm diameter and 30% thrombus-type ostial stenosis of left circumflex found in coronary angiography.

Acute Coronary Syndromes with Normal Electrocardiogram Finding in Emergency Department : A Case Report

S. Raj¹, T. Delfian²

¹General Practitioner, Hermina Medan General Hospital

²Cardiologist, Hermina Medan General Hospital

Background

Coronary Artery Diseases (CAD) are number one cause of death worldwide and top three in Indonesia. CAD process results which can be categorized as either Acute Coronary Syndromes (ACS) or Chronic Coronary Syndromes. Diagnostic of ACS including clinical symptoms and vital signs, cardiac marker testing and Electrocardiogram (ECG). ECG in ACS differentiated into two group consist of ST Elevation ACS and Non ST Elevation ACS which may present as transient ST-segment Elevation, persistent or transient ST-segment depression, T-wave inversion, flat T waves, Pseudonormalization of T waves, or the ECG may be normal.

Case illustration

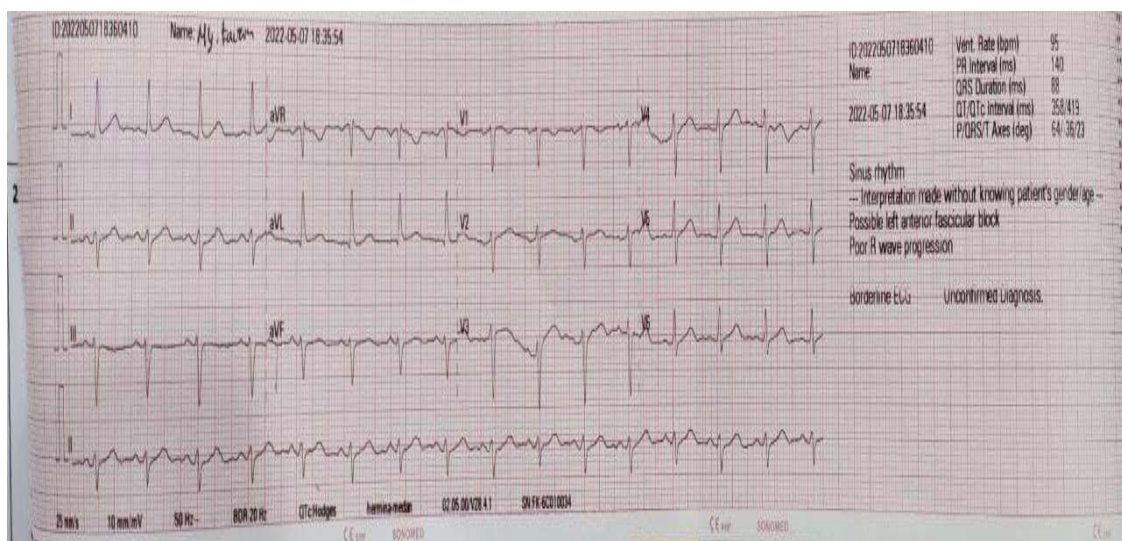
Female, 52 yo taken by her children to Emergency Department (ED) of Hermina Medan General Hospital with chief of complain dyspnoea triggered by activity with history of chest pain, cold sweat, nausea, vomiting, and syncope. She had nebulized in Clinic Before. Past medical illness was diabetes mellitus uncontrolled. Patient's Respiratory Rate was 24 x/m with Abnormal blood tests showed leukocytosis 16.800/ μ L and high blood glucose 314 mg/dL. Chest X Ray was normal. ECG Showed Left Axis Deviation. In ED, patient was treated with Miniaspi 2 tabs, Clopidogrel 4 tabs, and Atorvastatin 40 mg then was consulted to Cardiologist and Internist and was treated for 4 days.

There are four factors independently associated with missed ACS in the ED and failure to hospitalize patients. They are Normal ECG, female sex less than 55 yo, nonwhite race, and chief complain of dyspnoea. Patients with normal ECG will have 22% of a Non-ST Elevation ACS, 19,2% of Serious Cardiac Event Rate, and 5,7% of in-hospital Mortality Rate.

Conclusion

Clinician who work in ED should be aware that ACS can present without any objective data of Myocardial ischemic injury. Initial diagnosis depends on patient's clinical history and clinician's judgement and treatment should be given immediately.

Keywords: ACS, Normal ECG



Electrocardiogram of the patient

Unprovoked Transformation of Saddle Back to Coved ST-segment Elevation ECG Pattern: A New Paradigm to Recognize the Silent Killer

M. Firdaus¹, A. Rizal¹

¹Department of Cardiology and Vascular Medicine, Faculty of Medicine, Universitas Brwajaya, Dr. Saiful Anwar General Hospital, Malang, Indonesia

Background

Brugada syndrome (BrS) is a heritable arrhythmia syndrome which usually triggered VF and SCA in young adults by many factors such as psychotropic medications, anesthetic agents, cocaine, excessive alcohol intake and fever. We present a case of young adults with unprovoked transformation of BrS.

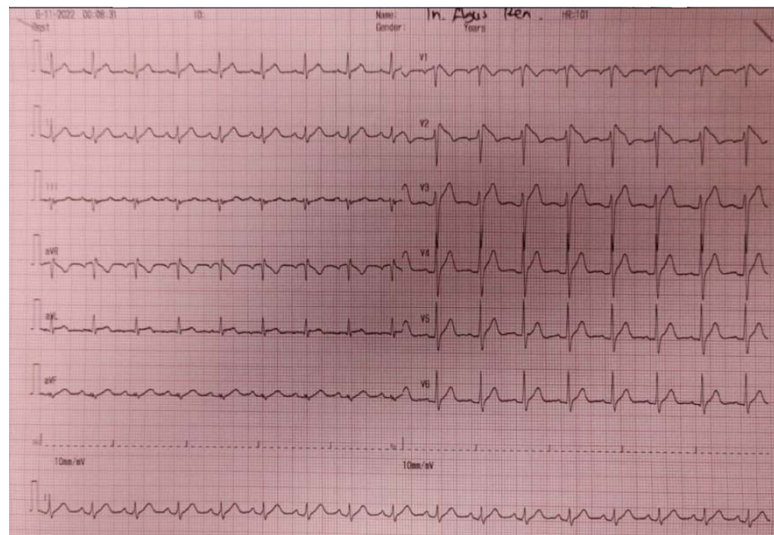
Case Illustration

A 35-year-old man was admitted to ER due to an unexplained syncope. It happened 3 times within 1 hour which preceded by lightheadedness, nausea and vomiting. Before the syncope, he did not feel any palpitation, chest pain nor dyspnea. He had no history of fever, dehydration, alcohol consumption and any medication before. There was no history of sudden cardiac death in his family members. Physical examination, laboratory and echocardiography were within normal limit, but the ECG showed a coved ST-segment elevation with inverted T-wave at V1-V2 with ECG pattern. The ECG then transformed into a saddle back ST-segment elevation 2 weeks later which we assume as the patient's baseline ECG. The diagnosis of BrS was made. He underwent ICD implantation at Saiful Anwar Hospital Malang as a secondary prevention.

Conclusion

ECG changes from type 2 to type 1 Brugada pattern is often induced by trigger factors, but even without any provocation, type 1 BrS could still happen. Thorough history taking and ECG investigation are always a mandatory step.

Keywords: Brugada, Syncope



A Rare Case of Total AV Block In The Young With Significant Coronary Disease: Complete Revascularization or Pacing First?

P.P. Sakti¹, A. Rizal¹

Department of Cardiology and Vascular Medicine, Saiful Anwar Hospital, Malang¹

Background

Total AV block (TAVB) is a highly perilous form of arrhythmia that can manifest in various symptoms such as chest pain, presyncope, and dyspnea, although some patients may not display any symptoms at all. Comprehensive examinations are necessary to exclude the possibility of secondary causes such as myocardial ischemia. This paper will present a case of TAVB in a young patient in setting of acute coronary syndrome with significant lesion.

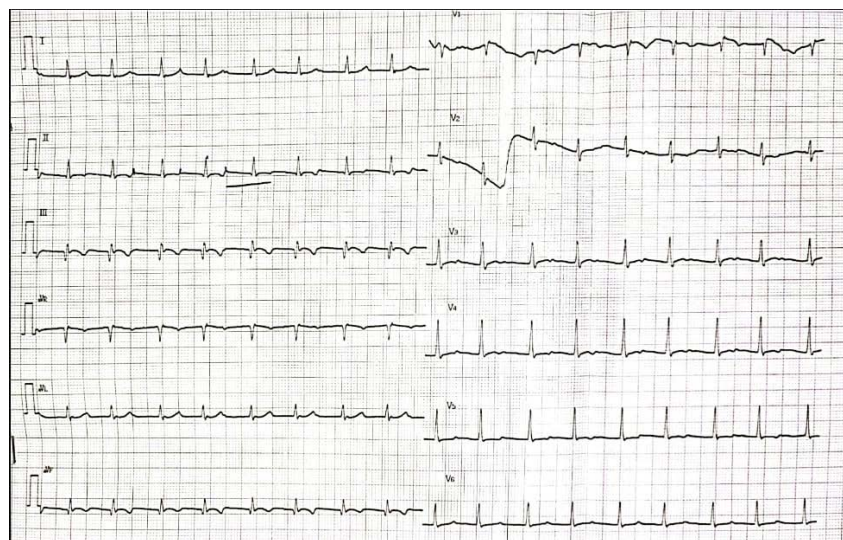
Case Illustration

A 30 years-old man had chief complaints of syncope occurred for about 20 minutes after playing badminton. The syncope was preceded by chest discomfort and light headedness, after regained consciousness spontaneously, he was fully awake, but he still felt chest discomfort. He was a smoker since the age of 18 years old. His father got ACS at 45 years old and performed CABG at 67 years old. From the physical examination, the findings were normal except for bradycardia of 50 beats per minute. The ECG showed TAVB, atrial rate 100 bpm, ventricular rate 50 bpm. The laboratory test showed elevated cardiac marker. He was then diagnosed with TAVB related to ACS. PCI procedure was performed and revealed CAD 2 vessels disease with culprit lesion in RCA and also significant stenosis in LAD, drug eluting stent was implanted at RCA. The ECG evaluation after procedure showed that TAVB was converted to 1st degree AV block. He was observed in the following days and the ECG still didn't turn to sinus rhythm.

Conclusion

Acute coronary syndrome is one of the complete heart block causes. In a young patient with significant coronary disease that cause TAVB should underwent extensive work-up to find the right decision whether it would be complete revascularization or pacing device treatment to prevent any sequelae and obtain the best outcome.

Keywords: total AV block, acute coronary syndrome, revascularization, permanent pacemaker



ECG at first medical contact showed total AV block

Single Ventricle with Two Atria, It is Possible?: A Rare Case from Remote District Hospital at East Nusa Tenggara

Eliza¹, D.M. Putra², I.G Sumantra³

General Practitioner at Waikabubak Hospital, West Sumba, East Nusa Tenggara¹

General Practitioner at Reda Bolo Hospital, Southwest Sumba, East Nusa Tenggara²

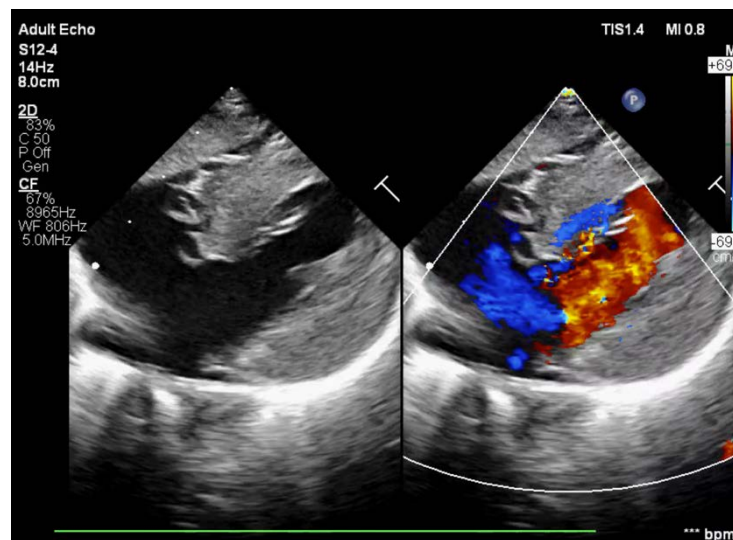
Cardiology Department at Paramarta Heart and Vascular Hospital, Bandung, West Java³


Background: Hypoplastic right heart syndrome (HRHS) is a rare cyanotic congenital heart disease with under-development of the right ventricle, tricuspid, and pulmonary valves leading to right-to-left shunting of the blood through inter-atrial septal defect.

Case Illustration: A 3-month-old male came to the emergency room with a complaint of dyspnea and cyanotic. Vital signs showed heart rate 148 beats per minute, respiratory rate 68 breaths per minute, oxygen saturation 40% with face mask 10 liter per minute. His body weight is 2500 grams. Physical examination showed intercostal retraction and fix splitting murmur. Chest X-ray showed cardiomegaly with CTR 77%, grounded apex, enlarged atrial appendage, and splaying carina. Echocardiography showed a situs solitus, small VSD, moderate ASD secundum with Right to Left shunt, LV hypertrophy with normal LVEF, pulmonary atresia and stenosis and tricuspid atresia and stenosis with RV hypoplastic. Patient was diagnosed with HRHS based on echocardiography findings. Patient was given diuretics such as furosemide and spironolactone and motivated to be referred for further investigation and management. The patient is temporarily survived because of this CHD condition (ASD and small VSD) help the patient still has an oxygenated blood flow to the body although in the decreased blood oxygen saturation.

Conclusion: HRHS is a rare cyanotic congenital heart disease that can be deadly if it is diagnosed and treated late. The survival of the newborn depends on the size of the defect in atrial septal and level of development of the right heart structures. In this setting, we can only give conservative therapy to reduce cardiac preload and refer to the cardiovascular center for further diagnosis and management.

Keywords: hypoplastic right heart syndrome, congenital heart disease, pediatric cardiology





Amiodarone and Oral Verapamil-Induced Hypotension in 34-year-old Woman with Supraventricular Tachycardia and Wolff-Parkinson-White Syndrome

E. Rolandika¹, V.Y.S. Putri¹
RS Baptis Batu¹

Background Supraventricular tachycardia is an arrhythmic condition originating from the sinus node, atrial tissue, accessory pathways and junctional areas. In some cases, patients with WPW have no symptoms until manifesting SVT.

Case Illustration a 34-year-old woman came to the ER with palpitations. ECG examination showed a regular and narrow QRS complex tachycardia with pulse was 190 beats/minute, and blood pressure was 100/90 mmHg. The patient was given 150 mg bolus of amiodarone for 15 minutes. The patient was transferred to the ICU and was administered with amiodarone drip 1 mg/minute for 6 hours then 0.5 mg/minute for 18 hours, isoptin SR (verapamil) 240 mg orally, bisoprolol 1x1.25 mg orally, atorvastatin 1x40 mg orally, aspilet 1x80 mg orally, omeprazole injection 1x40 mg intravenously. While in the ICU, the blood pressure dropped to 81/55 mmHg. Amiodarone, verapamil and bisoprolol were stopped, the patient was then given NaCl 0.9% 100 cc in 10 minutes and norepinephrine 0.05 mcg-1 mcg/kg/minute. The patient's blood pressure increased, the pulse rate became 88x/minute. On repeated ECG examination, a shortened PR interval (<0.12 seconds) and a delta wave pattern were found. The patient was observed in the ICU for 2 days, then the patient was discharged without any complications and was given 1x5 mg bisoprolol for home therapy.

Conclusion Patients with hemodynamically unstable SVT are recommended to receive synchronized cardioversion, but the patient refused. Amiodarone is a class III antiarrhythmic drug that can interact with β -adrenergic receptors, potassium and sodium channels. Amiodarone can reduce atrial sinus automation and decrease the conduction velocity of the atrioventricular node. In some cases, these effects can lead to bradycardia, hypotension and Torsade de Pointes. Administration of verapamil can also provide negative inotropic effects and peripheral vasodilation that can cause hypotension in patients.

Keywords: Supraventricular Tachycardia, Wolff-Parkinson-White, Amiodarone, Verapamil

Case Report : Emergency pericardiocentesis with CVC kit at perifer hospital

D.J. Simatupang¹, Y.S. Situmorang²
Kesrem Hospital Lhokseumawe¹
Arun Hospital Lhokseumawe²

Background

Cardiac tamponade is a life-threatening condition that need urgent pericardiocentesis. Here, the authors report a case of pericardiocentesis with alternative pericardiocentesis kit which is CVC kit.

Case illustration

A male 46 yo admitted to ER with severe short of breath and chest pain that radiates to back. He was treated with tuberculosis and received anti tuberculosis drug by pulmonologist for 2 months. Physical examination showed elevated of JVP, low blood pressure and muffled heart sound. ECG showed low voltage with electrical alternans. From bedside echocardiography, massive pericardial effusion, RV diastolic collapsed and mitral inflow variation > 25% were found.

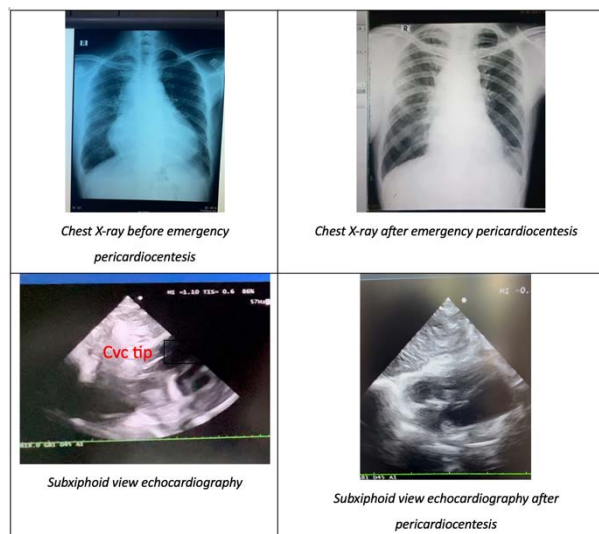
Discussion


This patient fulfilled criteria for cardiac tamponade and needed to do emergency pericardiocentesis. Pericardiocentesis was done with subxiphoid approach by CVC kit as the absence of pericardiocentesis kit in ER. Two liters of pericardial fluid were withdrawn.

Conclusion

We describe a case with emergency pericardiocentesis in cardiac tamponade. This case report focused on the importance of clinical judgement and alternative treatment with the limitation of instrument without catheterization laboratory at perifer hospital.

Keywords: emergency pericardiocentesis, cardiac tamponade, CVC kit, perifer hospital





Stress-induced Hyperglycemia in Acute Decompensated Heart Failure (AHF): Case Report

D.A.D.L. Sati¹, B.A. Prabowo², A.S. G. Nirwana¹

Faculty of Medicine, Jenderal Soedirman University, Purwokerto Central Java, Indonesia¹
Cardiologist, Prof. DR. Margono Soekarjo General Hospital, Purwokerto Central Java, Indonesia²

Background

The association between hyperglycemia (HG) and AHF remains controversial. Several reports have suggested a negative impact of HG on AHF overall survival and mortality yet others have not shown similar findings.

Case Illustration

An 87-year-old woman presents to Emergency room complaining of progressive exertional dyspnea over the last two days, she also complains orthopnea, cough, palpitation, leg swollen, and nausea. She has history of uncontrolled chronic heart failure and hypertension but no history of diabetes mellitus. Examination in ER revealed blood pressure 183/90 mmHg, heart rate 88, respiratory rate 26, temperature 36.6, SpO₂ 99% on 2 lpm O₂ nasal cannulae, cardiomegaly, bilateral rales in lungs, and pitting edema. ECG showed sinus rhythm with LVH and 1st-degree AV block. Chest x-ray showed cardiomegaly and pulmonary edema with bilateral pleural effusion. Laboratory shows high random blood glucose (235 mg/dL) with renal insufficiency (ureum 47.2 mg/dL, creatinine 1.53 mg/dL, creatinine clearance 33 ml/min/1.73m²). Patient was diagnosed as acute decompensated heart failure and hyperglycemia. Echocardiography showed concentric LVH with hypokinetic anteroseptal segment, LVEF 30%, TAPSE 18, AR moderate, and MR mild. Patient was treated with IV furosemide, and oral spironolactone, valsartan, ISDN. After 48 hours, Patient condition was improved, and random blood glucose 108 mg/dL.

This case is an instance of stress-induced hyperglycemia in AHF. This condition is due to sympathetic nervous system activation and/or excessive production of stress hormones like cortisol. Natural physiological responses to stress result in elevated glucose levels.

Conclusion

Hyperglycemia can occur in AHF patients. This condition does not imply diabetes mellitus; rather, the stress response caused the hyperglycemia. Once the clinical state is stabilized, the blood glucose level may return to normal.

Keywords: acute decompensated heart failure, stress-induced hyperglycemia

Persistent Thrombocytopenia in Long-Standing Congestive Hepatopathy Secondary to Severe Mitral Stenosis: A Case Report

Z. Ramadhanty¹, T. Rahadiyan²

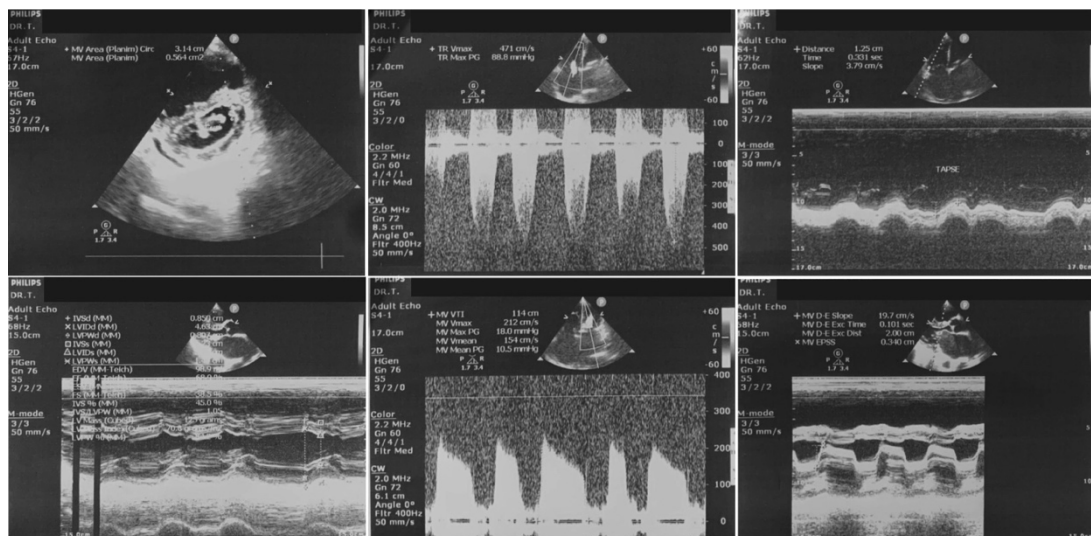
General Practitioner, Cardiology Clinic, dr. Bratanata Military Hospital, Jambi¹
Cardiologist, dr. Bratanata Military Hospital, Jambi, Indonesia²

Background: Congestive hepatopathy is a consequence of a long-term elevated hepatic venous pressures due to chronic right-sided heart failure. This paper aims to present a patient with persistent thrombocytopenia as a rare manifestation of congestive hepatopathy and splenomegaly due to severe mitral stenosis.

Case illustration: A 53-year-old man was admitted to the emergency room with a worsening dyspnea in the last few days, orthopnea, and other signs of right heart failure such as jugular venous distention, hepatomegaly, and pitting oedema. Jaundice was noted and ECG result showed atrial fibrillation. Persistent thrombocytopenia ($55-117 \times 10^3/uL$) in the past few months with normal result of hemoglobin and leucocyte level, slight increase in total bilirubin (2.02mg/dL), SGOT (146u/L), and SGPT (74u/L) was revealed. Coagulation marker (PT and INR) was within therapeutic range. All causes of thrombocytopenia such as viral hepatitis, drug-induced, and immunologic destruction were excluded. Abdominal ultrasonography result showed hepatosplenomegaly and dilated hepatic veins. Echocardiography revealed normal LV function (EF 68%) but decreased RV function (TAPSE 1,25cm); dilatation of LA, RA, and RV; severe mitral stenosis (MV area 0,564cm² and MV mean PG 10,5mmHg) and severe tricuspid regurgitation (TR Max PG 88,8mmHg); D-shaped LV; and estimated PASP of 108,8mmHg. All these findings conclude that this patient had congestive hepatopathy due to right heart failure and severe pulmonary hypertension secondary to severe mitral stenosis. Prolonged congestive hepatopathy could lead to portal hypertension and redistribution of blood flow and platelets to the splenic pool which further lead to reduced thrombopoietin production and results in persistent thrombocytopenia.

Conclusion: Persistent thrombocytopenia can be seen in long-standing congestive hepatopathy. If left untreated, the liver can progressively become fibrotic and cirrhotic, leading to liver failure. To prevent that, the underlying cardiac condition should be treated.

Keywords: congestive hepatopathy, mitral stenosis, chronic heart failure, thrombocytopenia, pulmonary hypertension



Echocardiography revealed decreased RV function with dilatation of LA, RA, and RV; severe mitral stenosis and severe tricuspid regurgitation; and severe pulmonary hypertension

Anti-Thrombotic Strategy in Chronic Limb Threatening Ischemia with Deep Vein Thrombosis After Percutaneous Endovascular Intervention: A Case Report

T.I. Rahayu¹, F. Herfandi², E.F. Elfi³

General Practitioner, Andalas University, West Sumatera¹

Cardiology Resident, Mjamil General Hospital, West Sumatera²

Cardiologist, M Djamil General Hospital, West Sumatera³

Background : Chronic limb-threatening ischemia (CLTI) represents the end stage of peripheral artery disease where antithrombotic as one of the management strategies. Deep Vein Thrombosis (DVT) is an anticoagulant (OAC)-requiring condition and a compelling indication for antithrombotic therapy in CLTI.

Case Illustration : A 65 years old female was admitted with pain in the left foot since 3 weeks before admission. The pain was felt at rest and the tips of the big toe and middle finger of the left foot are blackish. The patient had a history of DVT 3 months ago and treated with rivaroxaban. Localized status of the left foot showed necrosis on the first and third phalange, pain, pallor, pulselessness, paresthesia, poikilothermy, and pretibial edema. There were no arterial pulses in the left dorsalis pedis artery and left anterior tibialis artery. The ABI was 0.14. The vascular doppler showed total occlusion as high as the left anterior tibial artery. We performed Percutaneous Old Balloon Angioplasty (POBA) in the left Anterior Tibial Artery. Subsequently, we started clopidogrel and continued rivaroxaban. The lab's result after POBA showed mild anemia with Hemoglobin 9 mg/dL Therefore, we performed urinalysis and benzidine test with results were microscopic hematuria and negative benzidine test. As the bleeding occurred, we continued clopidogrel and postponed rivaroxaban as we started in the clinic with consideration to reduce risk of bleeding in this patient.

Conclusion : There are several treatment strategies for patients with CLTI. One of the strategies is to treat all patients with CLTI with an antiplatelet and consider clopidogrel as single antiplatelet of choice. Current recommendation in patients with peripheral vascular diseases requiring OAC, OAC should be continued only if a compelling indication exists. After endovascular revascularization, OAC alone should be considered if the bleeding risk are high.

Keyword : Anti-Thrombotic, Chronic Limb Threatening Ischemia, Deep Vein Thrombosis

Keywords: Anti-Thrombotic, Chronic Limb Threatening Ischemia, Deep Vein Thrombosis

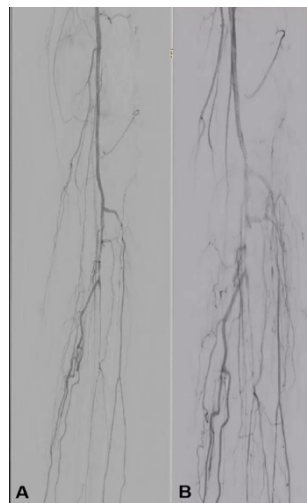


Figure 1 Patient's DSA: Pre-Intervention (A) and Post-Intervention(B)

SPECTRAL CT: STATIC MYOCARDIAL PERFUSION IMAGING IN CHRONIC CORONARY SYNDROME

C. Abdillah¹, D. Wardana², Elen¹

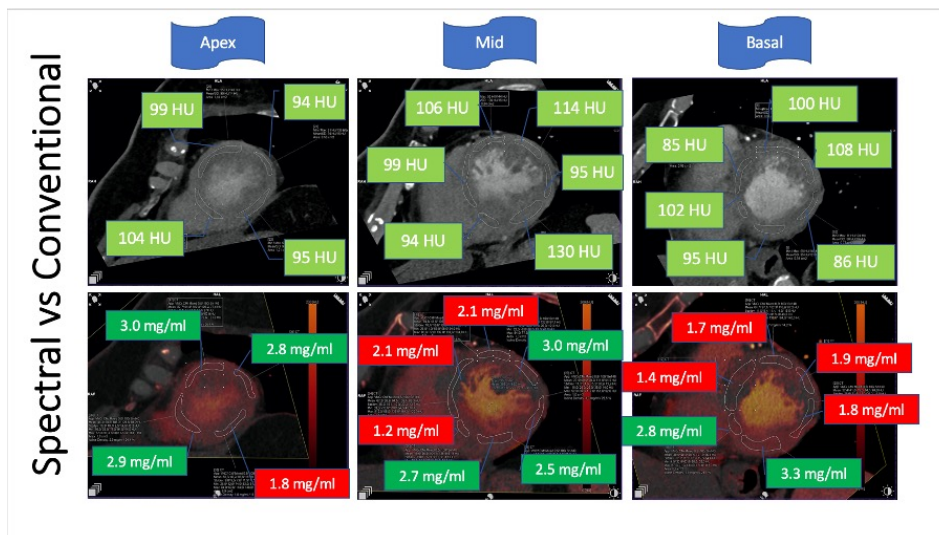
Faculty of Medicine Universitas Indonesia / National Cardiovascular Center Harapan Kita¹
Faculty of Medicine Universitas Diponegoro / Diponegoro National Hospital²

Background : The non-invasive technique using multi slice computed tomography (MSCT), especially coronary CT angiography (CCTA), is more preferable option in diagnostic test rather than invasive angiography. Dual Energy CT (DECT) using spectral imaging has been introduced and potentially evaluating the changes in myocardial blood flow as iodine map images. The aim of this study is to present a case of patients with suspected of chronic coronary syndrome using Spectral DECT to identify ischemic lesion


Case Illustration : A-64-year old female with dyspnea on effort presented with moderate likelihood of CAD. Coronary CT Angiography with Spectral CT was done in this patient. CCTA found multiple lesions on coronary arteries. Moreover, Spectral CT revealed several segments was already hypoperfused although there was no wall motion abnormality with good ejection fraction and normal myocardial density by conventional monoenergetic CT evaluation. Late iodine enhancement (LIE) did not show any infarcted region.

Conclusion : CT has ability to combine evaluation of anatomical detail of coronary anatomy and evaluation of perfusion in single procedure. Spectral imaging CT gives higher diagnostic accuracy regarding ischemia condition which is better than conventional CT.

Keywords: Spectral CT, CT angiography, chronic coronary syndrome, myocardial perfusion



Spectral CT vs Conventional CT



Inotropes and Vasopressor for Stabilization of Cardiogenic Shock with Extensive Anterior STEMI & Ventricular Extra Systole Patient before Primary PCI; a Case Report

S.C. Nugroho¹, K.P. Islami¹, K. Ruth¹
RS Dr. Suyoto General Hospital¹

Background

Cardiogenic shock is mentioned to describe as inadequate systemic circulation caused by primary cardiac dysfunction that leads to hypoperfusion and subsequent multi-organ failure. Delayed recognition and treatment of Cardiogenic shock can increase mortality rate.

The incidence of cardiogenic shock is the most frequent complication in ST- elevation AMI as compared to non-ST-elevation AMI. Norepinephrine (NE) and Dobutamine are Vasopressor and Inotropes that frequently used in clinical for Cardiogenic Shock cases.

Case Illustration

We hereby present a 55-year old man come to ER with typical angina chest pain 1 hour before arriving. This patient has previous stable angina history but not so clear. There were no type II Diabetic history nor stroke. In first ECG, we found Anterior Extensive STEMI and VES with Cardiogenic Shock status. We do initial oral DAPT, high dose statin, fluid reperfusion and start using Dobutamine 3 $\mu\text{g}/\text{Kg}/\text{minute}$ as initial Inotropes and NE 0,1 $\mu\text{g}/\text{Kg}/\text{minute}$ as Vasopressor. We also prepare the patient to send to higher level of Hospital to get Primary PCI. Patient's vital sign was monitored intensively in ER. After 30 minutes monitoring, the BP was not increasing. We increase NE up to 0,5 $\mu\text{g}/\text{Kg}/\text{minute}$ and Dobutamine 3 $\mu\text{g}/\text{Kg}/\text{minute}$. Targeted MAP and BP was not reached. We substitute the combination, then we increase Dobutamine gradually until 10 $\mu\text{g}/\text{Kg}/\text{minute}$ and NE to 0,2 $\mu\text{g}/\text{Kg}/\text{minute}$, targeted MAP and BP was reached and the VES was not too effected. The patient was stable in this setting.

Conclusion

In this patient with Cardiogenic Shock with VES and STEMI Anterior Extensive was safely to get 10 $\mu\text{g}/\text{Kg}/\text{minute}$ of Dobutamine as Inotropes and 0,2 $\mu\text{g}/\text{Kg}/\text{minute}$ of NE. The Ventricular Extra Systole rhythm was not too effected and not going to lethal rhythm.

Keywords: : Cardiogenic Shock, Ventricular Extra Systole, STEMI, Dobutamine, Norepinephrine

Peripartum Cardiomyopathy: A Case Management Series at Sanjiwani Hospital

A.A.G.I. Putra^{1*}, G.I. Susanti², K.E. Bagiari¹, A.A.G.R. Budayasa²

¹Department of Internal Medicine, Cardiology and Vascular Medicine Division, Sanjiwani Hospital, Gianyar, Bali, Indonesia

²Department of Obstetric and Gynecology, Sanjiwani Hospital, Gianyar, Bali, Indonesia

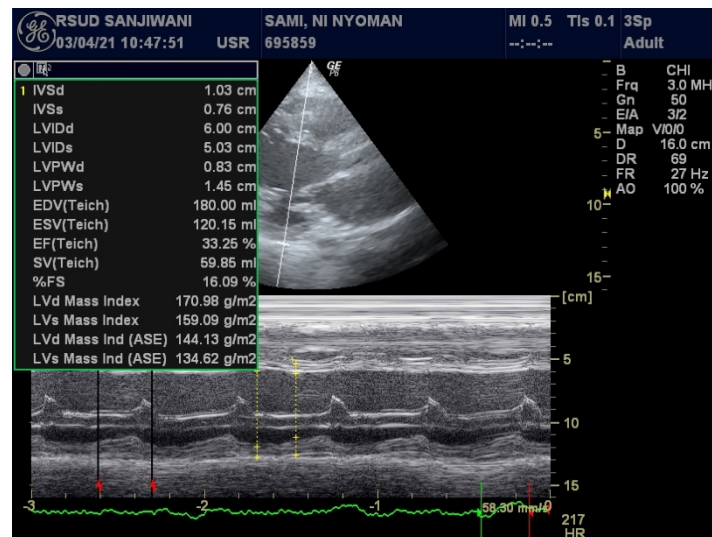
Background: In Peripartum Cardiomyopathy (PPCM), heart function will generally return to normal a few months after delivery, but in some cases poor outcomes might occur, therefore early detection and management are crucial. This case series study aims to get an overview of PPCM cases in a type-B referral hospital in Gianyar, Bali.

Case Illustration: This study presents 3 cases of PPCM that showed symptom onset in the antepartum period (the third trimester of pregnancy). 2 out of 3 cases were nulliparous with maternal age <30 years, and went through a Cesarean Section. All three cases underwent treatment in the Intensive Care Unit and showed improvement in their condition. Until now, the heterogeneity of PPCM diagnostic criteria has become an obstacle to its treatment, thus the reported incidence tends to be low. This is likely due to the diagnosis of PPCM which is an exclusion diagnosis from other causes of heart failure. Echocardiography and NT-ProBNP examinations should be done, which, although not specific, may lead to a diagnosis of PPCM when combined with a thorough patient history. The availability of supporting examination modalities in many regions in Indonesia are varied thus referrals are sometimes needed, resulting in the delay of PPCM cases management.

Conclusion: All pregnant women who experience dyspnea during the third trimester of pregnancy, along with a family history of heart disease, need to undergo close examination and supervision because of the suspicion of PPCM. Early detection and treatment are the main key to successful management of PPCM cases.

Keywords: Early Detection; Echocardiography; Peripartum Cardiomyopathy

Keywords:



Patient echo study

Cardiac memory-induced T-wave inversions after temporary ventricular pacing: a case report

E.P.B. Mulia¹, D.A. Rachmi¹

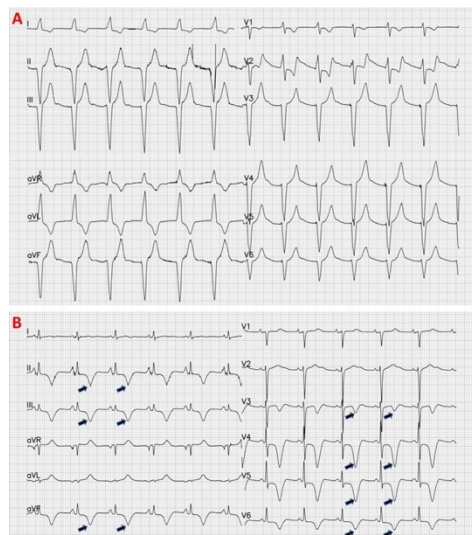
Department of Cardiology and Vascular Medicine, Faculty of Medicine, Universitas Airlangga – Dr. Soetomo General Hospital, Surabaya, Indonesia¹

Background: Cardiac memory refers to the T-wave inversions (TWI) on the electrocardiogram (ECG) after a period of abnormal ventricular activation or wide QRS. TWI as cardiac memory manifestations are often confused with other pathological conditions that may manifest as TWI, such as myocardial ischemia or infarction, myopericarditis, takotsubo cardiomyopathy, and cerebrovascular injury.

Case illustration: We present a 62-year-old female with symptomatic bradycardia due to sinus pause. She underwent temporary transvenous ventricular pacing immediately. A 12-lead ECG obtained after pacing insertion showed right ventricular paced rhythm (QRS width 150 ms) at 75 bpm (figure 1A). In the following days, intrinsic normal sinus rhythm was resumed at 69 bpm and narrow QRS (97 ms). Additionally, deep TWI were observed in leads II, III, aVF, and V3 to V6 (figure 1B). Echocardiography showed no wall motion abnormality. Serial troponin and electrolytes were within normal range. Coronary angiography performed before permanent pacemaker (PPM) implantation showed no significant stenosis. Due to the distribution of TWI, normal echocardiogram and laboratory results, non-significant coronary angiogram, recent right ventricular pacing, and the direction of the T waves in sinus rhythm followed (remembered) the direction of the QRS complex during the preceding episode of wide QRS or abnormal ventricular activation (ventricular pacing), hence TWI was concluded as a manifestation of cardiac memory after ventricular pacing. Follow-up 12-lead ECG four weeks later showed T-wave morphology returned to normal baseline. This further confirmed the final diagnosis of cardiac memory-induced TWI.

Conclusion: Recognizing cardiac memory phenomenon is essential for physicians to facilitate appropriate evaluation and management, which may help avoid unnecessary hospitalization and further cardiac diagnostic test.

Keywords: cardiac memory, T-wave inversion, wide QRS, ventricular pacing, bradycardia



PERICARDIAL EFFUSION IN TB PERICARDITIS AS A SIGN OF WORSE PROGNOSIS : EARLY DETECTION AND PROMPT TREATMENT IS PARAMOUNT.

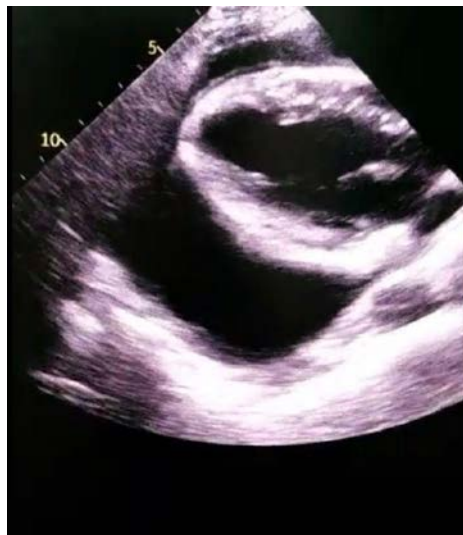L.M.S.I.W. Atmapraja¹, D. Elysmasia¹
Rumah Sakit Umum Daerah Praya¹

Background: Pericarditis is inflammation of the pericardial lining which can be caused by an infection, autoimmune disease, and idiopathy. Tuberculous pericarditis is a rare form of extrapulmonary tuberculosis and can produce a slowly arising pericardial effusion. Tuberculous pericarditis consists of four stages. Beyond third and fourth stages the clinical signs and symptoms of cardiac tamponade or congestion appear may progress to constructive pericarditis.


Case Illustration : A 26-year-old woman came to the emergency room at the Praya Regional Public Hospital complaining of shortness of breath for the past 3 days. On physical examination the Heart: ictus cordis is not visible and not palpable, the heart border seems widened, heart sounds away. On chest X-ray examination, a "water bottle-shaped heart" was obtained which indicated a massive pericardial effusion. Electrocardiographic examination revealed sinus tachycardia and low-voltage complexes and electrical alternation. On echocardiographic examination found accumulation of pericardial effusion in the posterior area. The patient was diagnosed with pericarditis with massive pleural effusion and cardiac tamponade. Pericardiocentesis was performed, a rapid molecular TB test was carried out and the results were positive. The patient was diagnosed with tuberculosis pericarditis.

Conclusion: The diagnosis of tuberculous pericarditis is challenging. It requires strong clinical suspicion, especially in endemic regions. The findings suggest that pericardial effusion in tuberculous pericarditis in the early clinical stage of TB pericarditis is the most predictive factor of constrictive pericarditis, which indicates a poorer prognosis. Early detection and prompt treatment are needed to reduce progressivity and recurrency as well as to prevent mortality.

Keywords: Tuberculosis Pericarditis, Cardiac Temponade, early detection, prompt treatment



Pericardial Effusion



Transient ST Segment Elevation and Complete Atrioventricular Block as an Uncommon Presentation in Acute Fulminant Myocarditis, How to Deal With it?: A Case Series

B. Aji¹, I. Prasetya²

Faculty of Medicine, University of Brawijaya, Malang, East Java, Indonesia¹

Department of Cardiology and Vascular Medicine, Dr. Saiful Anwar General Hospital, Malang, East Java, Indonesia²

Background

Acute myocarditis is a difficult diagnosis to make since it lacks a pathognomonic clinical manifestation. Electrocardiogram (ECG) results in a variety of non-specific abnormalities in myocarditis patients. Nonetheless, ECG is frequently employed as a preliminary myocarditis screening technique.

Case illustration

A-42-years-old and a-37-years-old male were referred to Emergency Department of Saiful Anwar Hospital with the initial diagnosis of acute coronary syndrome (ACS) and shock condition. The ECG examination for the first patient showed new onset right bundle branch block and complete atrioventricular block, while the second patient showed transient ST segment elevation mimicking spontaneous reperfusion. Both patients had elevated Troponin I 31.8 mcg/dL and 39.2 mcg/dL respectively. Urgent coronary angiography was performed as an initial diagnostic tool to rule out coronary cause in both patients with the result of non-significant stenosis with normal TIMI-3 flow. Transvenous temporary pacemaker and intra-aortic balloon pump were inserted as bridge to recovery.

An accurate working definition of fulminant myocarditis is a sudden and severe myocardial inflammation that causes cardiogenic shock and myocyte necrosis. Fulminant myocarditis must be distinguished from other acute circulatory compromises, the most prevalent of which is an acute coronary syndrome. Serial ECGs, echocardiography, heart catheterization with endomyocardial biopsy, immunohistology, and molecular analysis for the underlying infection and pathogenesis are all required as part of a rapid regular work-up in unstable hemodynamic patients. According to current recommendations, acute heart failure treatment consisting pharmacological and mechanical support is required in such situation.

Conclusion

ECG abnormalities in myocarditis patients can take many different forms, but none of them are pathognomonic. Although it is typical for fulminant myocarditis to have non-vascular distribution of ECG abnormalities, this shouldn't delay an angiographic examination of the coronary structure.

Keywords: fulminant, acute myocarditis, transient STEMI, complete atrioventricular block

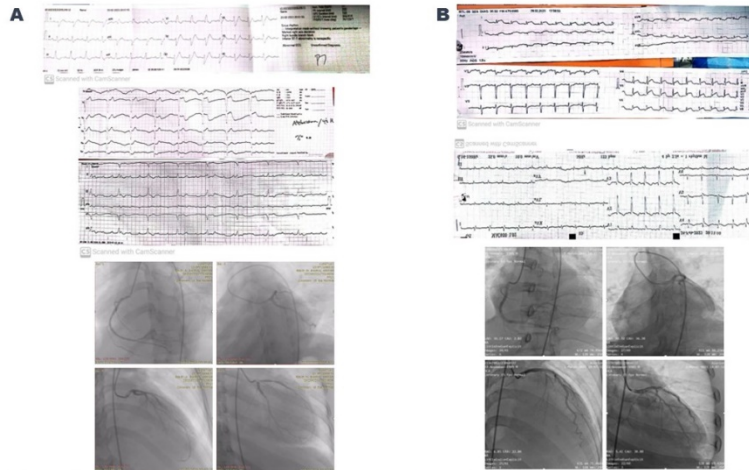


Figure 1. (A) The serial ECGs and coronary angiography of the first patient. The serial ECGs showed the progression from complete RBBB into complete AV block. The coronary angiography showed non-significant lesions with normal TIMF-3 flow. (B) The serial ECGs and coronary angiography of the second patient. The serial ECGs showed transient STEMI mimicking spontaneous reperfusion. The coronary angiography showed normal coronary arteries with normal TIMF-3 flow.

Atypical de Winter electrocardiography pattern: what is the culprit?

D.A. Rachmi¹, E.P.B. Mulia², R.A. Fagi¹
RSUD Dr. Soetomo - Universitas Airlangga¹
Dr. R. Soetrasno General Hospital, Rembang, Indonesia²

Background. The reported positive predictive value for "de Winter ECG pattern" in predicting acute left anterior descending (LAD) artery occlusion is inconsistent.

Case illustration. A 40-year-old man with chest pain for 7 hours came to the emergency room. Troponin I level was elevated. An initial 12-lead ECG demonstrated abnormal Q waves and subtle STE in leads I, aVL, STD in leads II, aVF, and upsloping STD up to 2.0-mm with tall, symmetrical T waves in leads V2 – V4 suggesting de Winter ECG changes. Therefore, extensive anterior MI with acute occlusion of the LAD was suspected (figure 1). However, the presence of prominent R waves in leads V1-V2 should raise suspicion that it might mirror the development of Q waves in posterior leads. With the addition of STE in the lead I and aVL, diagnosis of posterolateral MI is the most likely cause of this atypical de Winter pattern. Coronary angiography revealed total occlusion of the proximal LCx. The primary percutaneous coronary intervention was carried out in the LCx. Postprocedural 15-lead posterior ECG showed complete resolution of the ST segment to baseline in V2 – V4, however, abnormal Q wave and STE were found in posterior leads V7-V9 and more apparent STE in V5-V6, which further supports the diagnosis of posterolateral MI mimicking de Winter ECG pattern.

Conclusion. Posterolateral MI may present by mimicking the atypical de Winter ECG pattern. Other ECG findings, such as STE, Q wave, and R/S, and the location of the de Winter pattern in the different ECG leads should be used together to predict the culprit artery and assess the anatomical extent of myocardial ischemia. Recording posterior leads are strongly recommended in patients with atypical de Winter ECG pattern or if the ECG was still non-diagnostic of the anatomical location of MI.

Keywords: culprit artery, de Winter, posterolateral, ST-segment elevation myocardial infarction

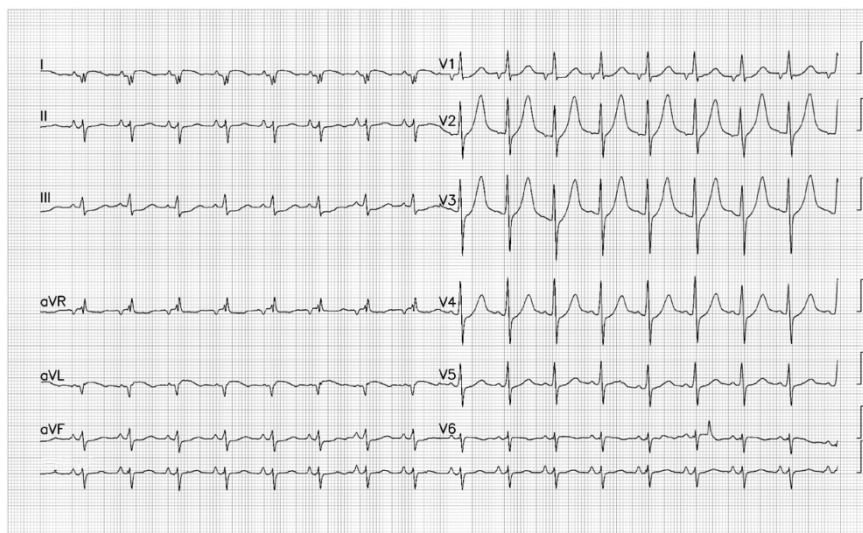


Figure 1. Initial 12-lead-ECG.

STEMI WITH ONSET >12 HOURS COMPLICATED BY HEART FAILURE IN AREAS FAR FROM ACCESS TO REPERFUSION THERAPY: A CASE REPORT

D.F. Soeharto¹, M. Dewi², R. Hermawan¹

Majenang Regional General Hospital, Central Java, Indonesia¹

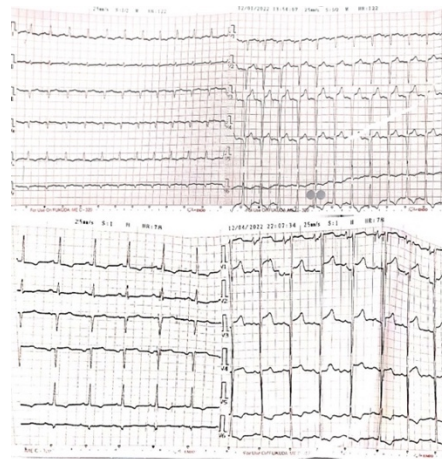Internal Medicine Department, Majenang Regional General Hospital, Central Java, Indonesia²

BACKGROUND: Total ischemic time is an important factor in ischemic heart disease. There are still many patients who are slow to seek medical attention resulting disease's onset of >12 hours during first medical contact. Percutaneous Coronary Intervention (PCI) is the first choice in cases accompanied by persistent symptoms or significant cardiovascular comorbidities. Even so, there are still areas in Indonesia that do not have access to reperfusion therapy. Therefore, an alternative clinical approach is needed in these health facilities.

CASE ILLUSTRATION: A 68-year-old male patient complained of left chest pain as if a heavy weight had been placed on him. Complaints have been felt to come and go since 6 days prior and have been aggravating since 1 day before admission. There are also symptoms of shortness of breath since 1-week before admission and swelling in both legs. Tachycardia (122x/minute), elevated JVP, rhonchi on both lungs, and pitting edema were found in physical examination. The ECG shows sinus tachycardia, LAD, LVH, ST-segment elevation in V2-V4 accompanied by Q waves in V2-V4 and T wave inversion in V5-V6. Troponin results were 395.2 ng/L and chest X-ray showed pulmonary edema and cardiomegaly. The patient was diagnosed with anteroseptal STEMI Killip II and dilated cardiomyopathy with right-left failure FC III. Primary PCI cannot be performed due to distance and clinical considerations, so conservative treatment is chosen. Intravenous vasodilators, double antiplatelets, anticoagulants, diuretics, and oral digoxin were given during treatment. The patient managed to experience clinical improvement at the end of the treatment period and was allowed to go home without sequelae.

CONCLUSION: Limited facilities are not an obstacle to comprehensive patient management. A complete, rapid, and accurate clinical assessment, as well as careful consideration of benefits and risks, greatly assists the clinical outcome of patients in limited health facilities.

Keywords: STEMI, Non-reperused, Heart Failure, Indonesia




Patient's ECG prior and after hospitalization

Aorta-Right Atrial Tunnel with Elevated Liver Enzymes: A Case Report

L.A. Huningkor¹, I. Haryana¹

Department of Cardiology, Dr. M. Haulussy General Hospital, Ambon, Indonesia¹

Background



Aorta-right atrial tunnel (ARAT) is an abnormal tubular extracardiac communication between the ascending aorta and the right atrium. It is a very rare genetic anomaly, and sporadic case reports of this disease make it vague and ill understood. In this case, we present a 21-year-old man with symptoms of heart failure and diagnosed as having the first case of ARAT ever reported in Ambon, Maluku.

Case Illustration

A 21-year-old man was referred for cardiac murmur and suspected massive pericardial effusion. He was present with shortness of breath and palpitation. The symptoms began seven days prior, including nausea, vomiting, orthopnea, and dyspnea on exertion. Physical examination found tachycardia, tachypnea, elevated jugular vein pressure, bilateral rales, continuous thrill, continuous murmur along right sternal border, distended abdomen, hepatomegaly, and lower extremity oedema. Blood test showed elevated liver enzymes; chest x-ray showed cardiomegaly, pulmonary oedema, and bilateral pleural effusion. Transthoracic echocardiography (TTE) showed a tunnel-like structure originated from non-coronary sinus, passing anteriorly to the right atrium; pulmonary arterial hypertension; and another cardiac anomaly which is an atrial septal defect. He was treated medically to relieve the heart failure (HF) and the clinical features improved. The patient was then recommended to be referred for further evaluation and surgical treatment.

Conclusion

ARAT is a very rare anomaly that can lead to right sided heart failure which can also result in abnormalities of the liver. TTE is enough to establish clinical diagnosis of ARAT but further evaluation with computed tomographic angiography of the heart, ascending aortography, or cardiac catheterization may be needed. Medical management consists of measures to relieve HF, treat coexistent arrhythmias and endocarditis. Treatment of HF may also relieve symptoms of liver abnormalities. Immediate surgery or transcatheter closure after diagnosis is recommended for symptomatic ARAT/

Keywords: Aorta, Right Atrial, Tunnel

A Case Series of Patent Foramen Ovale: Variation in Clinical Presentations and Management

J.A. Setiawan¹, S. Ng², I.M. Pardede²
Pelita Harapan University¹
Siloam Hospital Lippo Village²

Background

Patent foramen ovale (PFO) is a common congenital cardiac lesion, occurring in 25-30% of the population. Although most patients with PFO are asymptomatic, they can be associated with a variety of clinical presentations, both cerebrovascular and non-cerebrovascular related, and might significantly impair patients' quality of life. This case series aims to highlight key differences across diverse clinical manifestations and how these features play important roles in deciding the management of patients with PFO.

Case illustration

Six cases of patent foramen ovale from our center were compared and outlined in Table 1. All patients experienced cerebrovascular events in varying degrees, from a transient ischemic attack to stroke, and persisting headache was also a recurring complaint. Holter monitoring and carotid ultrasound were done in an attempt to rule out the cause of cerebrovascular events. Further risk stratification with RoPE scoring and PASCAL classification was done and patients in the probable category were managed with percutaneous PFO closure. Despite case 2 being in the possible PASCAL category, percutaneous closure was performed in consideration of her clinical presentations and quality of life. In all cases, PFO closure seemed to alleviate the chronic headaches and no new cerebrovascular events occurred in these patients.

Conclusion

PFO often presents as cerebrovascular events and chronic headaches, hence the presence of these manifestations simultaneously may prompt physicians to include PFO as a differential diagnosis, especially when other causes of cerebrovascular events have been ruled out. Risk calculations such as RoPE score and PASCAL classification remain valuable and may aid in the decision on managing PFO patients, leading to either percutaneous closure or conservative management with antithrombotics.

Keywords: PFO, migraine, stroke, RoPE, PASCAL

	Case 1	Case 2	Case 3	Case 4	Case 5	Case 6
Patient characteristics	46-year-old housewife with hypertension	41-year-old housewife	14-year-old male student	33-year-old housewife	11-year-old male student	41-year-old female with pre-excitation syndrome
Cerebrovascular clinical presentation	Recurrent cryptogenic stroke, history of multiple syncope episodes	Sudden slurred speech	Sudden right hemiparesis and aphasia	Sudden blackout episode	Sudden right hemiparesis	An episode of sudden blackout, self-resolving hemiparesis
Additional symptoms	Chronic migraine	Chronic headache	Recurring headaches	Chronic migraine	Persisting migraine for a week before	Chronic migraine
ECG pattern	Sinus rhythm (7-days Holter monitoring)	Sinus rhythm (7-days Holter monitoring)	Sinus rhythm	Sinus rhythm	Sinus rhythm	Sinus rhythm, no bradyarrhythmic episodes (7-days Holter monitoring)
Carotid ultrasound	Normal	Normal	Not performed	Normal	Not performed	Normal
Stroke pattern in imaging	Multiple lacunar infarct in bilateral frontoparietal lobe	Acute infarct in left parietotemporal lobe	Left parietotemporal infarct	No evidence of cerebral infarct in imaging	Multiple cortical lacunar infarcts in left frontal lobe	Head imaging not performed
Characteristics of PFO	High-risk morphology (atrial septum aneurysm)	Low-risk morphology	Low-risk morphology	High-risk morphology (large shunt)	Low-risk morphology	High-risk morphology (large shunt)
RoPE score > 7	Yes	Yes	Yes	Yes	Yes	Yes
PASCAL classification	Probable	Possible	Possible	Probable	Possible	Probable
Management	PFO closure	PFO closure	Conservative with aspirin	PFO closure	Conservative with aspirin	PFO closure
Follow-up	Resolution of migraine	No new cerebrovascular events	No new cerebrovascular events	Resolution of migraine and improvement of aphasia	Full motor function recovery	Resolution of migraine, no new cerebrovascular events, decreased body weight within 2 days post-closure

Table 1: Case details.

Successful Reperfusion of High Thrombus Burden in a Right Coronary Artery Presenting as ST-Elevation Myocardial Infarction Inferior and Symptomatic Bradycardia: A Case Report

A.A. Budiarto¹, Ahadi², R. Herdyanto³

Medical Intern, Dr. R. Sosodoro Djatikoesoemo General Hospital, Bojonegoro, Indonesia.¹

Cardiologist, Dr. R. Sosodoro Djatikoesoemo General Hospital, Bojonegoro, Indonesia.²

Interventional Cardiology, Dr. R. Sosodoro Djatikoesoemo General Hospital, Bojonegoro, Indonesia.³

Background

High thrombus burden (HTB) may lead to no-reflow, slow-reflow, and/or distal embolization. HTB in patients with acute myocardial infarction (AMI) with complication bradycardia is a significant cause of morbidity and mortality worldwide and its management is very challenging.

Case Illustration

A 60-year-old man with chest pain for one hour at rest with diaphoresis, dizziness, nausea, and abdominal discomfort. He had more than 40 years of smoking history. The patient had no history of hypertension, hepatitis, diabetes mellitus, cerebrovascular disease or other health problems. On examination, he was in pain (VAS 5/10) with a blood pressure of 100/60 mmHg and a heart rate of 45 beats per minute, which was irregular. Killip classification was class I. His electrocardiogram (ECG) showed ST-segment elevation in leads II, III, and aVF with 2nd Degree AV block Mobitz type 2. Aspirin 300 mg, ticagrelor 180 mg, atorvastatin 40 mg and 1 mg sulfa atropine were administered. He was immediately transferred to our hospital for primary percutaneous coronary intervention (PPCI). Coronary angiography (CAG) was performed directly under temporary ventricular pacing. Coronary angiography revealed a right coronary artery (RCA) that was completely occluded in the proximal with a high-burden thrombus (fig 1A). He was managed successfully with triple antiplatelets (aspirin, ticagrelor, and intracoronary GIIb/IIIa inhibitors), anticoagulation, and adjunctive PCI (aspiration thrombectomy and three stents were accurately implanted into the culprit's vessel). arrhythmia was observed during this process and the final angiogram showed flow in the proximal RCA with TIMI flow 3 (fig 1B).

Conclusion

This case report demonstrates successful treatment HTB use of aggressive antiplatelet, anticoagulation, PPCI and temporary pacemakers in STEMI patients with bradycardia but maybe this treatment can't be effective in another case because there is no ideal management strategy.

Keywords: High thrombus burden, STEMI, temporary pacemakers, PCI

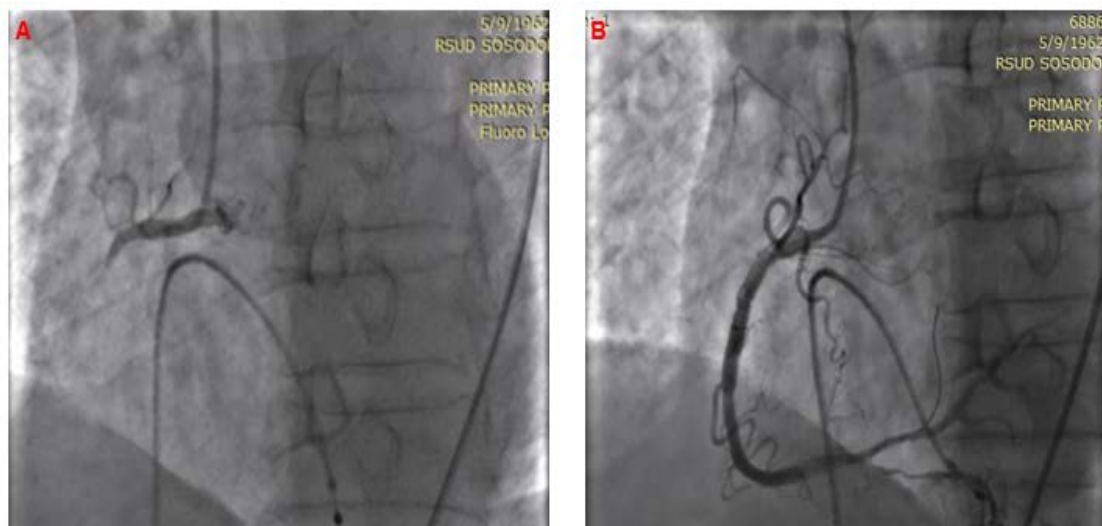

Fig 1. The right coronary artery of a 60-year-old male patient at the (A) beginning and (B) end of the primary percutaneous coronary intervention procedure.

Management of Acute Coronary Syndrome Presenting with Acute Heart Failure in Rural Area: A Case Report

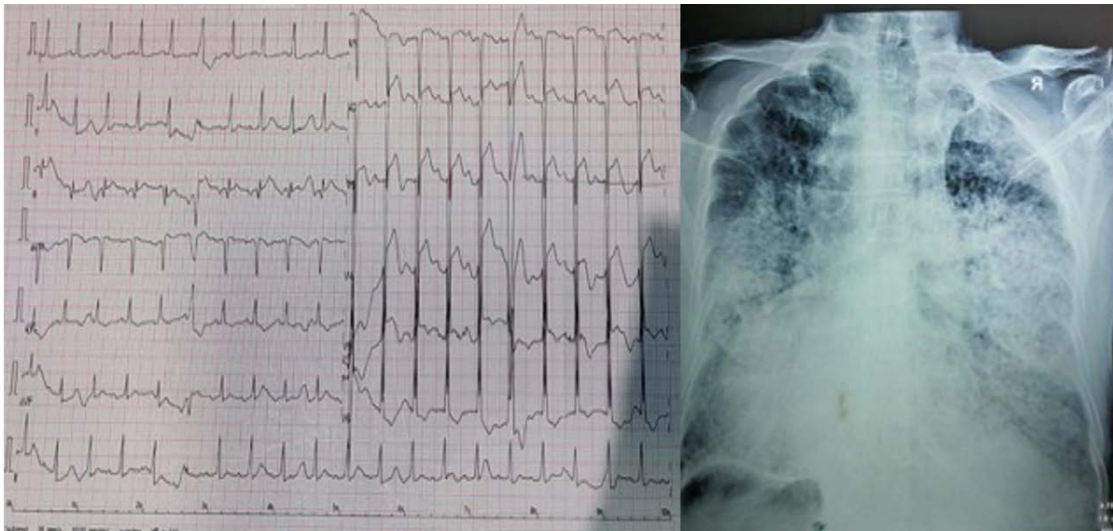
Y.D. Tanugerah¹, D.N. Sary¹
RSUD Muhammad Zein Belitung Timur¹

Background: AHF is defined as the sudden emergence of new or worsening heart failure symptoms. ACS is one of the most important causes of AHF. AHF in the setting of acute coronary syndromes is closely associated with reduced survival rates, both during hospitalization and in the long term. Mortality and hospitalization rates are also high in cases of AHF with ACS. The diagnosis of AHF and ACS is made by clinical presentations, ECG, serial cardiac troponin, and emergency echocardiography. In addition, patients with ACS and AHF should immediately undergo coronary angiography and PCI.

Case illustration: We reported a case of a 74-year-old man, without any previous medical history, presenting with shortness of breath and chest pain 2 hours before admission. The physical examination showed high blood pressure, desaturation, and cold extremities. Crackles and wheezing were heard in both lungs. The electrocardiogram (ECG) showed elevation of ST segment in precordial leads. Chest X-Ray showed bilateral pulmonary oedema of both lung fields. The patient was treated conservatively with only oral medications due to limited facilities and resources in the rural area.

Conclusion: ACS with AHF is a high-risk group with a mortality rate of 4.2%-5.5% and 1-year mortality rate is 20.6%-26.7%. AHF treatment should be given when required to stabilize the patient and concurrently with the start of ACS therapy. This case report showed adequate conservative therapies based on guidelines had good outcome in patients with ACS and HF.

Keywords: Acute Heart Failure, Acute Coronary Syndrome



ECG and X-Ray examination shown in Emergency Room

SURGICAL APPROACH FOR PATIENT WITH VENTRICULAR SEPTAL DEFECT, MEMBRANOUS SEPTAL ANEURYSM AND LARGE TRICUSPID VALVE VEGETATION

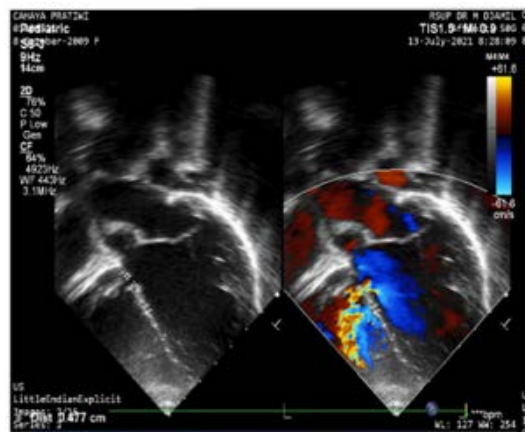
F.A. Azmi¹, D. Hariyanto¹, Kino¹
Universitas Andalas¹

Background: Ventricular septal defect (VSD) is the most common heart malformation and estimated about 25% of CHDs. One of the long-term risks of VSD is infective endocarditis (IE). Aim of this report is to discuss surgical approach for patient with VSD, membranous septal aneurysm, and large tricuspid valve.


Case Illustration: A 12-year-old girl presented with repeated high fever. There was history of shortness of breath after heavy physical activity. The patient was known for suffering from perimembranous VSD since 3 years old. There was history of repeated cough, cold, and reduced appetite. Body temperature was 38.3°C. Nutritional status was under-weight. Auscultation was grade 3/6 pansystolic murmur on LLSB, which extended laterally, and intensity didn't increase with inspiration. Laboratory examination showed leukocytosis. ECG results sinus rhythm, LAD and LVH. Chest X-ray showed CTR of 60% and plethora. Echocardiography showed VSD PM 3-5 mm, left-right shunt and vegetation in septal tricuspid leaflet. Patient was given vancomycin 2x500 mg, gentamicin 1x75 mg, paracetamol 4x300 mg, and captopril 2x6,25 mg. Blood culture was positive for *Streptococcus mitis* and *Streptococcus orafis*. Patient was diagnosed with definite infective endocarditis met two major criteria of Duke's modified. Open heart surgery, VSD surgical closure, and evacuation of vegetation were conducted. We didn't conduct catheterization of the right heart due to vegetation which may complicate as pulmonary embolism if detached.

Conclusion: We have described a girl diagnosed with VSD PM L-R 3-5 mm shunt with IE. The shunt left-to-right made it easy for the occurrence of IE due to existence of turbulent flow on VSD. IE is natural history of VSD, thus emphasizing the urgency of early diagnosis and management when IE is detected.

Keywords: Ventricular septal defect, Membranous Septal Aneurysm, endocarditis infective, vegetation



Transthoracic Echocardiography shows 3-5 mm VSD L-R shunt, MSA and vegetation of tricuspid septal leaflet.



Sildenafil Therapy in a 42-Year-Old Man with Pulmonary Hypertension and Acute Renal Failure: A Case Report

M.Destiani¹, N. Anggita²

¹General Practitioner, Kramat Jati Hospital, East Jakarta

²General Practitioner, Hermina Bitung Hospital, Tangerang

Background: Pulmonary hypertension (PH) is one of the world's health issues, its prevalence is estimated at 1% of the world's population and increases to 10% at the age of >65 years. PH is defined as an increase in MAP >20 mmHg. PH is a rare disease, but has high morbidity and mortality rate.

Case Illustration: A 42-year-old man came to emergency room with swollen legs since 2 weeks ago and shortness of breath, he was often sleeping with high pillows. His stomach was getting bigger, accompanied by nausea, vomiting, reduced urine volume. The patient has history of pulmonary tuberculosis treatment. There was increase in respiratory rate (28x/min), oxygen saturation of 74% on room air. Physical examination revealed ronchi in both lung fields, ascites, pitting oedema of inferior extremities. ECG showed RAD axis. Laboratory showed mild thrombocytopenia (141,000), elevated urea (105), blood creatinine (2.4). Chest x-ray resulted cardiomegaly, LAE, RVH. The patient was diagnosed with CHF caused by RHD. The therapies were furosemide 3x40 mg, HCT 1x25 mg, bisoprolol 1x2.5 mg, folic acid 3x1, bicarbonate 3x1, and CaCO₃ 3x1. On the third day of treatment, the patient experienced worsening shortness of breath, hypotension (70 mmHg/palpation). The patient was transferred to HCU with dobutamine 5mcg/kg/minute. At the maximum dose of dobutamine, the patient was still hypotensive, received norepinephrine 0.2 mcg/kg/minute. Echocardiography resulted LVEF 70%, grade I diastolic dysfunction, TR Severe High Probability for PH. The patient received sildenafil therapy 3x10 mg, on the third day, the dose was increased to 3x20 mg. The patient experienced clinical improvement after five days of using sildenafil.

Conclusion: Sildenafil is a class of PDE-5i and is one of therapies for patients with PH. PDE-5i degrades cGMP and causes vasodilation in pulmonary blood vessels where the enzyme is widely excreted.

Keywords: Keywords: Pulmonary Hypertension, Sildenafil

A Tale of Success: Pericardial Effusion in Pediatric Lupus and Rheumatic Fever

I.P. Farissa¹, H.H. Satoto¹, Y. Herry¹, F. Tandri¹

Department of Cardiology and Vascular Medicine, Medical Faculty Diponegoro University¹

Background

Acute rheumatic fever (ARF) is caused by autoimmune response to a group A streptococcal infection. ARF largely affects children between the ages of 5–14 years with risk factors including age, sex, environment, and host susceptibility. Pediatric systemic lupus erythematosus (SLE) is a rare entity, affecting children under 16 years of age. Diagnosis is not always easy. Pericarditis is the most frequent cardiac manifestation of SLE, occurring in 10% to 40% of cases.

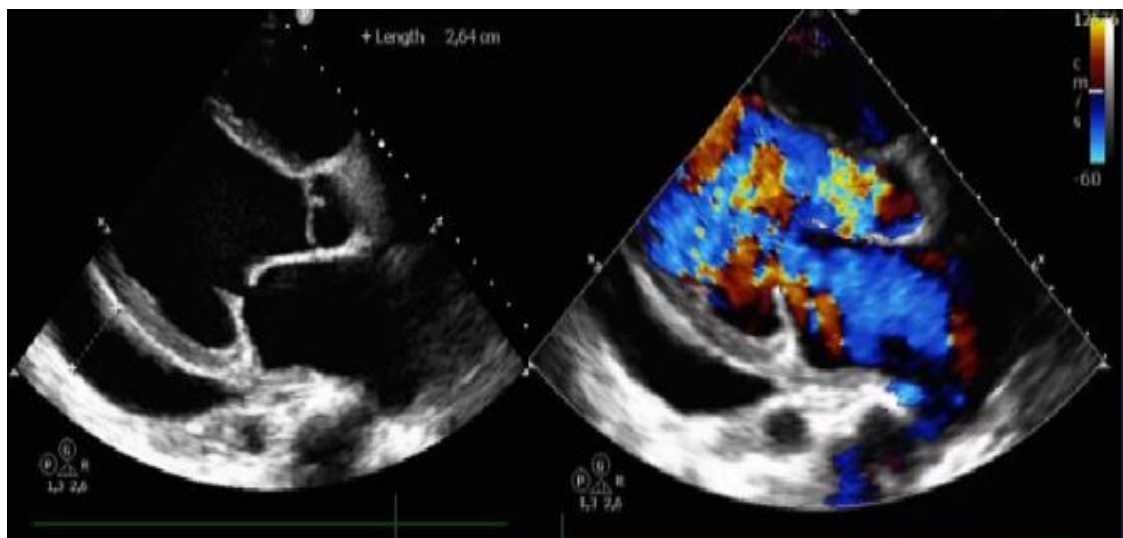
Case Illustration

A-16 years old boy referred with breathlessness 2 weeks prior to admission, not relieved with resting and position changes, accompanied with fever, coughs, odynophagia, and migrating joint pains. He was severely ill, with pressure 113/82 mmHg pulse 113 bpm respiratory rate 30x/min, temperature was 37 °C, pansystolic murmur grade IV/6 in apical area, diastolic murmur grade II/4 in Erbs area, gallop. The Laboratory result was leucocytosis, anaemia, elevated ESR, positive ASTO test, positive ANA and ds DNA test. Oropharyngeal swab revealed positive grams diplococcus and blood culture was positive for *Klebsiella oxytoca*. The echocardiography revealed severe aortic and mitral regurgitation with massive pericardial effusion without tamponade signs. We managed with high dose of steroids, antibiotics, colchicine, and NSAIDs. The evolution was favorable and echocardiography evaluate no longer pericardial effusion.

Conclusion

The diagnosis of ARF cannot be made using a single test, requiring recognition of a complex of clinical signs divided into major and minor manifestations as well as laboratory investigations aided by application of the Jones criteria. Pediatric-onset SLE diagnosis and management with heavy treatment in a growing being poses some specific problems. Pericardial effusion may happen in pediatric with SLE and ARF requiring prompt management. The use of corticosteroid therapy and treatment with proper adequate antibiotics is crucial in managing pericardial effusion and ARF.

Keywords: Massive pericardial effusion, Pediatric-onset SLE, Acute Rheumatic Fever



Echo initial

Global Longitudinal Strain as predictor of Myocardial Damage in Severe Mitral Regurgitation with Normal Ejection Fraction

M.R. Priatama¹, A.S. Kuncoro²
Universitas Indonesia¹
National Cardiovascular Center Harapan Kita²

Background

Myocardial strain imaging using GLS is a novel approach for assessing left ventricular function. From the previous study, GLS already deteriorated even when EF is still preserved, indicating that GLS may be superior in detecting myocardial damage. It can be suggested that GLS may also have a role in assessment of mitral regurgitation (MR), especially in severe MR with preserved EF where early detection of myocardial damage is needed for making clinical decisions.

Case Illustration:

A male, 57 years old came to NCCHK, with fatigue and DOE. Patient sleep with 2 pillows stacked and he often wakes up at night due to shortness of breath and cough. There are no chest pain or rapid heart rate. The patient complained a presenting symptoms six months prior to the admission. These symptoms were amplified during mild activity. The echocardiography shows eccentric left ventricular hypertrophy, left ventricular systolic function was normal, dilated left atrium, flail of PML with posteromedial commissure lesion and severe mitral regurgitation splay. GLS score was -16,3 %.

Conclusion:

GLS is more superior than EF in prediction of myocardial damage in patients with severe MR. Measurements using EF, LVESD and LVEDD are more load dependent, which GLS are less dependent. GLS also have potential role in clinical decision making for timing of intervention in severe MR with preserved LVEF.

Keywords: Keywords: Speckle Tracking Echocardiography, Global Longitudinal Strain, Mitral Regurgitation

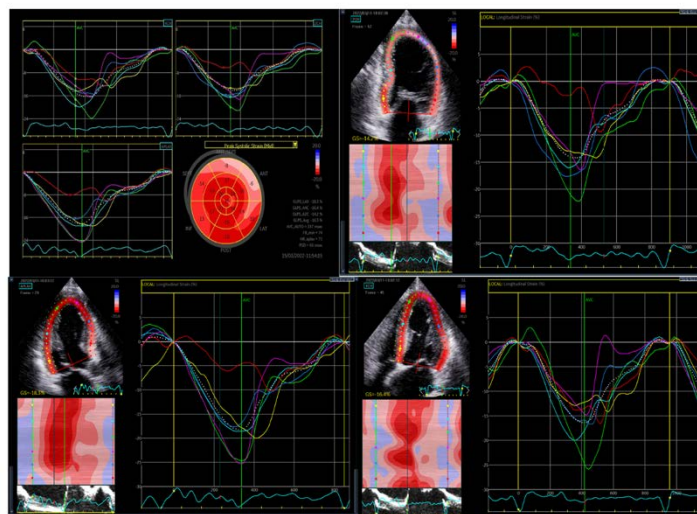


Figure 1. GLS Score -16.3

Protruding Stent into Left Ventricle : When Handmade Covered Stent wasn't Enough

V.B.F.P. Untu¹, J.A. Pangemanan¹, G.E.H. Reppi¹, H.J. Sunarto¹

Department of Cardiology and Vascular Medicine, Faculty of Medicine, Sam Ratulangi University, Prof. Dr. R.D.Kandou General Hospital, Manado, Indonesia¹

Background:

Coronary artery perforation is one of the most dreadful complications and still convey high mortality risk. Presence of contrast extravasation through frank perforation demand fast and precise decision to prevent further worse outcome.

Case illustration:

A-59 years old man was admitted to emergency department (ED) with chest pain. After careful anamnesis and physical examination, patient was diagnosed with acute ST segment elevation anterior myocardial infarction and sent to the catheterization laboratory. Right radial access was used and coronary angiography at Left Anterior Descending (LAD) artery shows total occlusion. After first Drug Eluting Stent (DES) placed, there is massive contrast extravasation in LAD artery (Ellis type III). Balloon was inflated to compress the perforation, while a second puncture was added through right femoral artery to treat the Right Coronary Artery (RCA) lesion. After delivered one DES stent in RCA, balloon was deflated and there is still massive contrast extravasation. Echocardiography was used to evaluate cardiac tamponade and there is minimal (<10mm) pericardial effusion. Attempt to stop perforation was made with two stacks of DES in Left Main (LM) artery, but failed. Handmade 'tegaderm' covered stent was deployed in LM-LAD artery, but contrast extravasation is still present. Echocardiography was used once again and found that stent was protruding into left ventricle base. Procedure was stopped due to maximum contrast was reached. Patient was given additional anticoagulant drug. Consulting with thoracic surgeon was made to retrieve stent surgically, but patient declined. Confirmation with computerized tomography (CT) scan found there is stent from LAD branch to left ventricle with probability of fistula.

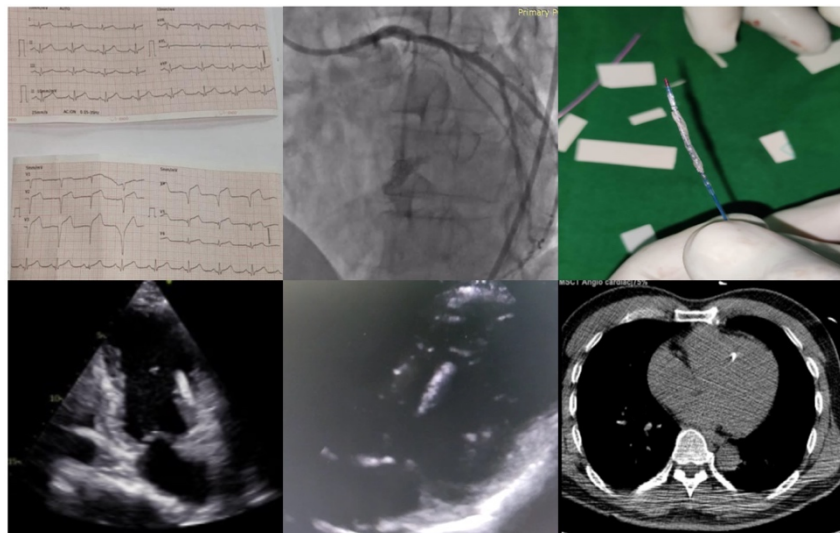
Conclusion:

Contrast extravasation with contrast staining can help to differentiate between coronary perforation to pericardial and into the cardiac chamber. Handmade 'tegaderm' covered stent may be considered if there is no other option.

Keyword:

Coronary Perforation, Protruding Stent, Handmade Covered Stent

Keywords: Coronary Perforation, Protruding Stent, Handmade Covered Stent





Indonesian Journal of Cardiology

Indonesian J Cardiol 2023;44:suppl_A
pISSN: 2830-3105 / eISSN: 2964-7304
doi: 10.30701/ijc.1537

Protruding Stent into Left Ventricle

Surviving the Storm: A Case Report of Myasthenic Crisis in Acute STEMI Patient

D. Nugraha¹, I.P. Farissa¹, S. Sungkar¹

Department of Cardiology and Vascular Medicine, Faculty of Medicine Diponegoro University- Dr. Kariadi Central General Hospital, Semarang, Indonesia¹

Background

Myasthenia gravis is an autoimmune disorder affecting neuromuscular transmission leading to muscle weakness. Myasthenic crisis is life-threatening complication, resulting in respiratory failure that requires intubation and mechanical ventilation. Cardiovascular event in patients with myasthenia gravis are rare, but clinicians should bear in mind the potential adverse interaction between myasthenia gravis and cardiovascular disease or its medications. We present a case of acute STEMI patient concomitant with myasthenia gravis which developed into myasthenic crisis.

Case Illustration

A 56 years old woman came to ER with typical chest pain 1.5 hours prior to admission. She has medical history of myasthenia gravis, dyslipidemia, but didn't take medication routinely. Vital sign and physical examination was normal. The ECG showed ST elevation in anterior extensive lead. Laboratory test revealed elevated troponin. Chest x-ray showed cardiomegaly LA and LV. Echocardiography showed LVEF 40.7% with hypokinetic anterior, anterolateral segment at basal-mid level, apicoanterior. Patient was given loading dose of acetylsalicylic acid, clopidogrel, and statin. The patient underwent fibrinolytic with 1.5 million IU dose of streptokinase, since primary PCI couldn't be performed. Chest pain was relieved and ECG showed ST elevation resolution indicating successful fibrinolytic. She developed myasthenic crisis that led to respiratory distress at 12-hours admission in ICCU, was managed with ventilator, neostigmine intravenous, corticosteroids and plasmapheresis. Patient condition was improved, extubated, and discharged 1 week later.

Conclusion

Myasthenic crisis is a life-threatening complication of myasthenia gravis. Precipitating factors should be quickly identified and promptly mitigated. It is possible that myocardial infarction or cardiovascular medication could trigger myasthenic crisis in some individuals. However, it is important to note that the relationship between them has not fully understood, and further research is needed to confirm this potential link.

Keywords: Acute STEMI, myasthenia gravis, myasthenic crisis

Precipitants of Myasthenia Crisis

Stressors	Medications
Physical stressors	Cardiovascular medications beta blocker (all, including topical beta blocker, e.g. timolol eye drops and combined alpha and beta blocker, e.g. labetalol) calcium channel blockers (verapamil, nifedipine)
Emotional stressors	Class I anti arrhythmic drugs (quinidine, procainamide)
Infection	Glibenclamide
Pain	Lidocaine (systemic dosing)
Pregnancy	Statins
Surgical procedure	Anti psychotics Phenothiazines, sulpride, atypicals, (clozapine)
Tapering of immune-suppressive drugs	Neuromuscular-blocking drugs Succinylcholine, vecuronium including ocular proparacaine Anticholinergic drugs Chlorpromazine Neurologic and psychoactive drugs Lithium Pitavastatin Carbamazepine Trifluoperazine Imetastatibone Antibiotics Aminoglycosides (amikacin, gentamicin, streptomycin) Quinolones (ciprofloxacin, ofloxacin, norfloxacin) Lincomycin (including clindamycin) Macrolides (doxycycline, erythromycin, oxytetracycline, tetracycline, azithromycin) Anti malarials (chloroquine, hydroxychloroquine, quinine) Penicillins (including ampicillin and imipenem cilastatin)

Precipitants of myasthenic crisis

Complete RBBB without the Presence of Cardiovascular Disease: Not Inconsequential as Previously Thought?

S. P. Yogita¹, S. A. N. Y. Sutarmini², I G. A. B. K. Jayantika²

Intern of Cardiology and Vascular Medicine, Bali Mandara Regional Public Hospital, Indonesia¹

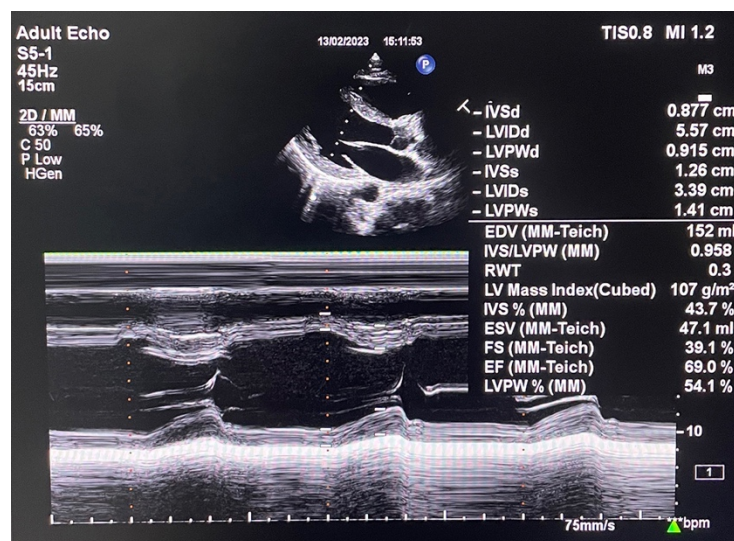
Departement of Cardiology and Vascular Medicine, Bali Mandara Regional Public Hospital, Indonesia²


Background: With a prevalence ranging from 0.2% to 2.3%, right bundle branch block (RBBB) is one of the most common electrocardiography (ECG) findings in clinical practice. It is still unknown whether RBBB increases the risk of coronary artery disease (CAD). Bundle branch block is frequently associated with myocardial infarctions, myocarditis, and cardiomyopathy (BBB). Unfortunately, isolated RBBB without structural heart disease remains a possibility. This case study adds to the growing body of evidence that isolated RBBB is not a trivial finding.

Case Illustration: A 17-year-old male came for a medical check-up since he will be going to police academy. At the polyclinic, the patient was fully conscious with a blood pressure of 120/80 and pulse rate of 58 bpm. He had no symptoms of chest pain or shortness of breath. The patient lives a healthy lifestyle, which includes activities like jogging and running around the park every day. He smokes but only a few cigarettes a month, sometimes even less. There were no other risk factors for coronary artery disease. The patient then proceeded with an ECG, which showed a complete right bundle branch block with normal sinus rhythm, no signs of ischemic and no signs of infarct. Echocardiogram (transthoracic) showed no regional wall motion abnormality with normal left ventricle (LV) ejection fraction. We suggested to proceed with a CT-Angiography but the patient refused, hence the patient went home without any medical treatment.

Conclusion: Right bundle-branch block has been linked to an increased overall risk of mortality and cardiovascular-related mortality in patients without known cardiovascular disease, as well as a higher frequency of hypertension and more exercise-related limitations, such as decreased aerobic capacity, slower heart rate recovery, and more dyspnoea on exercise testing. However, performing a comprehensive assessment to monitor patients with asymptomatic RBBB imposes a massive healthcare burden.

Keywords: right bundle branch block (RBBB), isolated RBBB, complete RBBB





Tolvaptan Use In Low Cardiac Output State Caused By Combination of Aortic And Mitral Stenosis : Hemodynamic Management For Bridging To Surgery

F Tandri¹, I.P. Farissa¹, R. Hidayatulah¹, M. F. Ahnaf¹
Dr. Kariadi Hospital¹

Background

Heart failure caused by low cardiac output state in aortic stenosis (AS) dan mitral stenosis (MS) has poor prognosis with high risk for surgery. The use of loop diuretic to relieve the congestion may induce hyponatremia, worsening cardiac output reduction, hypovolemia, and critical hypotension in this condition. Tolvaptan acts as vasopressin receptor antagonist, helps to maintain hemodynamics and seems to be appropriate in this condition. Therefore, we present the case of tolvaptan's effects and safety in patients with heart failure caused by severe AS and MS.

Case Illustration

A 35-year-old man scheduled for Double valve replacement surgery complained of exertional dyspnea, altered mental state, ascites, and leg swelling. He has ejection systolic murmur at second right intercostal spaces close to the sternum and mid-diastolic murmur at the apex. Laboratory test showed hyponatremia. Chest X-ray showed cardiomegaly, congestive pulmonum, and pleural effusion. Echocardiography revealed severe AS and MS with preserved LV function (EF 55%). At initial treatment, maintenance dose of furosemide was given but the congestion persisted.

After hemodynamic stabilization, Tolvaptan 7,5 mg was added to optimal medical therapy. Dyspnea, ascites and leg swelling were improved. It didn't cause hypotension significantly (BP 89/68 to 85/69). Urine output increased significantly (750 to 2500cc/day). There was improvement of hyponatremia (127 to 137 mmol/L) after 5 days administration, no worsening of kidney function (creatinine serum 1,13 mg/dL to 1,2 mg/dL). Echocardiography also showed no hypovolemia (IVC 25/19) and no worsening of aortic (VTI 0.4cm² to 0.4cm²) and mitral valve flow (VTI 0.8cm²- VTI 0.7cm²) Patient maintained stable heart failure and improvement of quality of life until 1-week follow-up.

Conclusion

Tolvaptan use in low cardiac output state caused by combination of AS and MS with heart failure is safe before double valve replacement surgery.

Keywords: Tolvaptan, Heart Failure, Aortic Stenosis, Mitral Stenosis, Double Valve Replacement Surgery

STEMI WITH DIABETIC KETOACIDOSIS, HOW TO MANAGE?

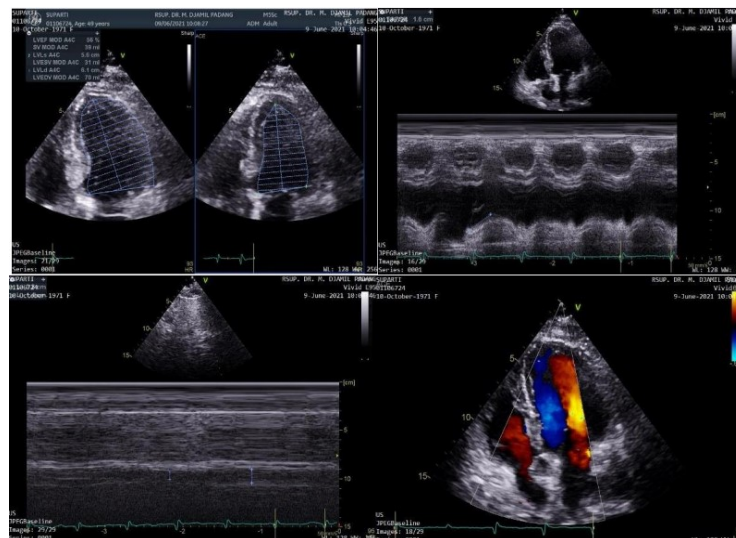
F. Yuliani¹, Y.R. Ilhami¹, W. Erlanda¹
RSUP Dr M DJAMIL PADANG¹

Background: Diabetic ketoacidosis (DKA) is an acute life-threatening complication of diabetes mellitus that be signed by trias hyperglycaemia, acidosis, and ketosis. DKA can also be seen concomitantly with a STEMI. Fluid resuscitation to treat DKA could be dilemmatic problem in STEMI patient.

Case illustration: A 49 years old woman referred to hospital with sudden chest pain since 7,5 hours before admission. Her physical examination showed she was fully alert, with blood pressure 123/78 mmHg, heart rate 60 beats/min, and minimal rales in both lung fields. Blood gas analyse showed metabolic acidosis, pH 7.32, PCO₂ 28 mmHg PO₂ 169 mmHg HCO₃⁻ 15 mmol/L BE - 11.2 mmol/L, SO₂ 99%. Random blood glucose was 526 mg/dL, osmolarity was 316 and fluid deficit 3 liters. Her electrocardiogram showed total AV blocked with ST elevation 1-4 mm at II, III, AVF, V3R-V4R. The patient underwent Temporary Pacemaker and Primary Percutaneous Coronary Intervention in Right Coronary Artery while giving critical ill insulin and fluid therapy with saline 1,5 L. Patient then admitted to CVCU. In CVCU, the patient looked somnolent and Kussmaul breathing with urine ketone (++) . We assessed as diabetic ketoacidosis and administrated fluid resuscitation around 3,75 L. Echocardiography revealed EF 43%, TAPSE 1,1, SV 39 ml, CO 4L/i, SVR 1640 dyne.sec/cm⁵, normal IVC, collapsibility index 22% and central venous catheter (CVC) pressure 12 mmHg. We did strict echocardiography and CVC monitoring. Patient symptom and hemodynamic were improved and discharged at day 10.

Conclusions: When STEMI patient concomitant with DKA, fluid therapy may need to be modified. Volume status and cardiac performance monitoring using central venous catheter and echocardiography should be controlled intensively.

Keywords: Diabetic Ketoacidosis, STEMI, Fluid Therapy



Left Ventricular Free Wall Rupture with Pseudoaneurysm following Inferoposterior Myocardial Infarction: A Case Report

F.A. Habibi¹, S. Safitri², R.M. Candrasatria³
Puskesmas Gunung Sari Pesawaran Lampung¹
RSUD Menggala²
RSUD Dr.H.Abul Moeloek Provinsi Lampung³

Background

Free wall rupture of the left ventricle (LV) is a mechanical complication following myocardial infarction leading to fatal condition. In rare case, free wall rupture can be forming a pseudoaneurysm. The diagnosis and treatment are challenging.

Case Illustration

A 57-year-old male with history of hypertension and smoking, was presented to emergency departement with chief complain of intermittent central chest pain, dyspnea, fatigue for two days. To give a brief background, he had a history of a posteriorlateral STEMI 6 weeks earlier without revascularisation therapy. On physical examination, blood pressure was 96/64 mmHg, heart rate 106 bpm, respiratory rate 23 breaths/minute, systolic murmur in apex, no rales. Electrocardiogram was showing sinus rhythm, with ST segment depression in lead V2-V4 and T wave inverted in lead V4-V6, I and aVL. Laboratory study revealed increased WBC: 18750/mL, increased creatinine level: 1,42 mg/dL, CKMB: 15 U/L. Chest X-ray revealed an oval bulge on the left border of the heart and more prominent left cardiac silhouette compared to previous his chest X-ray, cephalisation. He underwent a TTE which accidentally showed LV wall ruptured at basal until mid inferolateral and formed pseudoaneurysm with narrow neck (3 cm), turbulent bidirectional flow showed by colour Doppler, no thrombus, LV dilatation, moderate MR, EF 35%, mild pericardial effusion. He was diagnosed with LV free wall ruptured with pseudoaneurysm and history of late onset posterolateral STEMI. He was given intravenous diuretic, ACE inhibitor, nitrate and beta-blocker. Then, the patient was referred to Harapan Kita National Heart Center for further therapy. He underwent a successfull surgical repair.


Conclusion

Our patient presented with previous MI and non-specific symtoms but with clinical suspicion finally was leading to find a rare mechanical complication of MI through non-invasive imaging. So the patient could get early appropriate management.

Keywords: Pseudoaneurysm, cardiac rupture, myocardial infarction, case report

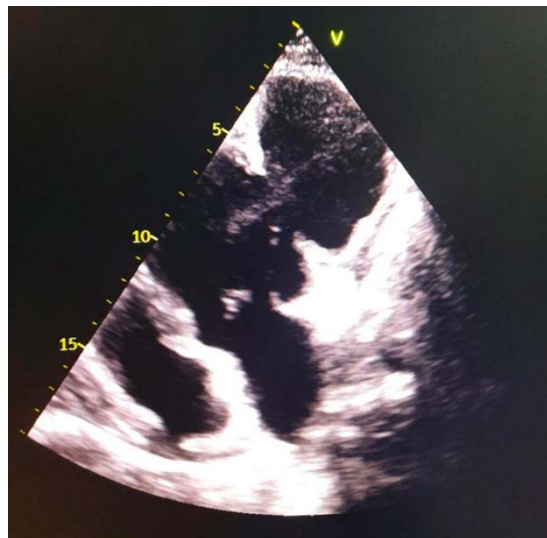

Figure 1. Transthoracic echocardiography



Successful Suppression of Electrical Storm Using A Combination of Medications in The Setting of Acute Coronary Syndrome : A Case Report

A. Siagian¹, P.S. Prameswari¹, S. Laksono¹

Department of Cardiology and Vascular Medicine, RS Jantung Diagram Cinere, Depok, Indonesia¹

Background Electrical storm is a rare but life threatening condition with high mortality, occurring as complication in 6% of acute coronary syndrome cases. It is defined as a clustering of three or more separated ventricular arrhythmia in 24 hours. The focus of treatment in electrical storm is to stabilize the patient, identifying the etiology, and prevent recurrence.

Case Illustration A 49 year-old male was taken to our emergency department complaining of chest pain and shortness of breath since one day. He was previously hospitalized with non-ST elevation myocardial infarction and acute heart failure 10 days before admission. On presentation unstable ventricular tachycardia (VT) was noted. Immediate electrical cardioversion achieved conversion into normal sinus rhythm, but episode of sustained VT returned and the patient was diagnosed with electrical storm. Signs of acute heart failure were found : tachypnea, bilateral rales, distended jugular vein, and pulmonary edema seen on chest x-ray. The patient was diagnoses with NSTEMI according to elevated troponin T. A few hours after admission, cardiac arrest occurred and the patient was placed on mechanical ventilation. Due to acute kidney injury and lack of hemodialysis facility in our hospital, we did not perform percutaneous coronary intervention (PCI) that should be the main focus in treating electrical storm induced by ischemia. Instead, we opted to treat the patient conservatively with a combination of heparinization, dual antiplatelet therapy, treatment of heart failure, and combination of amiodarone and lidocaine as antiarrhythmics.

Conclusion We opted to treat the patient conservatively without PCI. Our patient probably benefited from administration of lidocaine, an antiarrhythmic that is especially useful in ischemic cellular condition. Sedation and treatment of heart failure with diuretics, ACE-inhibitor, and beta blocker also contributes to the suppression of electrical storm.

Keywords: acute coronary syndrome, arrhythmia, electrical storm, heart failure

Left Ventricular Thrombus in a Child with Reduced Left Ventricular Ejection Fraction that treated with Rivaroxaban : A Case Report

M. Irfan¹, M.R. Enoch¹, A. Hardin¹

Department of Cardiology Abdul Aziz Hospital, Singkawang, West Borneo, Indonesia.¹

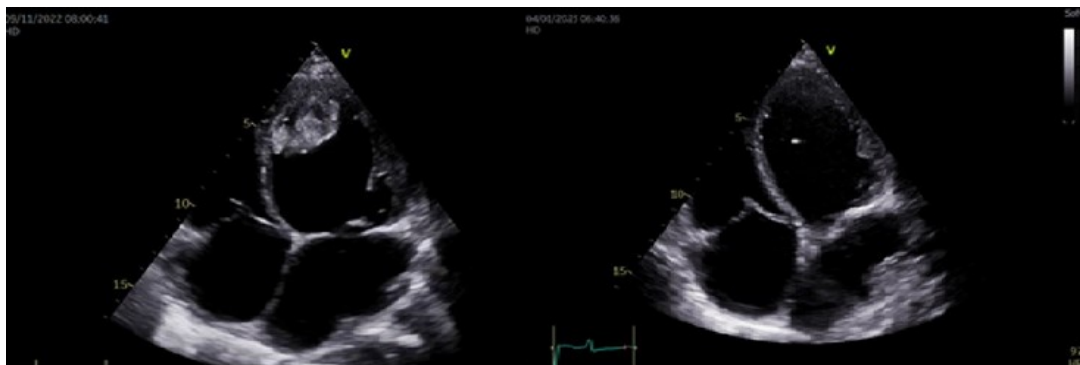Abstract

Background: Intracardiac thrombus are a complication of dilated cardiomyopathy (DCM). Factors implicated in the formation of thrombus in DCM include low-velocity swirling of blood, abnormal endocardial surfaces, atrial fibrillation, and a hypercoagulable state. The most common site for thrombus in DCM is the apex where blood flow is generally slowest. However there is no recommendation for treating thrombus in children. Here we present a case of young children with intracardiac thrombus treated with rivaroxaban for 3 months.

Case Illustration: A 14 years old female came to Hospital with chief complaint of dyspnea. The vital signs on normal value, with minimal crackles. The Laboratory showed rheumatoid factor were positive with other parameters in normal ranges. The electrocardiogram showed sinus rhythm with left ventricular hypertrophy. Echocardiography showed a thrombus in the left ventricle (LV) with the size is 18x35 mm and decreased of ejection fraction with global hypokinetic. The patient was treated with rivaroxaban for 3 months. The next echocardiography showed the thrombus had disappeared without any complications.

Conclusion: LV thrombus can occur due to several factors and one of them is a decrease in ventricular ejection fraction. There is no still guideline recommendation for treating of LV thrombus in children using direct oral anticoagulation. Systemic anticoagulation is indicated when there is evidence of thromboembolic or intracardiac thrombosis. Rivaroxaban has shown to have success as a thrombus dissolution agent among the other agents in adult patient. However we didn't know the etiology of DCM and thrombus formation for this patient. Rivaroxaban administration in pediatric patients with LV thrombus can reduce or even eliminate the thrombus. Further investigation of rivaroxaban is need to be investigated.

Keywords: LV thrombus, dilated cardiomyopathy, rivaroxaban



Pre and post treated with rivaroxaban for 3 months.



Transient Diffuse ST Segment Depression in a Patient with High-Grade Fever: A Diagnostic Pitfall


Y.N. Afifah¹, E.D.N. Rahmawati¹
PKU Muhammadiyah Gamping Hospital, Yogyakarta¹

Background : High-grade fever is defined as a body temperature above 39°C. Body temperature is known to affect the cardiovascular system. However, it is rare for high-grade fever to induce ST segment depression, which can be a diagnostic pitfall as it mimics coronary occlusion.

Case illustration : A 71-year-old female with a history of arrhythmia and hypertension was admitted to the emergency department complaining of fever and chills without any chest pain. She had a body temperature of 41.7°C, elevated blood pressure at 148/66 mmHg, and tachycardia at 110 beats/min. Physical examination revealed cardiomegaly. Echocardiography showed hypertensive heart disease and 64% ejection fraction. Laboratory examination showed normal electrolyte levels, neutrophilia, lymphopenia, and a grey-zone HS Troponin result of 13.80 ng/L. Routine urinary examination suspected cystitis. Electrocardiography displayed sinus tachycardia with diffuse ST segment depression. She was resuscitated with IV hydration and paracetamol infusion. Her temperature returned to normal followed by the ST segment returning to the baseline on serial electrocardiography. Her previous Holter monitoring 1 month earlier confirmed no history of ST segment changes. Three days later, the patient was discharged without any events. The mechanism of ST segment depression triggered by high-grade fever is less understood. It is hypothesized that during high-grade fever, myocardial oxygen demand is elevated due to hyperthermia and tachycardic events. This mechanism may result in transient ischemia shown by the ST segment changes.

Conclusion : We documented a patient with transient diffuse ST segment depression during the high-grade fever phase. The electrocardiography resolved after her temperature returned to normal. It is crucial to be cautious in interpreting ST segment changes in patients with high-grade fever, especially without clinical signs and symptoms of acute coronary syndrome. Serial electrocardiography and cardiac biomarker tests can aid in accurate diagnosis and management.

Keywords: Transient ST segment depression, High-grade fever, Diffuse ST segment depression, Hyperpyrexia



When a Rare Pathogen Strikes: *Abiotrophia defectiva* and Infective Endocarditis with Septic Embolism

Effendi¹, I.P. Farissa¹, F. Tandri¹, M.F. Ahnaf¹

¹Department of Cardiology and Vascular Medicine, Faculty of Medicine Diponegoro University, Dr. Kariadi Central General Hospital Semarang, Indonesia

Background

Most cases of Infective endocarditis (IE) are caused by *Streptococci viridans* or *Staphylococci* species. *Abiotrophia defectiva* is a rare species which can lead to infective endocarditis. Here we discuss a fatal case of IE due to *Abiotrophia defectiva*.

Case Illustration

A 37-year-old man admitted to Emergency Department because of dyspnea accompanied with prolonged fever for 3 months with a history of untreated recurrent toothache. From physical examination, there was grade 3/6 holosystolic murmur, high pitched punctum maximum at apex radiating to axilla. Cardiomegaly with congestive pulmonum was noted by chest x-ray. Echocardiography revealed normal Left Ventricle function with vegetation at mitral valve leaflets and severe mitral regurgitation. He was diagnosed as possible IE at presentation. Three sets of blood cultures were taken before the patient was commenced on antibiotic with ampicillin-sulbactam and gentamycin. There was no improvement for 7 days of treatment. Blood culture later revealed *Abiotrophia defectiva* which resistant to ampicillin-sulbactam, we decided to replace it with Ceftriaxone. On 11th day, patient developed severe kidney injury (Creatine 4,9 mg/dL) and sepsis (Procalcitonin 6,87 ng/ml) which were thought as a septic embolism to kidney. A combination of Meropenem and ceftriaxone then administrated but septic shock and respiratory distress syndrome caused the patient death.

Conclusion

The report underscores the potentially life-threatening nature of IE. It highlights the challenges of diagnosing and treating rare pathogens like *Abiotrophia defectiva* and also complications of patients with IE. The report underscores the critical role of prompt and aggressive management. Overall, this case report highlights the need for increased awareness and vigilance to infective endocarditis, particularly when rare pathogens are involved. While the outcome in this case was tragic, it provides important lessons for healthcare professionals in diagnosis, treatment, and management of infectious diseases.

Keywords: Infective endocarditis, septic, rare pathogen



THE IMPORTANCE OF IMMEDIATE REPERFUSION ON STEMI WITH CONDUCTION DISORDER: CASE OF SUCCESSFUL FIBRINOLYTIC ON ANTERIOR STEMI WITH BIFASCICULAR BLOCK

A. Almira¹, Hendrianus², Y. Natanael³

Brawijaya Women and Children Hospital Antasari¹

Cardiology and Vascular Medicine Resident, Faculty of Medicine Universitas Indonesia, National

Cardiovascular Center Harapan Kita²

Ruteng Public Hospital³

Background : Acute myocardial infarction is one of the major leading death worldwide. ST-elevation myocardial infarct (STEMI) is frequently associated with the development of a new bundle branch block or hemiblock result in high mortality rate due to the extensive myocardial necrosis. This case is presented to highlight a case of STEMI with bifascicular block (RBBB and LAFB) and its management in rural area.

Case Illustration: A 70 years-old male was referred to rural hospital from primary health centre with typical chest pain 7 hours before admission. At arrival, the patient exhibited mild chest pain with stable vital sign. The electrocardiogram showed sinus rhythm with anterior myocardial infarct followed by RBBB and LAFB, so DAPT and nitrate were given. Before fibrinolytic was administrated, the patient chest pain aggravated and became highly agitated accompanied by sign of shock. Fibrinolytic was administered along with benzodiazepine to sedate the patient. Fibrinolytic therapy was successful as marked by significantly decreased chest pain and agitation. ECG evaluation showed persistent ST elevation in anterior leads. Echocardiography showed decreased left ventricular ejection fraction (EF 20%) and LV aneurysm. After 5 days in the ICU, his clinical condition improved and the patient was discharged in a stable condition. Bifascicular block (RBBB with LAFB or LPFB) is often associated with a poor prognosis and the presence of acute heart failure. Fibrinolytic therapy is crucial in settings where primary PCI cannot be offered in a timely manner, as in rural area.

Conclusion: In rural area, immediate reperfusion with fibrinolytic significantly improved the outcome of patients with STEMI complicated by bifascicular block.

Keywords: Bifascicular block, fibrinolytic, STEMI, rural area

Recurrent Seizures and Arrhythmia : Clinical Entity or Coincidence?

R.K. Utami¹, A. Rakhmawati¹, M.D. Sutadi¹
RSUD Dr Tjitrowardojo Purworejo¹

Background : Cardiac arrhythmia is frequently associated with epileptiform seizure. It has been considered as a potential cause of sudden unexpected death in epilepsy. We report a case of a patient with recurrent seizures with high degree atrioventricular block and documented ventricular standstill during seizure which required a cardiac pacemaker.

Case illustration : A 49-year-old woman with a medical history of epilepsy was admitted to the emergency room due to recurrent seizures. She had experienced several episodes of seizure since a week before admission with normal level of consciousness gained between the episodes. The medical history of arrhythmia was unknown. Physical examination showed stable hemodynamics with no remarkable neurologic deficit. Laboratory studies showed elevated white blood cells count and normal metabolic panels. The 12-lead ECG exhibited high degree atrioventricular block. The EEG showed generalized intermittent slowing wave with no epileptiform activity. During hospitalized, she had generalized seizure followed by cardiac arrest with ventricular standstill mode in the monitor. Surface ECG monitoring was high degree atrioventricular block with ventricular standstill (Figure 1). She got return of spontaneous circulation and regained consciousness after the episodes of seizure. The patient was treated with dopamine infusion and referred to higher-level hospital for pacemaker implantation.

Conclusion: Recurrent seizures in this patient was most likely caused by atrioventricular node dysfunction, not epilepsy since the EEG showed no epileptiform activity. She needed pacemaker implantation mandatory.

Keywords: seizure, arrhythmia, epilepsy, high degree av block

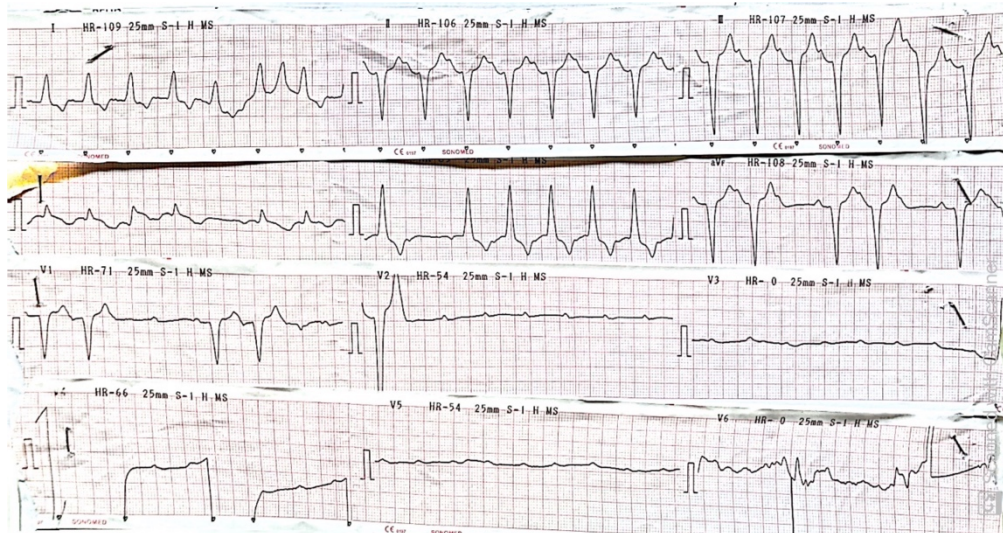



Figure 1 ECG showed high degree atrioventricular block with ventricular standstill



The management of antiplatelet therapy in acute coronary syndrome patients with thrombocytopenia: A Case Report

W. Bahagia¹

Bhayangkara Palangka Raya Hospital¹

Background: Acute myocardial infarction (AMI) is myocardial necrosis resulting from acute obstruction of a coronary artery. Dual antiplatelet therapy (DAPT) consisting of aspirin and a P2Y₁₂ receptor antagonist is a fundamental component of acute coronary syndrome (ACS) management. The management of antiplatelet therapy in ACS patients with thrombocytopenia poses a particular challenge for physicians, as they are at higher risk of both bleeding and, paradoxically, ischaemic events

Case Illustration: A 49-year old man came to emergency with a history of hypertension and presented chest pain followed by worsening shortness of breath, nausea, and vomiting 12 hours before admission. Physical examination's patient was conscious, blood pressure 140/90, a respiration rate of 32 times/minute, and a heart rate 138 times/minute irregular. The electrocardiogram showed irregular narrow QRS complex tachycardia and p wave was absent. Laboratory CBC revealed hemoglobin 9,7 g/dl and platelet count $88 \times 10^9/L$. Chest radiograph showed either cardio or lung was normal. Echocardiography showed all chamber dilation, decrease left ventricular systolic function (ejection fraction 46%), segmental hypokinetic, mild mitral regurgitation, and moderate tricuspid regurgitation. Given the patient's stable hemodynamic, nitroglycerin intravenous drip became started. Aspilet, Clopidogrel, Digoxin, Bisoprolol, Furosemide, Spironolactone, and Atorvastatin were initiated. After six days of adequate treatment, the symptoms resolved and the patient was discharged from hospital.

Conclusion:

The presence of thrombocytopenia in ACS patients predicts significantly worse outcomes. It has been suggested that thrombocytopenia in ACS may reflect a greater burden of atherosclerosis predisposing to heightened platelet consumption, or reflect clinically significant thrombosis, and consequently, its presence should be viewed as a marker of disease severity. DAPT could use in ACS patients by considering the platelet count baseline, state of bleeding, and percutaneous coronary intervention (PCI) planning.

Keywords: AMI, NSTEMI-ACS, Trombocytopenia, Tachyarrhythmia

The Dilemma of an Action : Cardiac Tamponade in Severe Pulmonary Hypertension. Should We Drain?

W. Mubarok¹, R.P. Harjoko², Jefry¹

Faculty of Medicine, Diponegoro University, Semarang, Indonesia¹

Departement Cardiology and Vascular Medicine, Dr. Kariadi General Hospital Semarang, Indonesia²

Background

Development cardiac tamponade from pericardial effusion is a life-threatening condition requiring prompt diagnostic and therapeutic. In PH, pericardial effusion is related to higher risk stratification class and an independent mortality risk factor.

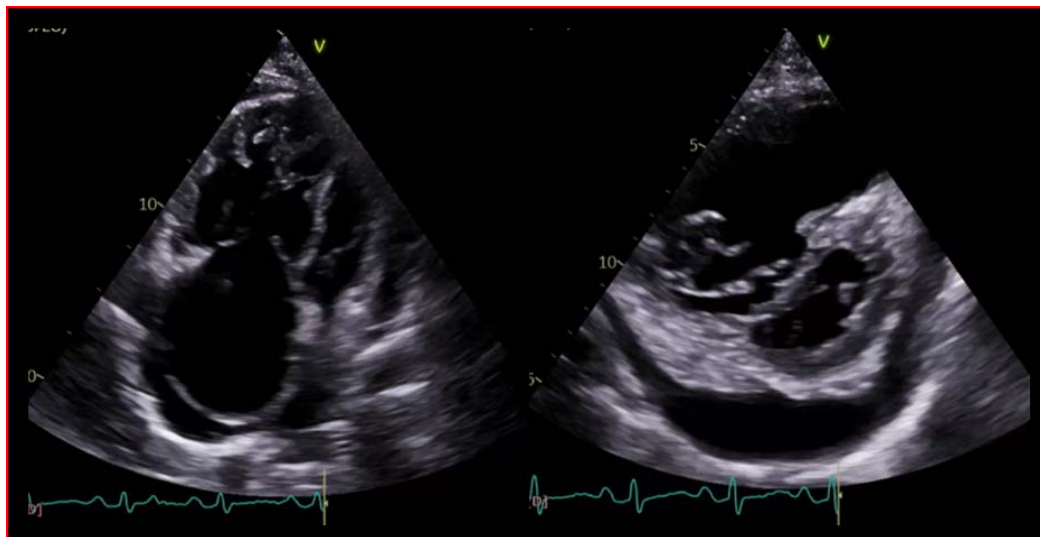Case Illustration

28-year old obese women present with dyspnea, ascites and edema in lower extremity. The complain since 1 years ago. Heart rate was 100 bpm with BP 110/70 mmHg, RR 26 per minutes, SpO₂ 96%. The ECG was sinus rhythm, RAD and RVH. The laboratorium showed hypoalbuminemia, hypokalemia and coagulopathy. Patient already done RHC, there are severe PH with mPAP 70 mmHg with no ASD. In echocardiography, we found dilated RA RV and MPA with LV smallish, decrease RV function, circumferential pericardial effusion with no sign of cardiac tamponade, TR severe and high probability for PH. Patient got pericardial window and got 500cc over 24 hour. The drain was gradual with improvement in LA filling. So, the presence of RV failure may significantly alter typical diagnostic findings. Abnormally high intracavitary pressures make RA and RV much more resistant to collapse. Because of ventricular interdependence, right ventricular dilation causes a disproportionate decrease in the size of the left ventricle, which worsens diastolic filling and stroke volume. Rapid drainage has high periprocedural mortality due to RV decompensation. Gradual drainage, as in our patient, may be safer resulting improvement.

Conclusion

The recognition of cardiac tamponade in the presence of severe pulmonary hypertension and RV failure can be even more challenging, because the “classic” findings are often not observed. Deeper understanding in pathophysiology and mechanism would help the patient workup.

Keywords: cardiac tamponade, pericardial effusion, pulmonary hypertension



REVASCULARIZATION IN CARDIAC ARREST SURVIVOR: A TRANSIENT ST-ELEVATION MYOCARDIAL INFARCTION POSTEROLATERAL CASE

L.B.A. Praha¹, M.F. Ahnaf¹

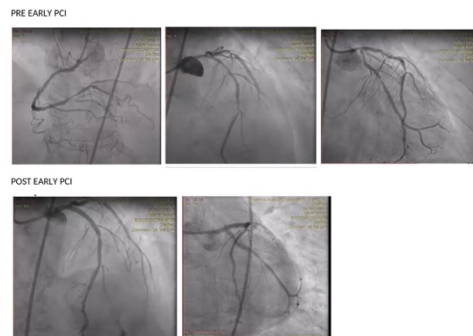
Cardiovascular Department, Medical Faculty of Diponegoro University, RSUP Dr. Kariadi

Background: AMI is a frequent cause of cardiac arrests due to VF or pulseless VT. The ESC clearly state in the case of cardiac arrest and ST-segment elevation after ROSC, immediate CAG and revascularization should be performed in order to reduce mortality and improve patient outcomes.

Case Illustration: A 67 years old woman was referred from Magelang hospital complaining of chest pain. Her CAD risk factor was menopause. After an hour, suddenly pulseless VT and cardiac arrest happened, continue CPR and defibrillation 3 times. Presenting on Kariadi, BP 118/75, pulse 84 bpm regular, RR 20, SpO₂ 98% NC 3 lpm. There were normal cardiac and pulmonary examinations, ECG in Magelang showed ST elevation in lead I, aVL, ST depression in lead III, V1-V4, and occasional VES, then ECG in Kariadi hospital showed qR lead aVL, V7,8,9 and run of PVC. Chest X Ray revealed Cardiomegaly (LV) and bronchovascular pattern increased. The laboratory test showed leukocytosis (17.4 u/L), elevated transaminase enzyme (OT 526, PT 325 U/L) and troponin level >25 ug/L, and metabolic acidosis fully compensated. She was scheduled to early PCI, found CAD3VD+LM Disease and done 1 DES distal LM - proximal LAD, 1 DES mid- distal LAD, 1 DES ostial proximal LCx, and then stabilized in CVCU for further evaluation.

Conclusion: Transient STEMI seems to be unique condition. According to ESC guidelines an early invasive approach with a view to revascularization within 24 h of presentation is mandatory. The term “time is muscle” is a basic principle in diagnosis and optimal management of AMI to improve patient outcomes.

Keywords: Revascularization, Cardiac Arrest Survivor, Posterolateral STEMI



The early percutaneous coronary intervention had done

Asymptomatic Obstruction of Bioprosthetic Mitral Valve due to Pannus Formation

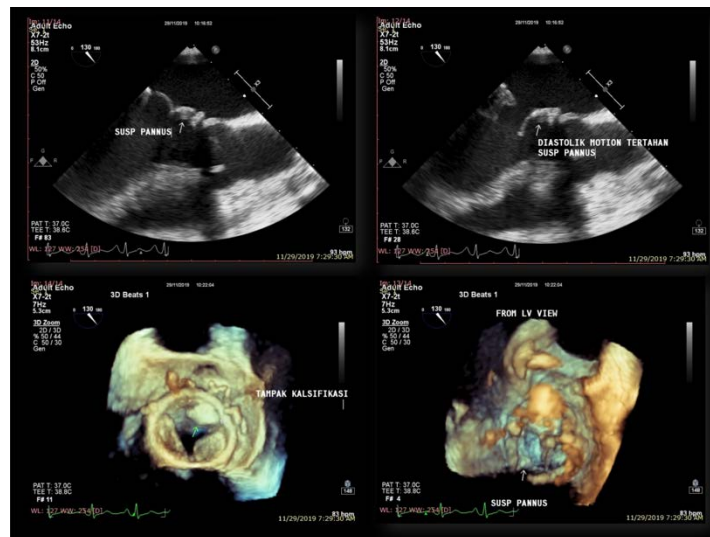
N.M.A.W. Sari¹, K.S. Bhuana¹
Universitas Udayana / RSUP IGNG Prof Ngoerah¹

Background : Pannus is an abnormal fibrovascular tissue, located in the circumference of the bioprosthetic heart valve. The true incidence of pannus is unknown, and thought to be related to incidence of valve thrombosis at 0.1 to 6% per year. Diagnosis of pannus require imaging such as echocardiography. Transthoracic echocardiography provided initial evaluation on transvalvular gradient, and determine the presence of obstruction. Transoesophageal echocardiography provided visualization of the mass and mobility of the leaflet. Management of pannus depend on the severity of the obstruction.

Case Illustration : We present a case of a 29-year-old female for routine yearly evaluation after she was performed a mitral valve replacement with BHV around 8 years prior, due to rheumatic severe mitral stenosis. On evaluation, she did not have heart failure symptoms and only took furosemide when necessary. Physical examination revealed low-grade diastolic murmur at 2nd right intercostal space with vesicular breath sound. Transthoracic echo showed moderate Aortic Regurgitation (AR), suspected pannus on the circumference of the mitral BHV, with mean transvalvular pressure gradient of 9 mmHg at heart rate (HR) of 69 bpm. Transesophageal echocardiography revealed a restricted motion during diastolic phase on one of the mitral BHV leaflet due to a suspected pannus structure, a moderate calcification on one of the leaflets, and trivial mitral regurgitation. We observed a change of mitral BHV mean transvalvular pressure gradient during procedure into 15mmHg with a HR of 84 bpm, with no change in symptom. The patient was managed conservatively with transthoracic echocardiography reevaluation every 6 months.

Conclusion : Pannus formation after mitral bioprosthetic heart valve (BHV) implantation is a rare finding with unclear pathomechanism. An asymptomatic obstruction of the bioprosthetic mitral valve usually require routine symptoms observation and echocardiographic reevaluation. This report hopes to provide an echocardiographic evaluation of BHV mitral valve pannus.

Keywords: Transthoracic Echocardiography, Mitral Vave Bioprosthetic, Pannus, Transesophageal Echocardiography, Asymptomatic obstruction.



Top : 2D TEE image at mid-esophageal long axis, showing a mass suspected pannus. Bottom : 3D TEE reconstruction from LV and LA View.

A rare case of intracardiac thymic carcinoma presenting as Superior Vena Cava syndrome

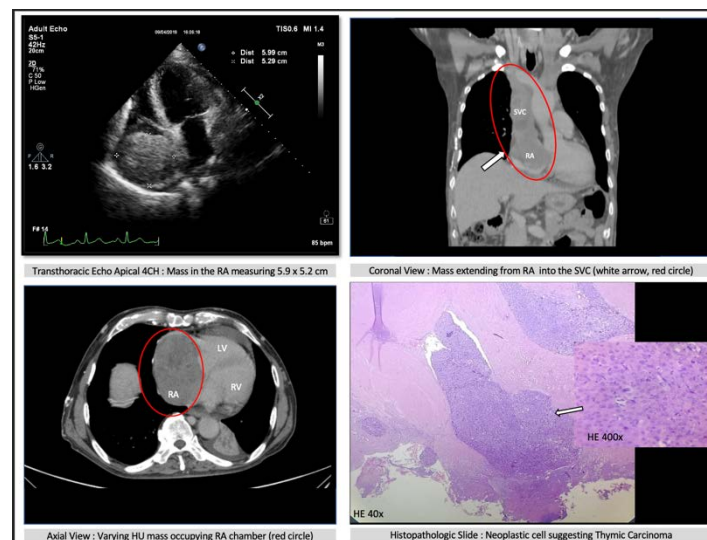
I.N. Wiryawan¹, K.S. Bhuana R¹
Universitas Udayana / RSUP IGNG Prof Ngoerah¹

Background : Thymic carcinoma is a rare neoplasm that arise in the anterior mediastinum. Thymic carcinoma has an incidence of 0.2 to 1.5% of all malignancies. Thymic carcinoma has varying clinical presentations, from asymptomatic findings to severe tumor mass effect. An intracardiac infiltration of thymoma occur in 4% of all cases. Diagnosis is made from clinical presentation, imaging and histopathologic assessment. Advanced stage of thymic carcinoma carries a worse prognosis.

Case Illustration : We present a case of intracardiac thymic carcinoma in a 64-year-old male patient with chief complaint of intermitten swelling of the face with neck lymph node enlargement. Initial chest MRI showed moderate signal intensity on the SVC. He was initially diagnosed as antiphospholipid syndrome due to positive ANA IF. Around 2 years after diagnosis, patient developed severe congestion of the face and neck, and upper extremities. Echocardiography evaluation showed a 5.9 x 5.2 cm mass inside the right atrium. Chest CT Scan showed a Mass from right atrium, extending into the SVC causing type IV SVC obstruction. CT scan also showed varying HU around the mass suggesting a thrombus adjacent to the mass. Patient was planned for sternotomy and tumor evacuation. Intraoperative evaluation showed a mediastinal mass with extensive localized and intracardiac spread. Patient was only performed incisional biopsy with samples taken from both the anterior mediastinum mass and inside the right atrial mass. Histopathological diagnosis of Thymic Carcinoma was made. Patient passed away due to lung infection, before receiving definitive treatment.

Conclusion : Intracardiac thymic carcinoma is a rare case and often overlooked. Infiltration into the cardiac chamber represent a more advanced disease, such as presented above. This report hopes to provide a comprehensive insight on imaging of intracardiac masses.

Keywords: Thymic Carcinoma, Right Atrial Mass, Superior Vena Cava Syndrome, Anterior mediastinal mass, Intracardiac masses.



Management of NSTEMI Patient with Acute kidney Dysfunction due to Septic Shock at Hasna Medika Cirebon Hospital

M.A. Rezza¹, A. Deri², H.I. Gugun³
Hasna Medika Hospital
Cirebon, Jawa Barat, Indonesia

Background: The presence of kidney dysfunction in ACS has been associated with worse outcomes, including higher rates mortality and bleeding. Prevalence rates of 42.9% among patients NSTEMI with presenting chronic kidney disease. Management of patients with severe kidney impairment with ACS more complex, consideration of increasing bleeding risk with worsening renal function.

Case Illustration: A 46- year-old male present to the hospital with chest discomfort, short of breath, and fatigue, fever and a new cough. Symptoms began approximately 2 weeks before and had progressively worsened with no associated, aggravating, or relieving factors noted. His physical examination showed BP 82/55 mmHg. No JVD present, bilateral rhonchi noted, cold extremities, and physical exam is otherwise normal. The laboratorial presented leukocytosis (19850/mL), troponin T (144 ng/l), aPTT (22.5/s) and a significant elevated urea (289.0 mg/dl) and creatinine blood level (12.01 mg/dl), compared to the historical of last 4-month laboratory result which was urea (31 mg/dl) and creatinine (0.6 mg/dl). ECG showed T wave inversion lead V1-V3, a chest x-ray showed pneumonia and cardiomegaly, and we also performed hemodynamic echocardiography showed ERAP15, SV:35, CO:2.3, SVR:2365 (on norepinephrine support). Due to acute kidney dysfunction we decided to do conservative management. Rehydration treatment with intravenous infusion of lactated ringer's solution, and followed by intravenous of norepinephrine dose. Loading dose of DAPT, then maintenance dose for the next day, atorvastatin once daily. Bolus dose of intravenous heparin followed by maintenance dose of heparin per hour. The follow up on the day 4th of medication, laboratory evaluation down to 194.9 mg/dl of urea level and 2.0 mg/dl of creatinine level. The laboratory evaluation at the polyclinic visits after a week of discharged, down to 24.6 mg/dl of urea level and 0.77 mg/dl of creatinine level.


Case Discussion: We describe a case NSTEMI with severe hypoperfusion caused by septic shock induced to kidney parenchymal injury followed by significant decrease of glomerular filtration rate and led to acute kidney dysfunction. In this NSTEMI patient with GFR 5.98 ml/min, we decided conservative therapeutic with unfractionated heparin (UFH) used, DAPT dose and rehydration and norepinephrine support to increase perfusion due to septic shock. We delayed invasive coronary angiography and percutaneous coronary intervention because of concerns about acute kidney injury accelerating their progression to dialysis.

Conclusion: UFH remains the default option for anticoagulant NSTEMI patients with kidney impairment can safely and effectively used, despite the complexity of its use and its known toxicity profile.

Keywords: acute kidney dysfunction, NSTEMI, septic shock

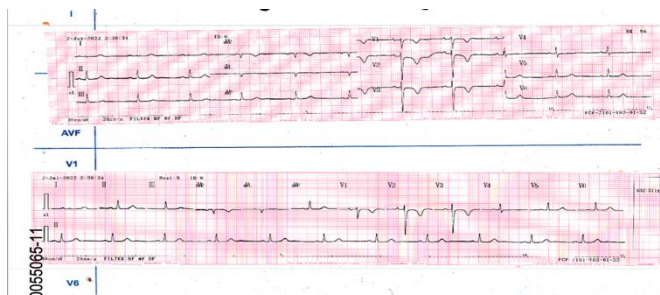

Fig. 1 Inverted T wave ECG showing sinus rhythm, T wave inversion in lead V1-V3



Successful Balloon Mitral Valvuloplasty in 32-week Pregnant Patient with Severe Mitral Stenosis: A Case Report

J.P. Sianipar, W.N. Yuandika, M.F. Ahnaf

Department of Cardiology and Vascular Medicine, Faculty of Medicine, Diponegoro University – Dr. Kariadi General Hospital, Semarang

Background

Mitral stenosis (MS) in pregnancy is still one of the most common causes of maternal death. MS is one of the most commonly encountered valvular heart diseases during pregnancy, the majority are rheumatic in origin and poorly tolerated due to cardiocirculatory changes that occur during pregnancy, labor and postpartum. Severe MS is usually poorly tolerated in pregnancy, with 67% of women developing peripartum heart failure even if previously asymptomatic.

Case illustration

A 33 years old woman, G3P1A1 31 weeks pregnant came to Dr. Kariadi Hospital with a shortness of breath during daily activity, which was worsened since 26 weeks of pregnancy. The complaint was accompanied by swelling on both legs. She felt more comfortable to sleep with half-sitting position. Chest pain was denied. Physical examinations demonstrated the BMI was 45 kg/m², diminished S1 and normal S2 sound, irregularly irregular, mid diastolic murmur 2/4 on apex. Echocardiography revealed Severe MS with MVA by planimetry 1.05 cm², by VTI 0.9 cm², by PHT 0.9 cm², mean PG 18 mmHg, Wilkins score 5, moderate tricuspid regurgitation with high probability for pulmonary hypertension. The patient was stabilized with continuous drip furosemide, digoxin, and warfarin. BMV had been done in 32 weeks of pregnancy and managed to reduce the mitral pressure gradient from 17.7 mmHg to 8.6 mmHg with mPAP decrease from 75 mmHg to 62 mmHg. During the procedure patient was under general anesthesia and extubated in recovery room after procedure. Then she was moved to ICU for monitoring in a day, then moved to ward.

Conclusion

Balloon mitral valvuloplasty in pregnancy is a relatively safe and effective interventional cardiac procedure, helps the patients with moderate to severe MS which gives optimum results.

Keywords: pregnancy, mitral stenosis, balloon mitral valvuloplasty

A 69 years old man with in stent thrombosis after PCI leading to Free Wall Rupture and Massive Pericardial Effusion: a Complex Disastrous Event after PCI

Y. Suryadilaga, M.F. Ahnaf, S. Sungkar¹

¹ Department of Cardiology and Vascular Medicine, Medical Faculty Diponegoro University, Kariadi General Hospital, Semarang, Indonesia

Backgrounds

Left ventricular free wall rupture is a rare but severe complication of acute myocardial infarction. It was reported to occur either early after the onset of MI (type I or II, approximately 55%) or during the sub-acute phase accompanied with overt cardiac remodelling (type III, 45%). Factors including old age, female gender, and large infarct size were found to be associated with the risk of free wall rupture. Due to the variable clinical presentations associated with high mortality, it remains a substantial diagnostic and therapeutic challenge for clinicians.

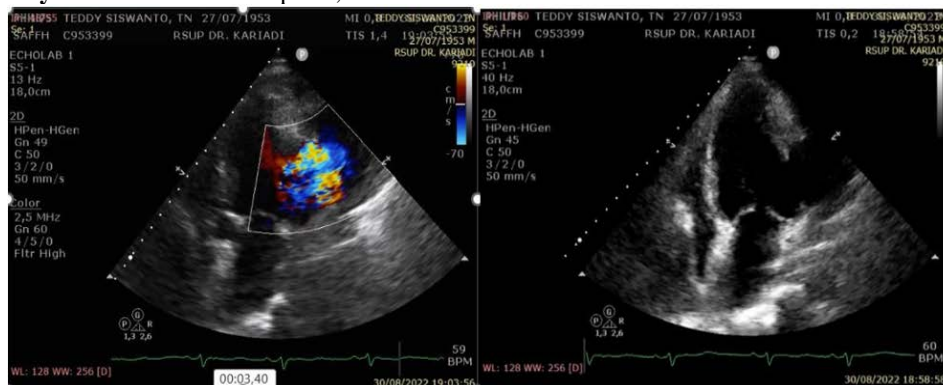
Case Illustration


A 69 years old man was referred with dyspneu and chest. A month ago, he experienced substernal heavy chest pain with diaphoresis. He got treatment and diagnosed posterior STEMI, underwent primary PCI, and a stent was placed in ostial-distal Left Circumflex artery. 3 weeks after, he developed dyspneu and chest discomfort, re-angiography showed in stent thrombosis with LV aneurysm. Echo revealed massive pericardial effusion with free wall rupture. In our ER, he was panting, Blood Pressure was 125/74 (94) HR 94 bpm RR 24 times/minute SpO₂ 98%, there were no rales, elevated JVP and pitting edema on both ankles. Bedside Echo showed massive localized pericardial effusion without tamponade, LV aneurysm and suspected of free wall rupture. Later he was admitted to ICCU and underwent cardiac surgery.

Conclusion

Acute myocardial infarction can cause ischemic, mechanical, arrhythmic, embolic, or inflammatory complications. The development of mechanical complications after AMI is associated with significant short-term clinical improvement and long-term survival. Though the incidence of this fatal complication has seen a considerable decline due to primary percutaneous coronary angiography, our observations point to a more prolonged symptom to angiography time as one of the important predictors that leading causes of this complication.

Keywords: Free Wall Rupture, STEMI





Neurological Complication After Cardiac Surgery: A Case Report

Y. Suryadilaga, S. Sungkar¹

¹*Department of Cardiology and Vascular Medicine, Medical Faculty Diponegoro University, Kariadi General Hospital, Semarang, Indonesia*

Backgrounds

Postoperative stroke in cardiac surgery continues to be a major factor that increases morbidity, mortality, and readmission risk, with contemporary reports of a ninefold increase in postoperative death of stroke patients. As cardiac surgical outcomes have improved over the past decades, the demographic of patients being referred for surgery has shifted in favor of patients who are of greater age with more comorbidities that may put them at higher risk for postoperative stroke. The incidence of stroke after cardiac surgery is dependent on the procedure itself and the reporting center, but typically ranges from 0.8% to 5.2%.


Case Illustration

A 58 years old man felt shortness of breath while taking light activities then underwent mitral valvular replacement. There is no history of atrial fibrillation and neurological sign before cardiac surgery. Vital sign after surgery, blood pressure 106/70 MAP 79 on support dobutamine 10 mcg/kgweight/minutes/ and norepinephrine 0.2mcg/kgweight/minutes, HR 120-130x/minutes irregular, RR 26x/minutes and SpO₂ 100% on VM Mode SCMV PEEP 5 FiO₂ 40%, patient showed atrial fibrillation. Sixth day after cardiac surgery patient got seizure tonic clonic with treatment fenitoin injection. Then head MSCT found cytotoxic cerebral edema, showed increased pressure intracranial, and sphenoiditis dextra et sinistra. Patient moved to stroke care unit after got stabilized from ICU ward.

Conclusion

Patients undergoing cardiac surgery should receive frequent postoperative neurologic checks so that an intervention can be made as quickly as possible when a large stroke occurs. Current interventions can minimize stroke risk, treat perioperative stroke, and manage perioperative hypoxic-ischemic injury. The goals of therapy are to improve oxygenation, maintain an adequate blood pressure for perfusion of vital organs and coagulation status. The underlying cause must be addressed.

Keywords: Cardiac surgery, Stroke, Postoperative



Cardiac Amyloidosis Presented with SND: A Case Report

S.A. Alawiyah¹, I. Fahri¹, S. Hastuti¹, J. Endang¹
RSUD DR. M YUNUS BENGKULU¹

Background: Cardiac Amyloidosis is a restrictive cardiomyopathy characterized by the extracellular deposition of mis-folded proteins in the heart. It is usually diagnosed late since symptoms are nonspecific and are often disregarded with other conditions.

Case Illustration: A 54 years old man presented to emergency department with sudden onset of syncope. He had medical history of heart failure with preserved ejection fraction and normal coronary artery by coronary angiography. On initial physical examination, His blood pressure was 87/62 mmHg with heart rate of 50 bpm. He also had ecchymosis in eyes and had facial droop and difficulty to closing eyes and smiling. He had clear lungs and normal heart sounds without murmurs or gallops. He had mild pitting edema bilaterally. ECG showed 1st degree AV block with episode of junctional rhythm and low voltages in the limb and pre cordial leads. His blood pressure and HR was supported with dopamine and hemodynamics was stable, but unable to weaned the inotropic due to hypotension and ECG showed AF SVR. We decided to implant PPM to this patient. Based on the findings above, a diagnosis of amyloidosis complicated with SND was considered and supported by echocardiography illustrating severe concentric ventricular hypertrophy and longitudinal strain reduction with relative apical sparing showing 'cherry on top' or bull's eye appearance with EF was at 32% by Simpson's. He remained asymptomatic after pacing and was discharged three days later. A subsequent follow-up of his amyloid involvement by other explorations is planned for this patient.

Conclusion: Cardiac amyloidosis remains a rare disease. In rural area with limited diagnostic testing must identify more from clinical and physical significance. Cardiologist should be aware of cardiac amyloidosis to allow early treatment that can change the prognosis of this disease

Keywords: Cardiac Amyloidosis, Syncope, SND

Lower Limb Skin Pigmentation as Sequelae of Untreated Chronic Venous Insufficiency

C. Adriana¹, N. Anggriyani¹

Faculty of Medicine, Diponegoro University, Semarang, Indonesia¹

Background

Chronic venous insufficiency (CVI) of the lower limb has great effect on quality of life. Untreated CVI results in variety of complications, the major ones being persistent pain and progressive skin changes ranging from small erythema to extensive areas of severe skin pigmentation that may ultimately lead to ulceration. The progressive unpleasant symptom itchiness that interfere daily activities is the prime cause for seeking treatment. Endovenous laser therapy (EVLT) is a less invasive procedure which is widely used for the treatment of CVI with excellent results.

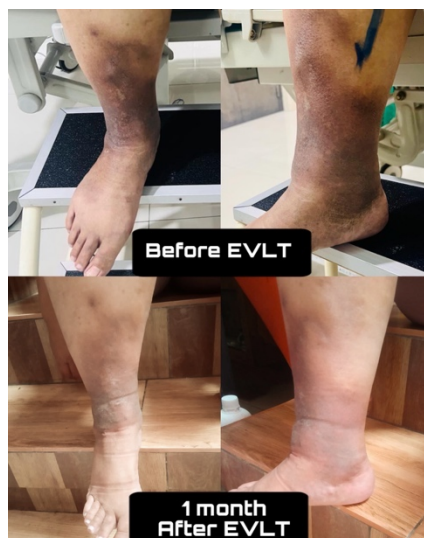Case illustration

A 48-year old woman presented with progressive skin pigmentation and itchy feeling on her right lower limb since 5 years ago. She has been plagued with fatigue leg, cramp, pain and burning sensation for 1 year. These symptoms worsen with prolonged sitting at work as administrative officer for 8 hours per day and obesity. She also had hypertension and dyslipidemia. Physical examination revealed inflammation skin discoloration appear as brown bruises on right tibial region. Lower limb arteries pulsation were equal and normal. Duplex ultrasound revealed severe CVI of right limbs without deep vein thrombosis. After performed EVLT, the patient symptom and skin discoloration improved and able to function at high capacity both at work and with her leisure activities. The extent complication of CVI can be reduced with non-surgical minimally invasive strategy.

Conclusion

Skin hyperpigmentation as a sequelae of underlying CVI required for treatment. EVLT has provided alternative for CVI treatment, effective in reducing the associated symptoms and improved quality of life.

Keywords: chronic venous insufficiency, skin discoloration, skin hyperpigmentation, endovenous laser ablation



ACUTE STEMI IN ANOMALOUS ORIGIN OF THE LEFT CORONARY ARTERY FROM THE RIGHT SINUS CORONARY ARTERY

M. H. Trisnawan¹, A. Alamsyaputra¹, I. Uddin², M.F. Ahnaf²

Faculty of Medicine, Diponegoro University, Semarang, Indonesia¹

Department Cardiology and Vascular Medicine, Dr. Kariadi General Hospital, Semarang, Indonesia²

Background: Anomalous Aortic Origin of Coronary Artery (AAOCA) are rare occurrence with incidence during routine coronary angiography approximately 0.6-1.3%. AAOCA presenting with STEMI are a rare clinical presentation and the management of an anomalous infarct-related coronary artery may be technically challenging.

Case illustration: 60 years old man came to ED with chief complaint severe chest pain accompanied with cold sweating, nausea, and limp while he was cycling. Blood pressure was 121/73 mmHg, HR 64 bpm, RR 21 tpm and there were no presentation of heart failure nor cardiogenic shock. The ECG showed ST elevation in II, III, aVF, and ST depression in lead I and aVL. Laboratory results showed HSTroponin I >40000.0 ng/L. Patient was diagnosed by Acute STEMI inferior 5 hours onset Killip I. Primary PCI was performed via right femoral artery, we had difficulties to access the LCA. Surprisingly, there was an anomaly in the coronary arteries and the patient just told the operator at the table that he had previous single ostium coronary artery anomaly from the CCTA and elective coronary angiography result at the past. So we decided to access the RCA with JR 3.5/6F by aortography technique. The LCA have acute take-off angle, arising from ostial RCA and fortunately have retro-aortic course. Subtotal occlusion thrombus type as the culprit lesion at proximal RCA and we implanted 1 stent DES Firebird II 4.0 x 18 mm at 16 atm. Final result was TIMI flow 3 with residual stenosis 0% without other complications during the implantation.

Conclusion: Cuspogram or aortography technique at the cusps of a target ostium can useful in emergency setting where short time has significant outcome where rapid identification of the culprit's vessel is crucial to achieve successful primary PCI

Keywords: aaoca, acute stemi, primary pci

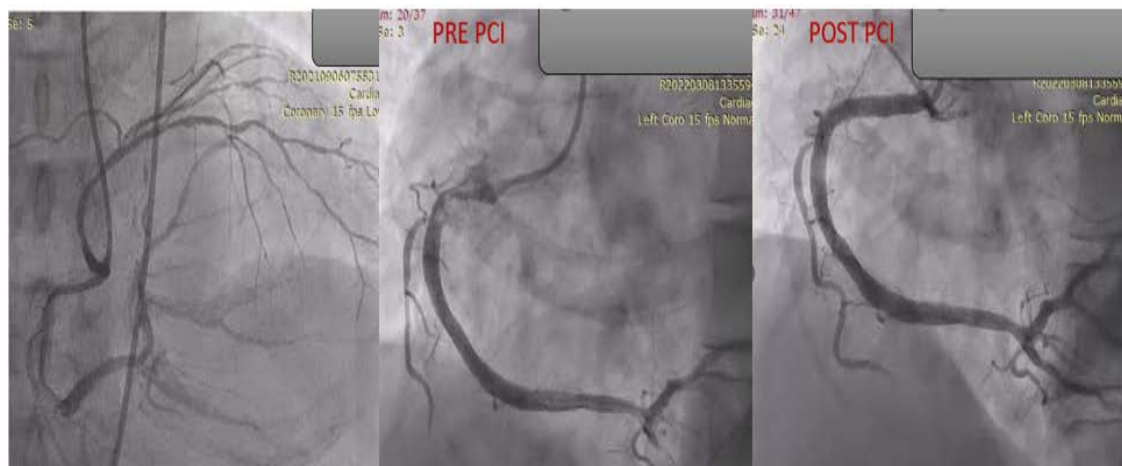


Figure 1. Coronary Angiography

Complete Atrioventricular Septal Defect in Patient with Down Syndrome Morphology: Case Report

I.B.U. Kramasanjaya¹
RSUD Balaraja¹

Background

Congenital Heart Disease (CHD) is the main cause of death in infants with 6.4 incidence per 1.000 birth. Complete Atrioventricular Septal Defect (CAVSD) which correlate much with Down Syndrome (DS) was 4-5.3 case per 10.000 birth. Here, we report a CAVSD patient with DS morphology.

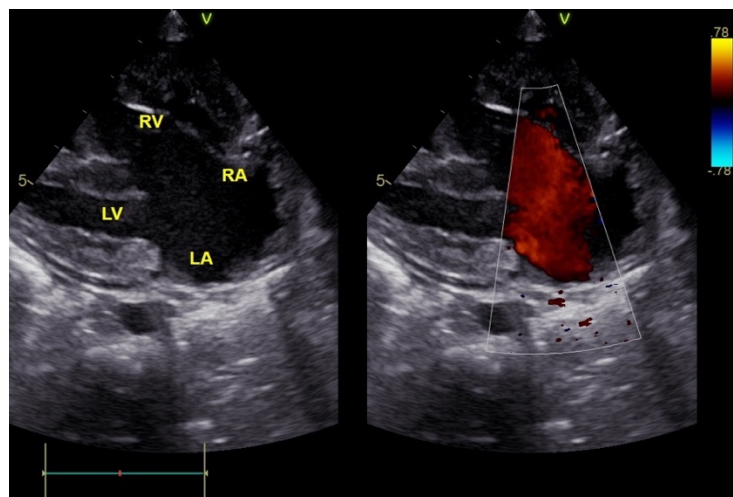
Case Illustration

A 2-year-old girl was admitted to hospital for dyspnea, fever, and cough with history of tuberculosis one year ago and routine control to Public Health Center for malnutrition. She was born premature (32-33 weeks) due to inadequate antenatal care with breastfeeding difficulty after. DS morphology was found. She was severely wasted, underweight, and stunted (5kg, 76cm) with BP 63/41mmHg, HR 140, RR 40, SaO₂ 60-70%, T 38°C. Cyanosis were triggered by crying. We discovered 3/6 systolic ejection murmur at left sternal border and bilateral rhonchi along with increased CRP, leukocytosis, and hypothyroid. Perihilar and paracardial infiltrates were found. Transthoracic Echocardiography showed VSD inlet, ASD primum, and common AV valve. Antibiotics and conservative treatment were given besides Dobutamine and Norepinephrine for shock sepsis. After pneumonia resolved, chromosome test and cardiac surgery were made and investigate later in other paediatric or cardiology center.

Conclusion

CAVSD is a rare CHD and usually symptomatic. Early diagnosis and prompt treatment prevent further fatal prognosis.

Keywords: Complete Atrioventricular Septal Defect, Down Syndrome



Echocardiography

Pulmonary Embolism as an Insidious Manifestation in Post Tuberculosis Obstructive Disease with Pulmonary Hypertension : An Experience from East Nusa Tenggara, Indonesia

M. Tombeng¹, K. A. Nugraha¹
Samuel J. Moeda Navy Hospital¹

Background: Pulmonary embolism (PE) is an acute disease with high mortality, which is prone to be underdiagnosed, especially if it occurs concomitantly with pulmonary disease, such as post tuberculosis obstructive disease (PTOD). PE as a complication of pulmonary TB is rarely reported, but recently, there has been growing evidence supporting this association.

Case Illustration: A 44-year-old man was admitted in our hospital because of worsening shortness of breath and chest discomfort. He had a history of completed and well responded to antitubercular therapy seven years ago. At admission, physical examination revealed normal blood pressure, tachycardia, decreased oxygen saturation 86% at room air, distended jugular vein, and accentuated pulmonary component of S2. No sign of DVT was found. ECG showed McGinn-White sign as S wave in lead I, Q wave, and inverted T wave in lead III. Chest X-ray revealed consolidation associated with collapse on bilateral upper lobe and hampton hump on left lung. Transthoracic echocardiography revealed good LV function, RV dysfunction, mild tricuspid regurgitation with high probability of PH without thrombus visualized. D-dimer level was elevated 0.9 mg/L, meanwhile other laboratory parameters were normal. CTPA revealed hazy appearance suspected as thrombus in left pulmonary artery and atelectasis with cavity lesion in bilateral upper lung that indicates POTD. The patient was given anticoagulant therapy with fondaparinux overlapping with optimal dose of warfarin. After five days of follow up, he showed significant improvement, his vital signs were normal, and could be discharged.

Conclusion: This case report highlights the association between pulmonary embolism and post tuberculosis obstructive disease. This can lead to serious complication, which is potentially preventable by prompt diagnosis and treatment.

Keywords: pulmonary embolism, post tuberculosis obstructive disease, pulmonary hypertension

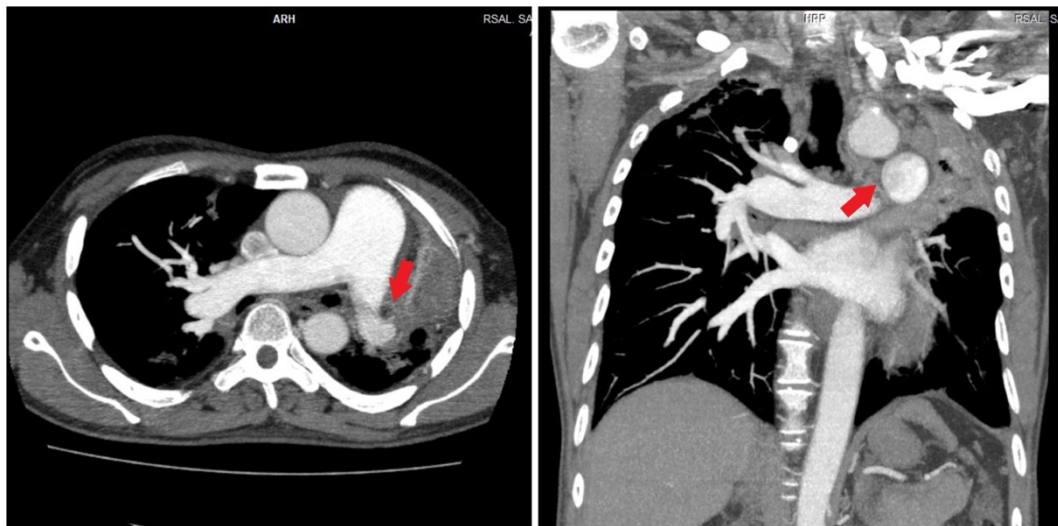


Fig 1. CTPA Axial and Coronal View Show LPA (red arrow) Thrombus

Ventricular Septal Rupture after Extensive Anterior STEMI without Cardiac Surgical Intervention Facility: A Case Report

M.R. Ramadhan¹, D. Jovindho¹
RS Bhayangkara Jambi¹

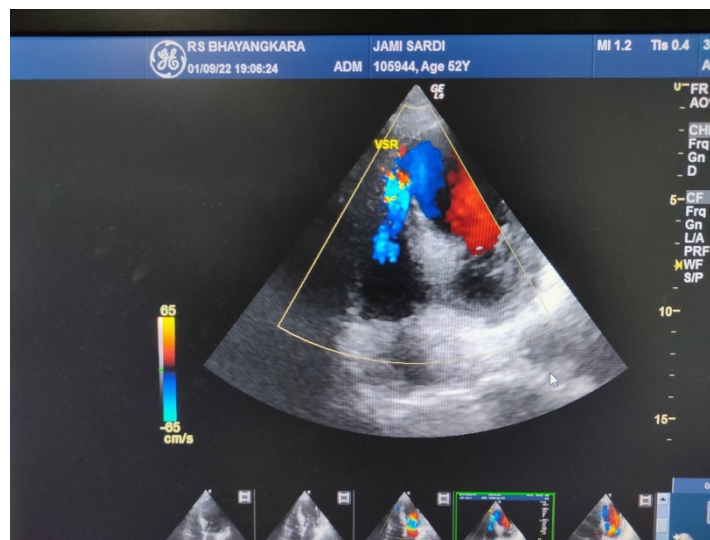
Background: Ventricular Septal Rupture (VSR) is a rare but lethal complication of acute myocardial infarction.¹ The VSR incidence was approximately 2% with significant mortality and morbidity.¹⁻² The management of VSR is stabilize the hemodynamic problems with reducing afterload to increase effective LV stroke volume by reducing left-to-right shunting.³⁻⁴

Case Illustration: A 52-years-old woman with complaint of shortness of breath since a day before admission. A history of epigastric pain radiating to the back accompanied by cold sweating felt two weeks ago. The patient had a history of uncontrolled hypertension. Cardiac auscultation revealed a systolic murmur on intercostal space 3 left-parasternal and rhonchi in medio-basal bilateral of the lung area. ECG showed ST-Elevation at the anterior extensive lead. From Echocardiography examination was found a rupture in intraventricular septal near the apex area with left-to-right shunt (**Figure 1**). From chest X-Ray was found cardiomegaly with increase of bronchovesicular pattern of lung. The patient was diagnosed with Late Onset Anterior-Extensive ST-Elevation Myocardial Infarction (STEMI) accompanied with Acute Lung Oedema complicated by Ventricular Septal Rupture. The patient got conservative therapy during treatment and close monitoring in ICU. One month post-treatment, the patient exhibited a relatively stable hemodynamic with light activity limitation.

Discussion: The management of VSR patient with lack of hospital facility is a challenging case and conservative therapy become an option for focusing of maintaining the stability of hemodynamic. This aims to minimize hemodynamics thereby reducing the work of the heart until the rupture of the intraventricular are fixed.

Conclusion: Due to the high risk of death, every clinician should be aware with potentially fatal complications. The keys to achieve optimal results are early diagnosis and prompt treatment.

Keyword: Ventricular Septal Rupture, Myocardial Infarction, Conservative Therapy.



The echocardiography showed rupture of the apex of septal area with left-to-right shunt flow

SUSTAINED MONOMORPHIC VENTRICULAR TACHYCARDIA (SMVT) CAUSED BY HYPERKALEMIA IN CHRONIC KIDNEY DISEASE (CKD) PATIENT : A CASE REPORT

A. Siswanto¹
RSD Balung Jember¹

Background

Ventricular tachycardia is defined as type of tachyarrhythmia with more than 3 consecutive beats as premature ventricular complex (PVC), rate more than 100 beat per minute, arising from ventricles, unrelated from atrial and atrioventricular nodal conduction. This arrhythmia can be caused by electrolyte imbalance such as hyperkalemia. CKD patients who have decreased renal function is susceptible to this potentially fatal condition.

Case Illustration

A 45-year-old woman was admitted in the ER because of severe dyspnea. There's fluid build up in her stomach and all extremities. She had been diagnosed with cervical cancer stage III since 3 months ago. On physical examination, her skin looked pale and there's coarse crackles in both lung fields. Ascites and edema in all extremities were also found. The ECG showed wide monomorphic QRS complexes, with no p wave thus confirmed Sustained Monomorphic Ventricular Tachycardia (SMVT). Then, the patient was given synchronized cardioversion twice with each dose 100 J and 125 J. The rhythm was converted to sinus rhythm and the symptoms was improved. Chest X-Ray showed cardiomegaly and congestive pulmonum. The laboratory studies showed high serum creatinin level 15.53 mg/dL and severe hyperkalemia 6.71 mmol/L. Then patient was given calcium gluconas and insulin intravenously to decrease serum potassium. If hyperkalemia persisted, the patient was scheduled for emergent dialysis.

Conclusion

One of complications of chronic kidney disease is high level of serum potassium. This electrolyte imbalance may pose clinical fatal consequences such as Ventricular Tachycardia. Therefore, individual screening in CKD patients should be routinely carried out especially for serum electrolytes. Besides that, all CKD patients must receive dialysis treatment right on time to prevent hyperkalemia or other complications.

Keywords: sustained monomorphic ventricular tachycardia, hyperkalemia, chronic kidney disease

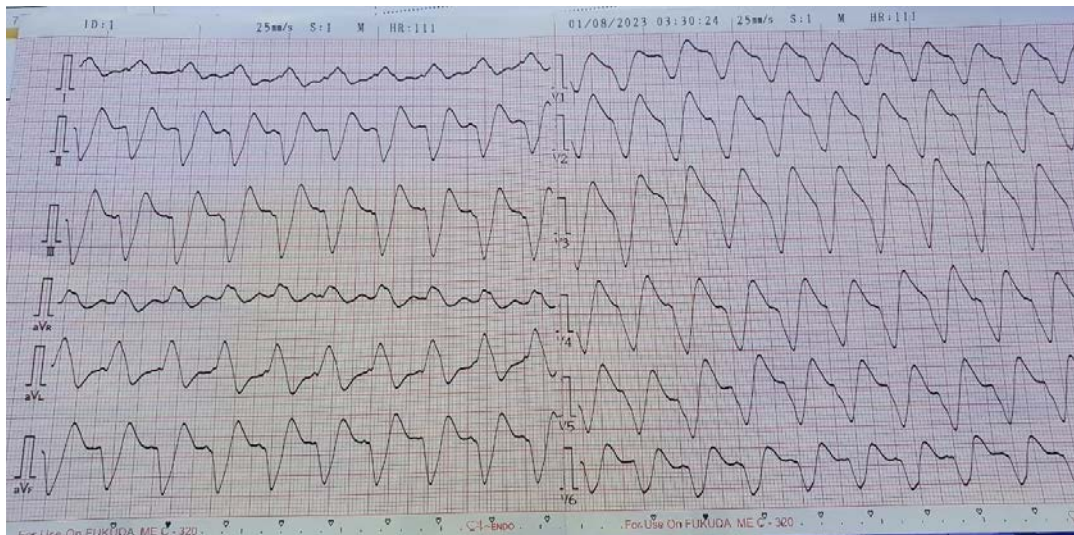


Figure 1. ECG from the patient showed prolonged and uniform QRS complexes, absent of p wave indicating Monomorphic VT

Percutaneous Coronary Intervention of Saphenous Vein Graft in Patients with End Stage Renal Disease - What to Consider?

A. Nurjanah¹, W. Putradana¹, D. Herdianto²

Abdoel Wahab Sjahranie General Hospital, Samarinda, Indonesia¹

Department of Cardiology and Vascular Medicine, Abdoel Wahab Sjahranie General Hospital, Samarinda, Indonesia²

Background

CABG surgery is considered the ideal treatment for multiple coronary stenoses. However, complications such as graft failure or re-stenosis often occur within days to years after surgery. Treatment for patients who develop complications with other comorbidities is quite limited. Thus, caution is needed in determining the therapy.

Case illustration

A 64-year-old man complained of chest pain radiating to the jaw and frequently recurred over the past year. He had a history of CABG surgery seven years ago. On physical examination, all vital signs were normal. A 12-lead ECG examination showed no typical ischemic features. Chest X-ray showed cardiomegaly, and laboratory results showed critical e-GFR values. The patient was referred to the internal medicine department. The internist diagnosed him with end-stage renal disease (ESRD) and advised hemodialysis (HD). Angiography was then performed and showed total occlusion of mid-LAD, diffuse stenosis of LCX, long diffuse stenosis of RCA, total occlusion of osteal LAD graft, and total occlusion of osteal LCX graft, long diffuse stenosis of RCA graft. He was diagnosed with multiple coronary stenoses and grafted with ESRD. The patient was scheduled to undergo PCI. The operator chose to stent the SVG of the RCA using a drug-eluting stent. Then, he was prescribed multiple anti-platelets, nitrates, statins, and b-blockers.

Conclusion

The failure rate of SVG within a decade is quite high. In favourable conditions, revascularization may be possible. PCI is generally preferred, as repeat bypass is considered unlikely due to the high risk of perioperative mortality. PCI using DES is thought to have a better prognosis. In cases of chronic total occlusion in the elderly, especially with low e-GFR values, treatment aims to reduce symptoms and improve quality of life.

Keywords: Saphenous vein graft, Vein graft stenosis, Percutaneous coronary intervention in end-stage Renal Disease, Stenosis vein graft stenting.

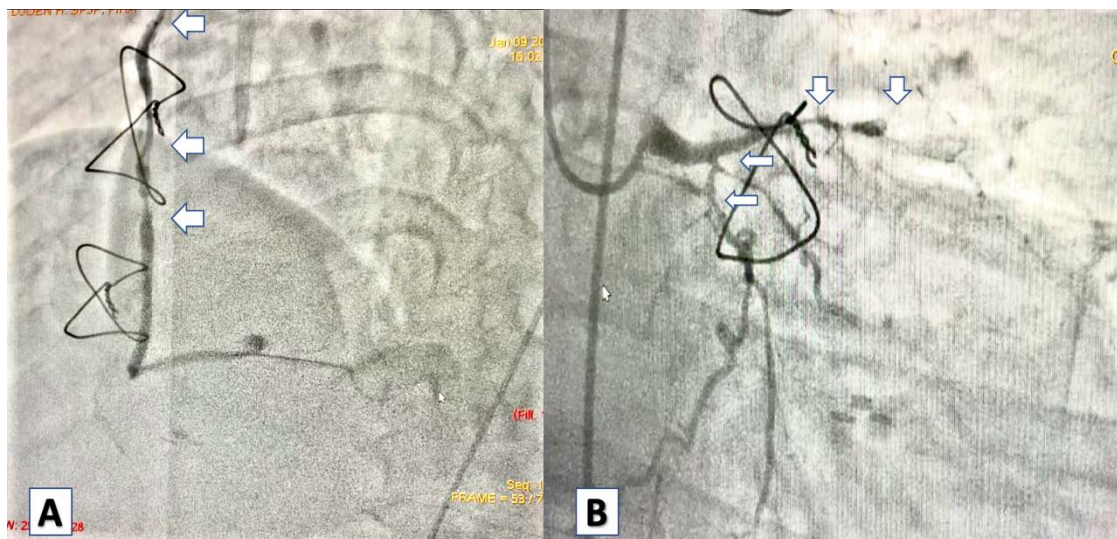


Figure 1. A Diffuse stenosis in RCA graft. B. Total occlusion in mid LAD and diffuse stenosis in LCX.

Stroke During Primary Percutaneous Coronary Intervention

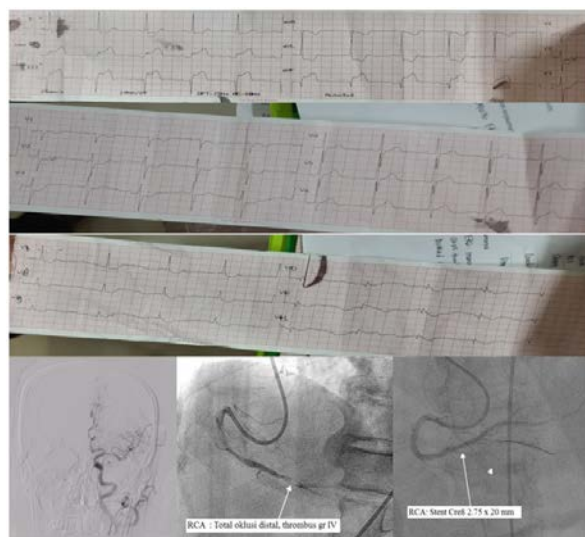G. Soemara¹, C. Kurniawan¹, Subiyanto¹, D.U. Djafar¹, J.A. Pangemanan¹, G. Tangkudung²
Department of Cardiology and Vascular Medicine, Faculty of Medicine, Sam Ratulangi University, Prof. Dr.
R.D. Kandou General Hospital, Manado, Indonesia¹
Department of Neurology, Faculty of Medicine, Sam Ratulangi University, Prof. Dr. R.D. Kandou General
Hospital, Manado, Indonesia²

Background: Stroke is a rare but dangerous complication of Percutaneous Coronary Intervention (PCI). Potential risk factors for periprocedural stroke have been identified, namely advanced age, hypertension, diabetes mellitus, previous stroke history, congestive heart failure, use of an intra-aortic balloon pump, emergency catheterization, renal failure, and presence of coronary artery thrombus. Hereby, we present a case report on stroke during PCI procedure in Manado.

Case Illustration: A 72-year-old male patient visited our emergency department with chief complaint of chest pain for 6 hours. Chest pain was like being crushed by a heavy object radiating to the back and accompanied by cold sweat. He had a history of hypertension for 10 years and did not routinely consume his hypertension drug. The ECG showed ST elevation in leads II, III, aVF, v7, v8, v9 and reciprocal in leads I and aVL. The patient was planned for primary PCI. At the time of procedure, he experienced an acute ischemic stroke with speech defect and right extremity hemiparesis. He was consulted to neurologist, Digital Subtraction Angiography (DSA) and intraarterial thrombolysis was performed with alteplase. After DSA and thrombolysis, the procedure was continued, a stent was placed on the right coronary artery then the procedure was completed with the patient's hemodynamic stability. After ninth day of hospitalization, patient was discharge with stabile condition and vital sign, also without any neurological disorders.

Conclusion: Stroke is rare but can dangerously happened during PCI procedure. Maneuvers that have been shown to prevent periprocedural stroke are minimal. Some maneuvers like gentle removal of the wire from the catheter, washing the catheter after removing the wire, being cautious in using contrast injection and avoiding air bubbles can be performed to minimalization periprocedural stroke.

Keywords: Stroke, Primary Percutaneous Coronary Intervention, Acute Coronary Syndrome



Stroke during PPCI

Role of External Counterpulsation in Wellens Syndrome

F.B. Jaya¹, E. Mulia², E. Sari¹

Sari Maranatha Sehat Clinic, Bandar Lampung, Indonesia¹

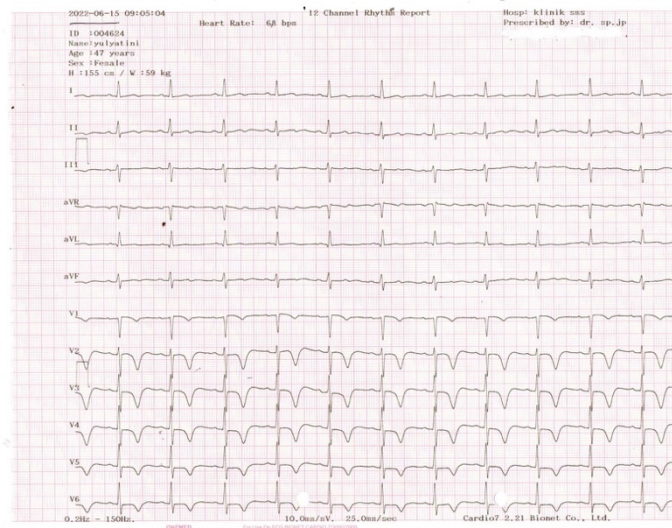
Sari Maranatha Sehat Clinic, Ahmad Yani Hospital²

Background: Wellens syndrome describes an abnormal typical electrocardiogram (ECG) pattern, deeply inverted T waves in leads V2 and V3, that are secondary to proximal left anterior descending artery (LAD) stenosis that is more than 50%. It usually comes with a history of chest pain, normal or slightly elevated cardiac enzymes, isoelectric or minimally elevated ST segment, preservation of precordial R-wave progression, and no precordial Q waves. Enhanced external counterpulsation (EECP) is a non-invasive treatment for angina pectoris that is refractory to pharmacotherapy and revascularization. The popular concept is that EECP may promote collateral development and improve myocardial perfusion, which may give additional benefit on top of conventional treatment.

Case illustration: A 47-year-old female patient came with typical chest pain and shortness of breath during activity since 1 month ago and worsened in the last 3 days. She had a history of hypertension and familial history of coronary artery disease. Physical examination showed normal blood pressure (126/72 mmHg) and normal heart rate (69 x/m). Electrocardiogram (ECG) showed inverted T waves which suited wellens syndrome. She was given clopidogrel 75 mg once daily, diltiazem HCl 100 mg once daily, rosuvastatin 20 mg once daily, ranolazine 375 mg twice daily. Echocardiogram showed preserved left ventricular ejection fraction with sign of left anterior descending wall motion abnormality. After EECP therapy sessions in combination with medical drug therapy, she was clinically improved. Her functional class and quality of life were improved. She could easily return to her daily work in the middle of the EECP therapy sessions. Abnormality in the ECG was also altered to sinus rhythm. The Seattle Angina Questionnaire scores was improved from 36 to 62.

Conclusion: In this case, EECP has shown promising treatment for Wellens syndrome which gives some beneficial effects on coronary system.

Keywords: External counterpulsation, Wellens syndrome, coronary system



Electrocardiogram (ECG) showed inverted T waves which suited wellens syndrome

Post-Thrombotic Syndrome: Long Term Sequelae of Deep Vein Thrombosis Complicating by Right Heart Failure

M. Reeiner¹, B.A.P.D. Sutanegara², A.P. Suwiry²

¹Faculty of Medicine, Udayana University, Denpasar, Indonesia; ²Vascular Division, Department of Cardiology and Vascular Medicine, Prof. Ngoerah Hospital, Bali, Indonesia

Background

Post-thrombotic syndrome (PTS) refers to the chronic manifestations of chronic venous insufficiency (CVI) following episodes of deep vein thrombosis (DVT), being an important and frequent long-term side effect of proximal DVT within two years in 20-50% of patients.

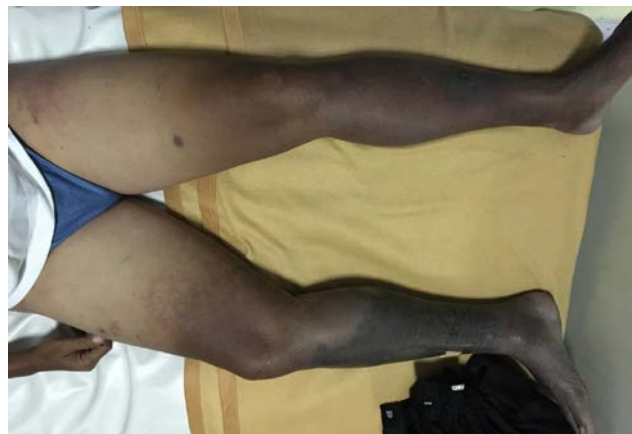Case Illustration

A 49-year-old male patient with a history of recurrent DVT on right lower extremity, right heart failure (RHF) and coronary artery disease post stenting with normal ejection fraction, complained pain, heavy sensation, persistent swollen and hyperpigmentation of both legs with multiple ulcers since a year before. Duplex ultrasound shows compression ultrasound negative on the right and left lower extremity vein, positive augmentation on the squeeze-release test on the right and left popliteal vein, positive reflux with squeeze test right popliteal vein 1.7 s, right and left femoral vein 1.0 s and 0.9 s, no thrombus was seen in the right and left popliteal vein, left common femoral vein. In DVT, the inflammatory response and incomplete thrombus acts as a functional obstruction, causes reflux. Pulmonary hypertension and right heart failure are often overlooked, these consequences add to the patient's burden and give the effect of systemic venous hypertension which will lead to backward failure. Villalta score can help to diagnose PTS, while DUS can be an additional examination to diagnose chronic vein insufficiency as a main pathophysiology of PTS. RHF and CVI can be an additive factor in development of PTS, since RHF worsen the systemic venous hypertension. Lifestyle modification and elastic compression stocking are the mainstay therapy. While endovascular and surgical correction are still being considered by the patient.

Conclusion

Long-term sustained increase in venous pressure caused by deep vein obstruction and exacerbated by peripheral venous hypertension due to right heart failure results in the development of severe PTS.

Keywords: post thrombotic syndrome, deep vein thrombosis, right heart failure



Lower extremities bilateral post thrombotic syndrome

Complex Congenital Heart Defect Case of Infant with Interrupted Aortic Arch Type B and Double Outlet Right Ventricle

M. Reeiner¹, E. Gunawijaya², V.K. Yantie²,

¹Faculty of Medicine, Udayana University, Denpasar, Indonesia;

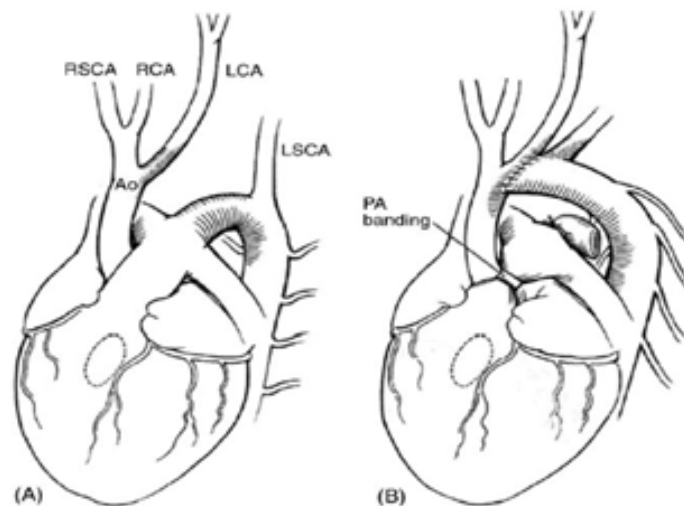
²Sanglah General Hospital, Denpasar, Indonesia

Background: An interrupted aortic arch is defined as complete discontinuity of the aortic lumen between segments of the aortic arch, a rare and fatal anomaly, accounting for about 1% of congenital cardiovascular defects, these congenital abnormalities can coexist with other congenital heart defects and entails a very poor prognosis without surgical treatment.

Case Illustration: A 11-month female with cyanotic congenital heart disease was referred to our center due to due to perioral and distal cyanosis when crying. Upon examination we found Interrupted aortic arch type B (Varians) with double outlet right ventricle doubly committed, dilated pulmonary artery, large patent ductus arteriosus, small atrial septal defect from echocardiography. On cardiac catheterization, the result was consistent with echocardiography result, with additional information of bicuspid pulmonary artery and severe pulmonary arterial hypertension. A biventricular approach will be carried out with 2 stages of the procedure. The first stage is repair of the interrupted aortic arch (end to side anastomosis + A. pulmonary autograft patch with a reverse flap of left subclavian artery or polytetrafluoroethylene graft), patent ductus arteriosus ligation, pulmonary artery banding, and will be followed by repeated cardiac catheterization examinations to assess pulmonary artery resistance. The second stage is pulmonary artery debanding and ventricular septal defect closure using an intraventricular tunneling patch or perforated patch.

Conclusion: Type B IAA accompanied by several other congenital abnormalities is a rare case thus comprehensive management and involvement of cardiac surgery team is needed to determine the best treatment plan for the patient, in this case a biventricular approach with 2 stages of surgery will be carried out.

Keywords: congenital heart defect, interrupted aortic arch, double outlet right ventricle, cyanotic heart disease



Lower extremities bilateral post thrombotic syndrome

A Case of Unexpected Death with Incidental Finding of Digoxin Effects on the ECG: who is the culprit?

S.D. Rasti¹, A.A.R. Sugiarto², A.P.A. Nuryandi³
RS Tk. II Dr. Soepraoen, Malang, Jawa Timur¹
RS Mawaddah Medika, Kab. Mojokerto, Jawa Timur²
RSUD Bhakti Dharma Husada, Surabaya, Jawa Timur³

Background

Although its current use in clinical practice is declining, digoxin is still known for its beneficial effects on the management of heart failure and atrial fibrillation cases. Digoxin has a narrow therapeutic window, hence requiring carefulness in its prescription.

Case Illustration

A 62-year-old woman presented with sudden loss of consciousness for 2 hours. Two days ago, she was taken to a “mantri” (orderly) for abdominal distension and chest tightness, then furosemide (1x20mg), metformin (2x500mg), glimepiride (2x2mg), ISDN (2x5mg), digoxin (2x0,25mg), and aspirin (1x100mg) were given. After taking these drugs, the patient complained of cold sweat. Upon examination, she was stuporous (GCS 1-1-3) and bradycardic 53x/min. Other vital signs were within normal limits. She was also severely hypoglycemic (20g/dl). She became fully awake after 3 flacons of D40% were administered. An AP chest x-ray showed cardiomegaly with suspicion of early lung edema. The ECG revealed sinus rhythm, with occasional PVCs, inverted T waves in V1-V2, and down-sloping ST depression as typical illustrations of digoxin effect namely “Salvador Dali sagging” in V5-V6. In the inpatient room, the patient complained of shortness of breath and malaise, but the blood sugar was normal (131g/dl). After 5 hours of treatment, the patient's condition suddenly deteriorated rapidly. The blood pressure became 60/palpation, with bradycardia 48x/min. Unfortunately, no repeated ECG was done. The patient's condition continued to worsen and she eventually died 30 minutes later after attempted resuscitation. Cardiac arrhythmias account for most deaths in digitalis intoxication cases and they can occur even when patients are asymptomatic. Suspicion for digoxin intoxication arises from the history of digoxin consumption twice daily as an initial dose without monitoring, which is inappropriate. However, its diagnosis couldn't be established considering no serum examination was done.

Conclusion

Physicians should be thoughtful of the subtle manifestations after digitalis administration attributable to its narrow therapeutic window.

Keywords: digoxin effect, digitalis intoxication, unexpected death

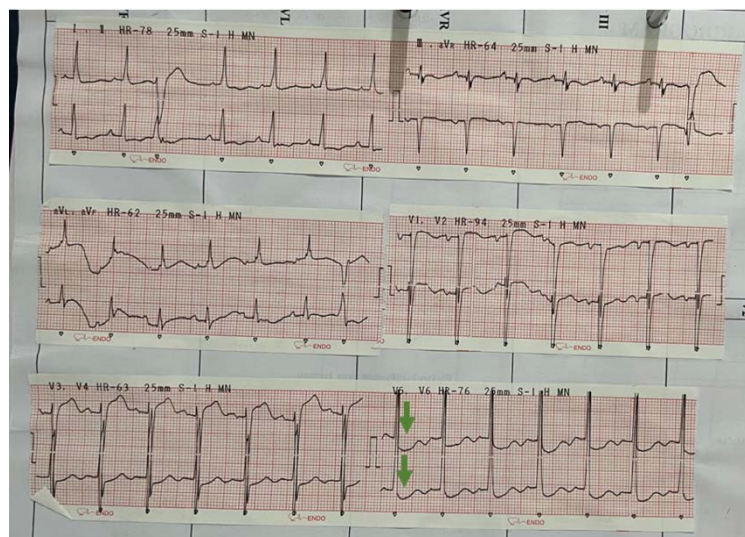


Figure 1. The ECG performed in the emergency room; the green arrow shows “Salvador Dali sagging”, a mark of digital effects.

ANOMALOUS ORIGIN OF THE RIGHT PULMONARY ARTERY FROM ASCENDING AORTA: A RARE CONGENITAL HEART DISEASE CASE

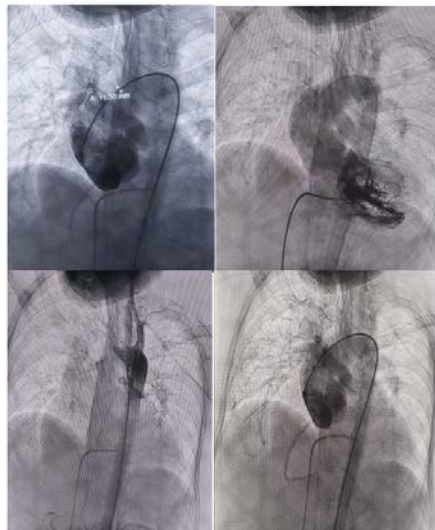
F. Yuliani¹, Kino¹, D. Hariyanto¹
RSUP Dr M DJAMIL PADANG¹

Background: Anomalous origin of the right pulmonary artery from ascending aorta (AORPA) is a very rare congenital cardiac malformation that happened 0.1% of all congenital heart disease. Only 5% of this case reported in adult. The most common condition that related to AORPA is patent ductus arteriosus, Tetralogy of Fallot (TOF), atrial septal defect, ventricular septal defect (VSD), and coarctatio aorta.

Case Illustration: a 11 years old girl, was referred to our hospital due to exertional dyspnoea worsened with time and mildly improve by resting in the last 2 months before admission. She also had cyanosis in extremities. Her body weight was 29 kg. The patient already known heart disease since young but never controlled to cardiologist. Physical examination revealed moderate condition. Heart rate was regular, and normal blood pressure and 80% oxygen saturation. Chest heart sound was pansystolic murmur grade 3/6 at the apex. Laboratory test concluded polycythemia with Hb 22.1 gr/dl and haematocrit 67%. Her electrocardiography showed sinus rhythm with right ventricular enlargement and chest radiograph showed cardiomegaly with boot shaped appearance. Echocardiography conclusion was Tetralogy of Fallot-Pulmonary Atresia (TOF-PA), Mayor Aortopulmonary Collateral Arteries (MAPCAS), good LV and RV function, and left arch. Initially patient was diagnosed with TOF-PA. After Aortography it was found that there were PA-VSD, AORPA, and arborisation left pulmonary from MAPCAS.

Conclusion: Due to high mortality case, it is important to early diagnose patient with AORPA condition in order to treat patient as soon as possible with surgical correction and for better prognosis in the future. A high of clinical suspicion is required especially unexplained heart failure with TOF PA echocardiography as seen in this case

Keywords: AORPA, TOF-PA, PA-VSD, MAPCAS



Heart Catheterization of AORPA

A Case Report: ST-Segment Elevation ECG on Hypertension and Diabetes Mellitus Patient with Chest Pain mimicking STEMI

P.N. Permatasari¹, I. Handirosiyanto²
General Practitioner, Baptis Batu Hospital, Malang, Indonesia¹
Cardiologist, Baptis Batu Hospital, Malang, Indonesia²

Background: Electrocardiogram is crucial for diagnosing STEMI because “time is muscle”, the longer the infarct time, the greater the ischemia and necrosis myocardium. Early and correct diagnoses are needed to make better decisions, regarding pharmacological or mechanical revascularization. However, recording and interpretation of 12-lead ECG in patients remain challenging. ST-segment elevation also could be caused by many non-cardiac conditions that mimic STEMI.

Case Illustration: A 65-year-old Man was transferred to the Cardiology department because of chest pain within one week and ST-Elevation ECG. He had controlled DM and HT. There was no symptom of typical chest pain, DOE, or congestion. BP: 150/90 mmHg, HR: 56 times/minute. In general examination no rales, no abnormality of heart sound, or signs of congestion. The first record showed ST-Elevation in Lead II, III, aVR, aVL, and aVF. Cardiologist re-recorded a 12-lead ECG of the patient. The patient took off all metallic belonging including the metal belt. The ECG showed no ST-Elevation on all leads. Turn out that in the first record, the patient just took off his coin and car key from his pocket. He still used a metal belt that made ECG show ST-Elevation in Lead II, III, aVR, aVL, and aVF.

Conclusion: Recording and interpretation of 12-lead ECG are very crucial. Every paramedic and doctor should be aware that there was no metal in the patient such as a belt, key, coin, or jewel. Metal material made an electrical disturbance to the recording ECG making it mimics STEMI.

Keywords: Electrocardiogram, Mimicking STEMI, ST-Segment Elevation

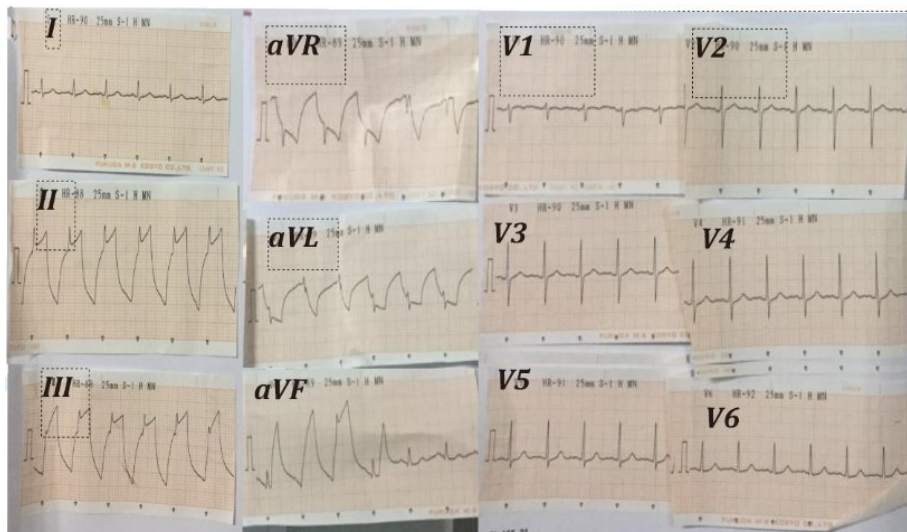


Figure 1: The First 12-Lead ECG



ACUTE LIMB ISCHEMIC AS COMPLICATION OF FEMORALIS PUNCTURE : A CASE REPORT

F.Q. Decroli¹, W. Erlanda², H. Kam³

Department of Emergency Medicine, M Djamil Hospital Padang¹

Division of Cardiology Faculty of Medicine, Andalas University / M. Djamil Hospital Padang²

Division of Surgery Faculty of Medicine, Andalas University / M. Djamil Hospital Padang³

Background: Acute limb ischemia is a sudden decrease in limb blood perfusion with an onset of less than 14 days, commonly occurs in lower extremities. Iatrogenic complications related to cardiac catheterization is one of the potential embolic causes which are related to a sudden decrease in arterial perfusion in the limb. Local thrombosis of the femoral artery or lower extremity vessel related to the access site is unusual, reported to occur in less than 1%. In this case report we present who developed ALI due to prior femoralis puncture that had successful thrombectomy treatment.

Case Illustration: 60 years old female patient brought to us with continuous pain on the right foot for three days and worsened in 24 hours prior to admission. Patient underwent Percutaneous Transluminal Coronary Angioplasty (PTCA) 4 days before the admission due to CAD2VD. No prior history of intermittent claudication before the procedure, and claudication worsened after the procedure. The right foot felt numb and weak. The fingers were pale and cold as well. The right foot had no pulsated from popliteal to dorsalis pedis artery, weak brachial pulse and undetected pulse oximetry result. Doppler Sonography revealed that there was no flow in the right common femoral artery. On the first day of hospitalization, the patient was scheduled for emergency thrombectomy at M Djamil Hospital Padang. Follow-up on the seventh-day post-surgery, the patient had no complaints of pain and pale in the right foot and the popliteal, tibialis, and dorsalis pedis arteries were palpable.

Conclusion: Catheter-artery mismatch, the presence of peripheral vascular disease, advance age, cardiomyopathy and the presence of hypercoagulable states are risk factors of local thrombosis of the femoral artery. In the absence of predisposing factors, vessel dissection or spasm may also contribute. Early thrombectomy shows excellent prognosis in this case.

Keywords: acute limb ischemia, femoralis puncture, thrombectomy

Aneurysmatic Patient Presenting with ST-Elevation Myocardial Infarction: Role of Multimodality Imaging in Emergency Setting

Y.A. Fikri¹, E.P.B. Mulia², F.W. Nugroho²

General Practitioner, Dr. Soetrasno Regional General Hospital Rembang¹

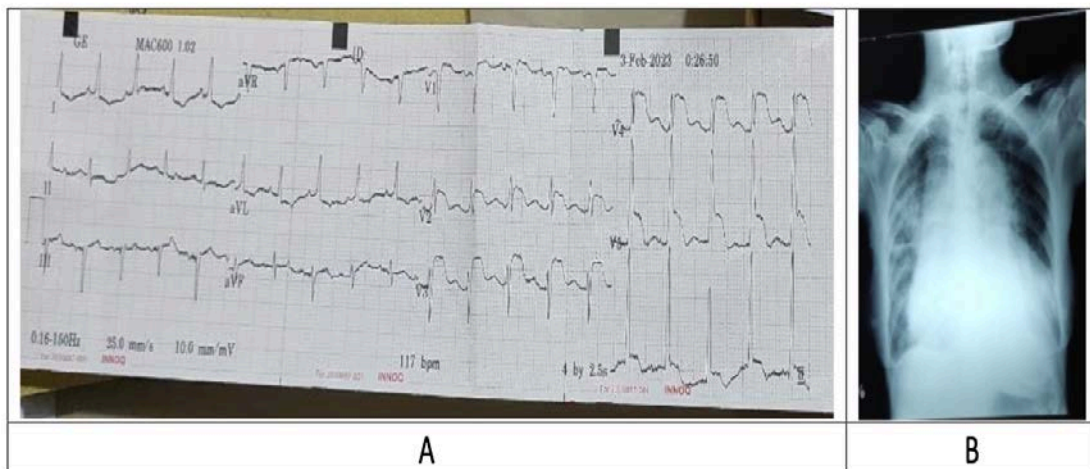
Department of Cardiology and Vascular Medicine, Dr. Soetrasno Regional General Hospital Rembang²

Background: Aortic dissection with concurrent ST-elevation myocardial infarction (STEMI) is rarely reported. As the proportion of myocardial infarction is higher in the emergency setting compared to aortic dissection, the diagnosis of aortic dissection may be overlooked, and it can be potentially fatal. By using bedside available information, detailed history taking and multimodality imaging in the emergency setting, it is possible to avoid a mistaken diagnosis. Here we present a case of aortic aneurysm presenting with anterior STEMI.


Case Illustration: A 79-year-old woman was admitted to our emergency department with decreased consciousness. Shortly before the patient went unconscious, she had a short episode of dyspnea. Her ECG showed marked ST elevation in the anterior leads (Figure 1A). However, her chest radiograph revealed mediastinal widening and a prominent aortic knob (Figure 1B). Due to suspicion of aortic dissection from the chest radiograph and loss of consciousness, which may be a sign of malperfusion syndrome of aortic dissection, bedside handheld echocardiography was then performed. It revealed hypokinesis of anterior and anteroseptal walls, pericardial effusion, and dilated aortic root to ascending aorta with severe aortic regurgitation. The presence of intimal flap can not be clearly excluded. Based on her imaging and clinical findings, aortic dissection was suspected and thrombolysis was postponed. The patient proceeded to undergo triple-rule-out computed tomography, from which the finding of ascending aortic aneurysm was noted, along with multiple stenosis of LAD (moderate-to-severe) and LCx (moderate), and there was no presence of false lumen.

Conclusion: Acute aortic dissection should be considered as a differential diagnosis in patients presenting with symptoms suggesting acute coronary syndrome. A suspected case of acute aortic dissection should necessitate further imaging studies. Therefore, multimodality imaging plays a vital role in the emergency setting, as it may avoid fatal consequences of misdiagnosis and mistreatment.

Keywords: aortic aneurysm, aortic dissection, myocardial infarction, chest pain, imaging, emergency



A) ECG showed marked ST elevation in the anterior leads. B) Chest radiograph revealed mediastinal widening and a prominent aortic knob.



A 70-years-old male who survived 22 times of defibrillation shocks after inotropes-induced recurrent ventricular fibrillation

S.D. Rasti¹, A.P.A. Nuryandi², A.A.R. Sugiarto³, F. Hartono⁴
RS Tk. II Dr. Soepraoen, Malang, Jawa Timur¹
RSUD Bhakti Dharma Husada, Surabaya, Jawa Timur²
RS Mawaddah Medika, Kab. Mojokerto, Jawa Timur³

Department of Cardiology and Vascular Medicine, RSPAL Dr. Ramelan, Surabaya, Jawa Timur⁴

Background

Inotropic and vasopressor agents are becoming cornerstones of therapy for the treatment of important cardiovascular syndromes. These agents increase myocardial oxygen consumption and can exert proarrhythmic effects.

Case Illustration

A 70-year-old male patient was referred to the emergency room from a peripheral hospital for recurrent ventricular fibrillation. He has a history of gastritis and hypertension. Initially, he came with a seizure after vomiting and heartburn. He then experienced sudden chest pain and the first cardiac arrest where VF was found on the ECG. Advanced cardiac support was immediately started. During 4 days of treatment, VF episodes occurred daily and 22 defibrillation shocks were administered in total. Historically, some drugs such as furosemide, fondaparinux, corrective KCL drip, lidocaine, dobutamine, and norepinephrine pump were given. After referral, dobutamine and norepinephrine were immediately tapered off, while lidocaine was maintained. The patient's condition improved and the VF did not recur. His echocardiogram revealed decreased LV systolic function (EF 31%) and eccentric LVH with grade II diastolic dysfunction. He was assessed with recurrent cardiac arrest due to coronary artery disease with old myocardial infarct, ischemic cardiomyopathy, and hypertensive heart disease. A week later, he was well recovered and scheduled for ICD insertion and PCI at the central referral hospital. Malignant ventricular arrhythmias may be observed in dobutamine use at any dose. Patients with underlying arrhythmia, heart failure, or ischemic heart disease are at greater risk of proarrhythmia. The suspected involvement of inotropic in the development of recurrent VF in this patient is supported by clinical improvement after its tapering.

Conclusion

Electrolyte imbalances, ischemia, catecholamines, and inotropes may worsen arrhythmias and increase ventricular susceptibility to sustained arrhythmias. The likelihood of both successful resuscitation and survival of a cardiac arrest patient is inversely proportional to the total number of defibrillation shocks required for cardioversion. Therefore, be mindful of handling it.

Keywords: ventricular fibrillation, inotropes, arrhythmias, recurrent VF, defibrillation

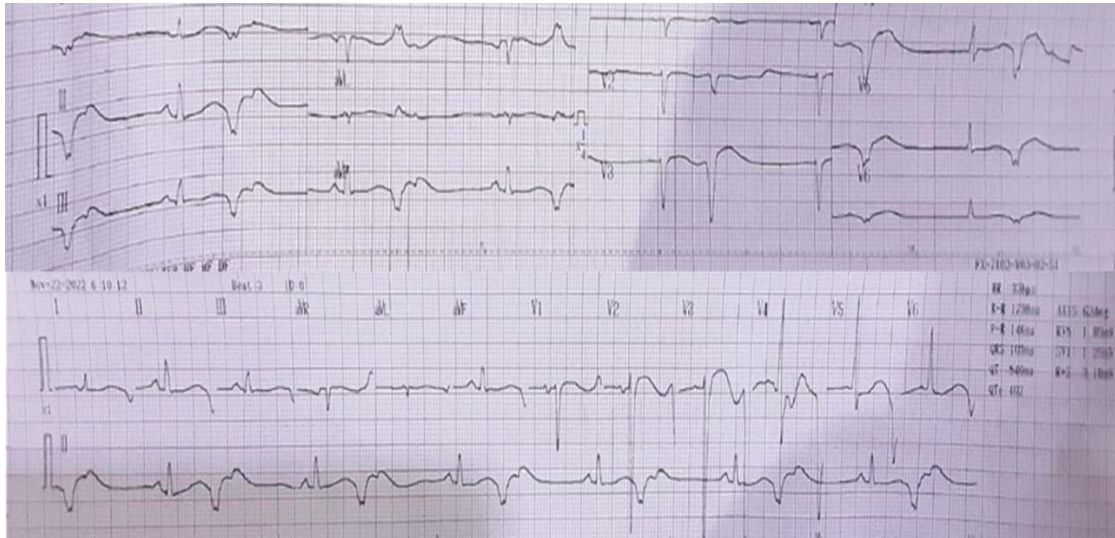


Figure 1. The ECG 3 days upon referral; after dobutamine and norepinephrine were tapered off, bigeminy and occasional PVC were still found

HYPERKALEMIA IN CHRONIC HEART FAILURE IS INVISIBLE, INSIDIOUS, AND DEADLY: A CASE REPORT

A.I. Pramesti¹, Z. Ramadhanty¹
Faculty of Medicine, Sebelas Maret University¹

Background:Hyperkalemia is an increased level of serum potassium $>5,5$ mmol/L that shows nonspecific signs such as bowel and muscle discomfort, paralysis, and arrhythmias that lead to cardiac arrest. ECG examination shows specific abnormalities and helps with the diagnosis. We report a case of a chronic heart failure patient with severe hyperkalemia who showed no specific signs, symptoms, and ECG abnormalities.

Case Illustration:A 71-year-old woman with a history of chronic heart failure came to the polyclinic for monthly control, with the results of blood tests was severe hyperkalemia with a K^+ value of 8.09mmol/L, increased ureum 126 mg/dl and creatinine 2 .87 mg/dL. The patient comes asymptomatic. Patient's heart rate was 63 bpm regular, blood pressure was 108/56mmHg, respiratory rate was 16breaths/min, and oxygen saturation was 98%. Physical examination of the heart revealed heart murmurs in the pansystolic mitral and tricuspid areas with grade 2/6, low pitch, without radiating. Other physical examination found no abnormalities. Electrocardiogram showed physiological left axis deviation, complete left bundle branch block, 2:1 advanced AV block degree 2, left ventricular hypertrophy, anterior T wave inversion, and poor r wave progression, and did not showed hyperkalemia. Echocardiography results showed significant improvement in left ventricular systolic function compared to the result three months earlier. Patients routinely take aspirin, simvastatin, amlodipine, bisoprolol, candesartan, spironolactone, thyrozol, and furosemide. The patient denied any history of kidney disease or diabetes mellitus. Severe hyperkalemia was successfully treated after potassium correction.

Conclusion:Patients with heart failure with comorbidities in the form of kidney disease and receiving drugs with the effect of reducing excretion of potassium may cause hyperkalemia which does not show signs, symptoms, or typical ECG features. Assessment of risk factors, understanding the mechanism of the drugs, and periodic examination of serum electrolytes can prevent hidden hyperkalemia thereby reducing mortality and morbidity.

Keywords: Hyperkalemia, Chronic Heart Failure, Acute Kidney Injury

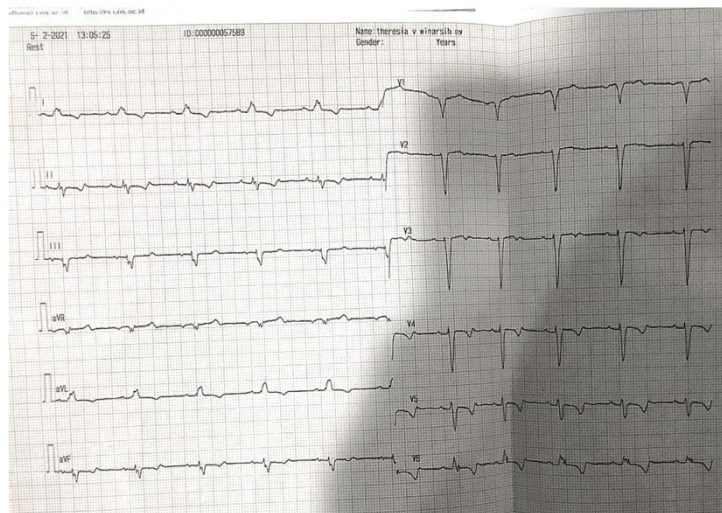


Figure 1. Patient's Electrocardiogram

BLOOD CULTURE NEGATIVE IN NATIVE VALVE INFECTIVE ENDOCARDITIS

N. Syauqi¹

¹Tarakan General Hospital, Jakarta, Indonesia

Corresponding author email: dr.nafisadnan@gmail.com

ABSTRACT

BACKGROUND

Infective endocarditis is a serious cardiac condition characterized by inflammation of the heart's endothelium, with a mortality rate of up to 30%. Diagnosis relies on symptoms, blood cultures, and echocardiography. However, diagnosing the disease becomes more complex when blood cultures yield negative results, which occurs in about 20% of cases, making prompt diagnosis and treatment difficult.

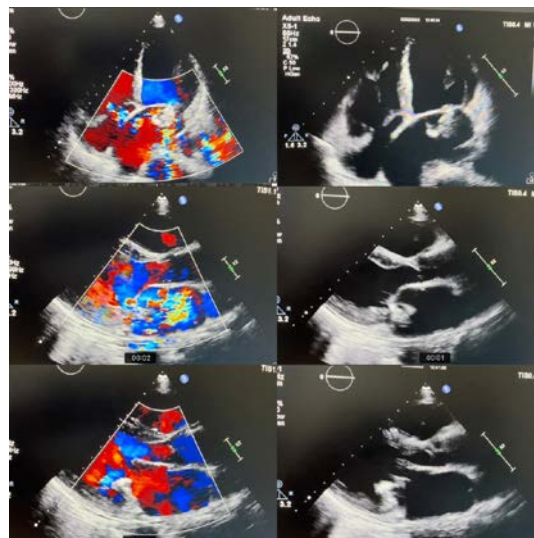
CASE ILLUSTRATION

A 56-year-old woman presented with shortness of breath and leg swelling, as well as high fever and no other symptoms. Her vital signs showed a high heart rate and blood pressure, and her physical examination revealed lung rales, a systolic murmur, and edema in her legs. Chest X-ray revealed an enlarged heart. Echocardiography showed vegetation and mitral regurgitation (fig.1). Modified Duke criteria were used to diagnose vegetation and history of fever as 1 major and 1 minor criteria yield in diagnosing possible endocarditis. Blood cultures were performed with negative results. The previous use of antibiotics is thought to be the cause of the negative blood culture result.

CONCLUSION

Diagnosing infective endocarditis (IE) is difficult due to patients lack of distinctive symptoms, despite the high mortality rate associated with IE. The results of supporting examinations and the establishment of diagnosis based on clinical criteria, supporting tests, and microbiological examinations remain crucial in diagnosing IE. Negative blood culture results still challenge establishing a diagnosis and initiating therapy. The presence of structural abnormalities and complications of heart failure are the main considerations for performing valve replacement.

Keywords: infective endocarditis, valvular disease



A Rare Case of Torsade de Pointes Following Dental Procedure: Idiosyncratic or Common Adverse Reaction?

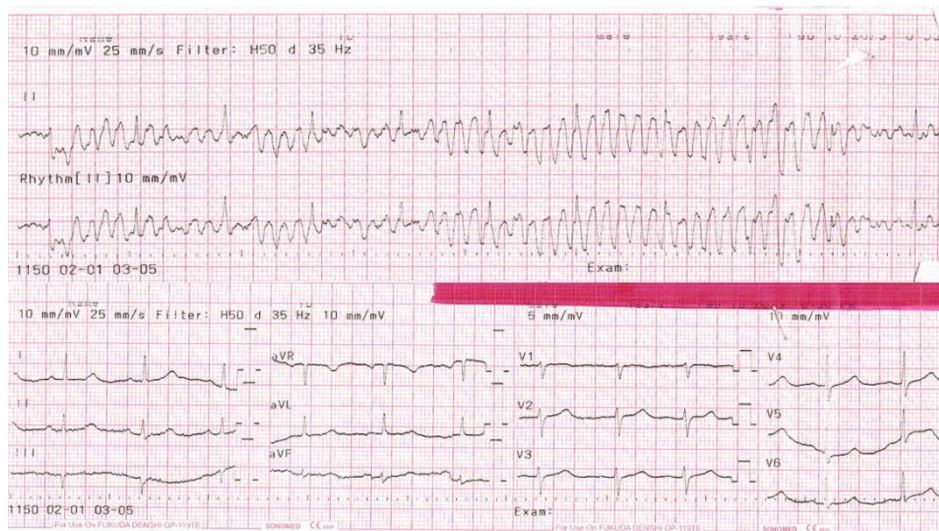
C.J. Purba¹, S.D.T. Sitanggang², A.E. Prasetya¹
Putri Hijau Hospital, Medan¹
RSUD Pakuhaji, Tangerang²

Background : Ventricular arrhythmia is one of most lethal complication following a heart attack. However, not all ventricular arrhythmia solely caused by primary cardiac problems yet it can also be precipitated by extrinsic factors. One of the most common extrinsic factors causing ventricular arrhythmia is drug-induced ventricular arrhythmia. In this report, we aim to present a rare case of polymorphic ventricular tachycardia, particularly Torsade de Pointes (TdP), that was induced during dental procedure after local anesthesia drug injection.

Case Illustration : A 49-year-old male with pulp necrosis came into dental polyclinic to undergo tooth extraction. He had no previous medical history. Before the procedure, local anesthesia was performed using lidocaine-epinephrine solution (lidocaine HCl 40 mg, epinephrine 0.025 mg). The patient was frightened and anxious, thus the procedure took longer than expected. Second lidocaine-epinephrine injection of the same dose was administered after the patient started to feel pain. Several minutes after the second dose, he started to experience palpitations, tremor, and diaphoresis. The patient was then admitted to the emergency room and electrocardiography (ECG) examination was performed. ECG showed TdP waveform as depicted in Figure 1. Hemodynamic was stable and bedside monitor was placed. After <1 minute, his heart rate spontaneously recovered to a normal sinus rhythm. He was admitted to the intensive care unit and no recurrence of TdP was observed. Lab results were unremarkable. The patient was discharged after 3 days of hospitalization.

Conclusion : This case demonstrates that a healthy patient without any heart disease may experience a brief episode of Torsade De Pointes even after receiving a clinical dose of epinephrine-lidocaine local injection. Catecholamines surge was suggested as the underlying mechanism. Therefore, patients who received epinephrine-containing anesthesia need to be monitored for any possible major cardiovascular side effects.

Keywords: Torsade de Pointes, catecholamine, arrhythmia, dental procedure, adverse reaction



Documented TdP and patient's baseline ECG, taken almost simultaneously.

Facing Up Complex Coronary Bifurcation Lesion with Left Main Involvement: The Upfront 2 Stents Method

Subiyanto¹, C. Kurniawan¹, G. Soemara¹, J.A. Pangemanan¹, A.L. Panda¹

Department of Cardiology and Vascular Medicine Sam Ratulangi University Prof. Dr. R.D. Kandou General Hospital Manado, Indonesia¹

Background : Bifurcation lesion accounts for 15-20% of all percutaneous coronary intervention (PCI) leads to more complex procedures especially involving left main branch. Approaching this complex lesion, provisional or planned two stents are the choices. PCI procedure on bifurcation lesion with LM involvement by upfront two stents method, T- stenting will be shared through this case report.


Case Illustration: A 57 years old male admitted into Emergency Department due to a typical angina chest pain during treadmill and his resting ECG 12-lead showed sinus rhythm with slight elevation at lead AVR and V1, ST depression at lead I, II, AVL, AVF, V4-6 as well as LVH with strain without any changes after serial ECG. Patient has been previously diagnosed of chronic coronary syndrome with recent echocardiography showed normal ejection fraction at 65%, global normokinetic. Cardiac markers of troponin T in normal range and not rising as well as the creatinine kinase level. During the procedure, coronary angiography revealed left main bifurcation lesion Medina 1-1-1 with significant lesion in proximal LAD (90%) and ostial LCx (80%). As the side branch (LCx) diameter is > 2.5mm, lesion length > 10mm, and bifurcation lesion angle > 70, It fulfilled the requirement of complex bifurcation lesion, which demands two-stents strategy. Our operator was, then, chose a T-stenting method by first preparing the lesion by dilating the main vessels, then deploying side branch stent followed by main vessel (LM-LAD) stent; lastly, kissing balloon inflation in the bifurcation site and Proximal Optimization Technique of main vessel afterward. The procedure resulted in TIMI flow 3 without complications.

Conclusion: The two-stents method is best suited in complex bifurcation lesion. T-stenting technique is the primary option when the angle of the bifurcation is close to 90°.

Keywords: Bifurcation Lesion, Intervention Cardiology, PCI, T-stenting, Two-stents method

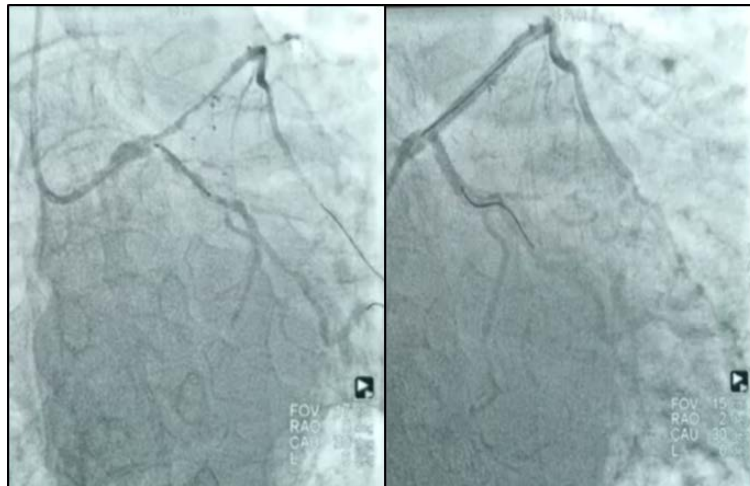

Figure 1. Coronary angiography results pre- and post stenting



Non-ST-segment Elevation Acute Coronary Syndrome Presenting with Acute Pulmonary Oedema and Gastro-Intestinal Bleeding: Thrombosis vs Bleeding Risk Management

H.T. Abdurrahman¹, Haikal²

Cardiology Resident, Faculty of Medicine, Airlangga University¹

Cardiology Consultant, Department of Cardiology and Vascular Medicine, Gatot Soebroto Army Central Hospital²

Background: Non-ST-segment Elevation Acute Coronary Syndrome (NSTEMI-ACS) presenting with acute pulmonary oedema has a high risk of mortality and morbidity and should be treated with an intervention strategy. However, some of these patients may develop gastro-intestinal bleeding (GIB) before an intervention strategy is performed. The risk of bleeding was higher in this case.

Case illustration: A 52-year-old man came to the ED of Gatot Soebroto Army Central Hospital after complaining of severe shortness of breath. Several hours earlier, the patient had complained of epigastric pain accompanied by diaphoresis. His BP was 192/118 mmHg, oxygen saturation was 68%, and rales in half of his both lungs on physical examination. The ECG showed T inverted in lead II, III, and aVF. Laboratory findings showed an increase in Troponin I level. The patient was diagnosed with NSTEMI very high risk, acute pulmonary oedema, and hypertensive emergency. He was then intubated after initial treatment of acute pulmonary oedema failed to relieve his condition. DAPT was given using an NGT, and an intervention strategy was planned. However, NGT showed GIB, and the intervention strategy was postponed. He was managed by a multidisciplinary team with a gastroenterohepatologist.

Conclusion: NSTEMI-ACS with acute pulmonary oedema carries a high risk of mortality, and GIB makes the condition more complex. The risk of thrombosis and bleeding should be managed by a multidisciplinary team. Even though this condition should be treated with an intervention strategy, the timing of the intervention itself should be managed to the patient's condition.

Keywords: NSTEMI-ACS, acute pulmonary oedema, GIB

Sleep-Bruxism: Is it a New Sign of Hypertension and Other Cardiovascular Disease?

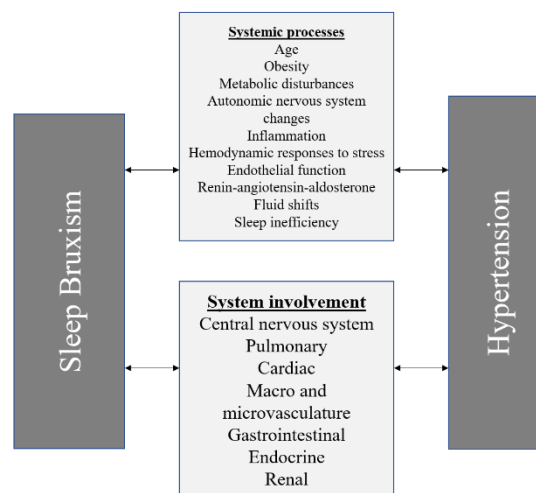
S. Chandra¹, A.A. Lukito¹, R.A.P. Fernandes¹, H. Hutabarat¹, I. Sabrina¹
Siloam Hospital Lippo Village¹

Background Sleep disordered breathing is a common and serious health problem. Accordingly to epidemiological data, it may affect about 20% of the adult population. The majorities are not aware of the disease. Bruxism is associated with increased masticatory muscle activity during sleep, which may be phased or tonic. It is estimated that the incidence of bruxism in the adult population is 13%. Sleep bruxism is associated with blood pressure fluctuations during sleep. Arousals and body movement often occur with sleep bruxism and can impact the magnitude of this blood pressure surge.

Case Illustration A 57-year-old woman presented with unstable blood pressure, with a previous medical history of hypertension for 2 years ago, and prediabetic state. On physical examination, blood pressure 130/77 mmHg, pulse 70 bpm regular, BMI scale was obese. Before diagnosed hypertension, patient did not snore when sleep, but had grinding her teeth when sleep since a long time ago. Treadmill Stress Test revealed negative ischemic response, hypertension at peak exercise around 220/62 mmHg. Therefore suggestion for this case was losing weight (exercise and intermittent fasting), and blood pressure medication.

Conclusions Sleep bruxism is associated with external factors (such as stress, anxiety) and OSA. Most sleep bruxism episodes are under the transient influence of cardiac sympathetic activity (as a promoter of arousal), as shown in a rapid rise in heart rate at the onset of rhythmic masticatory muscle activity (time domain estimate of heart rate acceleration (tachycardia) or deceleration (bradycardia) during recurrent sleep arousal. In this case, this patient had a sleep bruxism since a long time ago but did not aware. Even though the patient tells did not has sleep apnea but her BMI was obese prone to OSA. Next examination for definitive diagnostic was polysomnography for OSA and sleep bruxism.

Keywords: Hypertension, Sleep-bruxism, Cardiovascular-disease



Pathophysiologic Links Between Sleep-bruxism and Hypertension

THROMBOEMBOLECTOMY ON A RARE CASE OF ACUTE UPPER LIMB ISCHEMIC RUTHERFORD IIA WITH ATRIAL FIBRILLATION

D.B. Lululangi¹, H.A.K. Cantika¹, M.B.S. Ilham², R.P. Wicaksono³, R. Putra⁴

General Practitioner, KRMT Wongsonegoro State Hospital, Semarang, Indonesia¹

Internship Doctor, Bhayangkara Hospital, Denpasar, Indonesia²

Department of Cardiothoracic Surgery, KRMT Wongsonegoro State Hospital, Semarang, Indonesia³

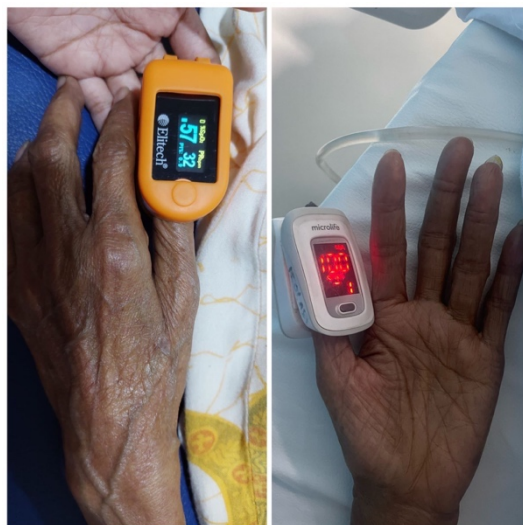Department of Cardiology, KRMT Wongsonegoro State Hospital, Semarang, Indonesia⁴

Background: Acute Upper Limb Ischemia (AULI) is a rare condition compared to lower limb ischemia, accounting for less than 5% of all cases and predominantly associated with atrial fibrillation. Despite the management of AULI can be conservative, however, revascularization procedure remains the treatment of choice.

Case Illustration: A 77-year-old female was referred to our emergency unit with the sudden, 8-hour onset of severe pain in the left arm accompanied by paresthesia and paralysis. The patient had a history of hypertension, underlying cardiac condition, and absence of prior traumatic incidents. Physical examination presented grade II hypertension with an irregular, weakened left radial pulse of 40 bpm, compared to a right radial pulse of 80 bpm. Neurovascular assessment of the left arm revealed poikilothermic and pallor extremity with finger oxygen saturation of 57%, 76%, -, -, and 83%, respectively. There were sensory deficits at the C4-C5 dermatome level with a subsequent decline of motoric arm strength at elbow level to fingertips. Cardiomegaly and atrial fibrillation were then found during further exams. From the doppler ultrasound, there was a thrombus in the left brachial artery hence patient confirmed the diagnosis of AULI grade IIA according to the Rutherford classification. Furthermore, the patient received anticoagulants, antiarrhythmic, and antihypertensive. Thromboembolectomy was then performed using a Fogarty catheter and a thrombus of approximately 5 ccs was obtained. The patient showed clinical improvement in the left arm, including optimal pulse oximetry level, adequate arterial pulse, and relief of symptoms. Postoperative transthoracic echocardiography reported no thrombi were recorded. The patient was discharged after being stabilized in ICU for further outpatient treatment.

Conclusion: AULI represents a vascular emergency, which requires timely recognition and treatment. Revascularization without delay should be considered once there are signs of severe, progressive ischemia for enhancing long-term patient outcomes.

Keywords: acute upper limb ischemia, thromboembolectomy



Comparison of finger oxygen saturation before thromboembolectomy (left) and after (right) showed improvement.

Early Diagnosis of Rare Type Ventricular Septal Defect: A Gerbode Defect Case Report

T.L.J. Putri¹, M.R.M.P. Sinurat¹
RSUD Cileungsi¹

BACKGROUND

Atrial septal defect and Ventricular septal defect are the most common type of congenital heart disease. There is an uncommon type of those communication anomaly, a left ventricle to right atrium connection, which is called the Gerbode defect. In this case we present incidental finding of VSD with Gerbode physiology.

CASE ILLUSTRATION

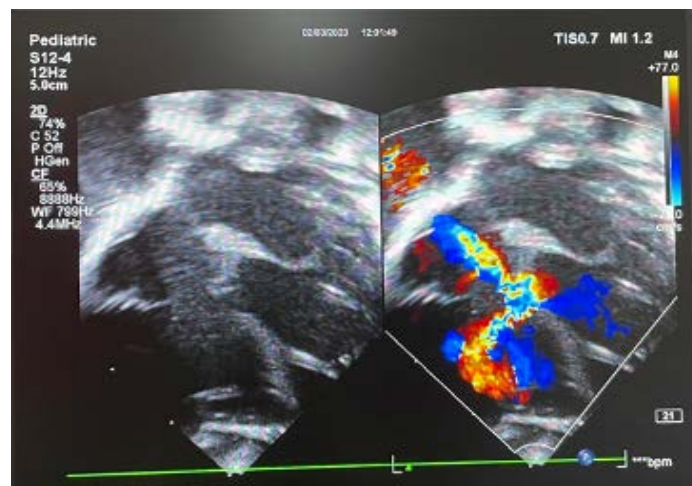
A term and fit 2-day-old neonate were referred from pediatrician for congenital heart disease screening. She came to ER with melena 1 day before admission. There is no cyanosis and dyspnea. On physical examination, vital sign is within normal limit, a holosystolic grade 3/6 murmur was found on the lower left sternal border. Trans-thoracic echocardiography showed a secundum ASD 2,1mm with left to right shunt and VSD 3,2mm with left to right shunt to right atrium and right ventricle. This condition matches the gerbode defect which caused by the connection between the left ventricle and the right atrium, resulting in high flow from the left ventricle into the right heart. A high doppler gradient is one of the hallmarks of the Gerbode ⁽¹⁾ Without early intervention, VSD Gerbode and ASD may causing early-onset Eisenmenger syndrome.

After stabilization, patient was referred to the tertiary hospital to undergo further assessment.

CONCLUSION

Trans-thoracic echocardiography can be used to detect CHD. CHD screening should be encouraged in any certain condition because some CHD might be asymptomatic. By doing early screening, we can lower the mortality and morbidity of CHD in the future.

Keywords: Gerbode defect, Ventricular Septal Defect, Atrial Septal Defect, Congenital heart disease



Echocardiography showed a left ventricle and right atrium connection which is called a Gerbode defect

When the Cure Causes the Pain: Post-Cardiac Injury Syndrome Following Ventricular Tachycardia Ablation

D.J. Pesireron, D. Nugraha, P. Ardhianto, A.Y.A.B. Muchtar, S. Sungkar¹

¹ Department of Cardiology and Vascular Medicine, Faculty of Medicine Diponegoro University- Dr. Kariadi Central General Hospital, Semarang, Indonesia

Background:

Post Cardiac Injury Syndrome (PCIS) is an inflammatory syndrome secondary to cardiac injury that develop after percutaneous cardiac intervention such as catheter ablation. Acute post-ablation pericardial effusion as a manifestation of PCIS is a common complications of atrial fibrillation ablation but its occurrence following an uneventful PVC catheter ablation is rare.

Case Illustration:

47-year-old women with complaints of frequent palpitations. Holter monitoring showed frequent premature ventricular contraction (PVC) with episodes of non-sustained ventricular tachycardia. Patient was referred for an electrophysiological study and catheter ablation. During the procedure ventricular tachycardia with right ventricular outflow tract (RVOT) origin was recorded. A total of four radiofrequency (RF) burns were applied to the anterior and posterior-mid septal region of RVOT. In the following day, the patient complained of severe chest discomfort with a slight dyspneu, relieved when she's leaning forward. 12 lead ECG examinations showed ST elevation in almost all lead (lead I, II, II, avF, avL, V4-V6), with PR depression. Laboratory findings showed elevated CRP and Troponin, Transthoracic echocardiography revealed circumferential pericardial effusion. The patient was diagnosed with PCIS and initiated on NSAID, steroid and low-dose colchicine. At a 5-day follow-up, the patient was free of symptoms and the pericardial effusion was diminished.

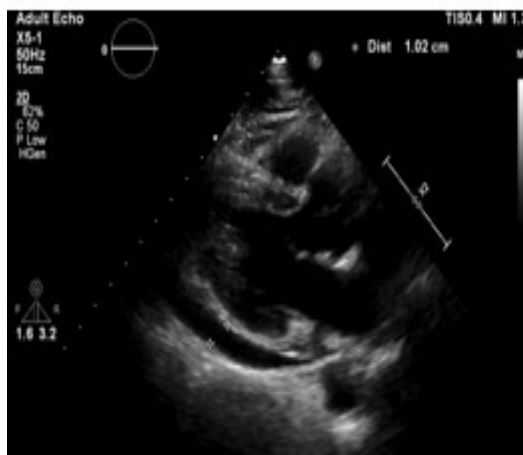Conclusion:

Pericarditis as a manifestation of Post Cardiac Injury Syndrome (PCIS) although rarely occurred following a PVC catheter ablation, can still happen. Early identification and prompt treatment is vital to mitigate the complication.

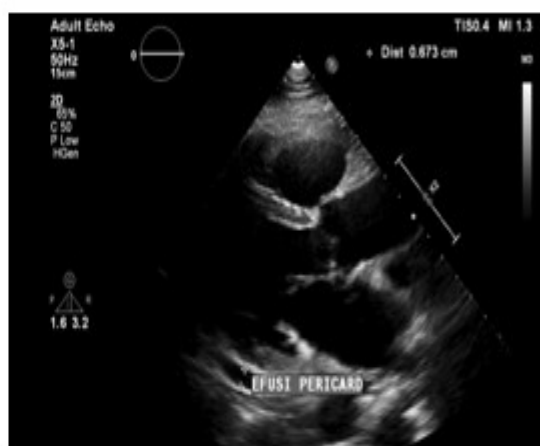Keyword:

Post cardiac injury syndrome, inflammation, ablation, pericardial effusion

Keywords: Post cardiac injury syndrome, inflammation, ablation, pericardial effusion



TTE Post Ablation



TTE Follow Up

REVERSE CARDIAC REMODELLING IN ADVANCED HEART FAILURE PATIENT

R. Sebastian¹, M. Putra²

¹Departement of emergency, Ibnu Sina Padang Hospital, West Sumatra, Indonesia.

²Departement of Cardiology, Ibnu Sina Padang Hospital, West Sumatra, Indonesia.

Background

ARNI (*angiotensin receptor-neprilysin inhibition*) is a new therapy for the treatment of heart failure with low EF. ARNI can cause ventricular remodeling within 12 months by increasing mean LVEF and clinically decreasing the LVEDV and LVESV indices.

Case Illustration

A 64-year-old female patient came to the emergency room of the Islamic Hospital Ibnu Sina Padang with complaints of shortness of breath since 4 months ago, which had increased since 2 days before hospitalization. Shortness of breath appears when doing moderate activity. The patient also complained of swelling in both legs and claimed to have lost 3–4 kg in one month. The patient had a smoking habit and a history of diseases such as hypertension, diabetes, and dyslipidemia. On Day 2 of hospitalization, therapy with ARB (angiotensin receptor blocker) was replaced with ARNI 2x50mg. The results of echocardiography on January 9, 2021, showed that the global LV systolic function decreased with an EF of 28%. Furthermore, on August 30, 2021, echocardiography showed an increase in EF to 41%. On February 18, 2022, echocardiography showed an increase in EF to 60%. The patient had a history of PCI 1 stent in mid LAD complete revascularization on April 1, 2022.

Conclusion

According to the trial of PARADIGM-HF and the related prospective observational study PROVE-HF, ARNI was presented. ARNIs play a role in remodeling of the ventricles by increasing levels of natriuretic peptides and blocking the effects of angiotensin II.

Keywords: Heart Failure, ARNI, Ejection Fraction, Ventricular Remodeling

Reverse Cardiac Remodeling in Advanced Cardiac Heart Failure Patient

R. Sebastian¹, M. Putra²
¹Department of emergency, Ibnu Sina Padang Hospital, West Sumatra, Indonesia.
²Department of Cardiology, Ibnu Sina Padang Hospital, West Sumatra, Indonesia.

Introduction
ARNI (angiotensin receptor-neprilysin inhibition) is a new therapy for the treatment of heart failure with low EF. ARNI can cause ventricular remodeling within 12 months by increasing mean LVEF and clinically decreasing the LVEDV and LVESV indices.


Case Description
A 64-year-old female patient came to the emergency room of the Islamic Hospital Ibnu Sina Padang with complaints of shortness of breath since 4 months ago, which had increased since 2 days before hospitalization. Shortness of breath appears when doing moderate activity. The patient also complained of swelling in both legs and claimed to have lost 3–4 kg in one month. The patient had a smoking habit and a history of diseases such as hypertension, diabetes, and dyslipidemia. On Day 2 of hospitalization, therapy with ARB (angiotensin receptor blocker) was replaced with ARNI 2x50mg. The results of echocardiography on January 9, 2021, showed that the global LV systolic function decreased with an EF of 28%. Furthermore, on August 30, 2021, echocardiography showed an increase in EF to 41%. On February 18, 2022, echocardiography showed an increase in EF to 60%. The patient had a history of PCI 1 stent in mid LAD complete revascularization on April 1, 2022.

Discussion
In this case, the ARB was replaced with an ARNI. Administration of ARNI, beta-blockers, and mineralocorticoid antagonists is still recommended for the treatment of heart failure with an ejection fraction below 40%. The administration of ARNI has been compared with that of ACEI and ARB. The results can reduce hospitalization rates and increase survival.

Conclusion
According to the trial of PARADIGM-HF and the related prospective observational study PROVE-HF, ARNI was presented. ARNIs play a role in remodeling of the ventricles by increasing levels of natriuretic peptides and blocking the effects of angiotensin II.

Keywords
Heart Failure, ARNI, Ejection Fraction, Ventricular Remodeling

References
1. McMurray JJV, van de乐乐en HJ, Perchutsky A, et al. Angiotensin receptor-neprilysin inhibition versus angiotensin II receptor blockade in heart failure. *N Engl J Med*. 2019;381(10):994-1003.
2. Gheorghiade M, Givertz MM, Givertz MM, et al. Natriuretic peptide therapy in heart failure with reduced ejection fraction: a systematic review and meta-analysis. *Circulation*. 2018;138(10):1171-1180.
3. Gheorghiade M, Givertz MM, Givertz MM, et al. Natriuretic peptide therapy in heart failure with reduced ejection fraction: a systematic review and meta-analysis. *Circulation*. 2018;138(10):1171-1180.



Acute Dyspnea in Young Obese Women with Pulmonary Hypertension Sign. What is Your Immediate Diagnosis?

S.J. Sitorus¹, M.R. Amadis¹

Department of Cardiology and Vascular Medicine, University Airlangga Dr Sutomo Hospital, Surabaya, Indonesia¹

Background Acute pulmonary embolism is a prevalent and potentially life-threatening cardiovascular condition. It may not be easy to immediately diagnose for non-specific clinical presentations that mimic many other common diagnoses. This is a paradox with the availability of effective treatment, which should be started as soon as possible.

Case Illustration A twenty-nine-year-old woman with acute dyspnea was consulted for cardiomegaly finding in a chest x-ray from the pulmonology department with suspected pneumonia in the emergency department. She denies chest pain, immobility, leg swelling, and any medical problem before. Her blood pressure was 102/69 mmHg, heart rate was 98 b.p.m, respiratory rate 30 b.p.m, with oxygen saturation was 78% on ambient air. Her weight was 90kg with a height of 152cm. From physical examinations, we found seems symmetrical leg size. An electrocardiogram (ECG) showed sinus rhythm 93x/' with a sign of right ventricular hypertrophy. Echocardiography revealed pulmonary hypertension signs with right ventricular dysfunction (TAPSE 1,2 cm). We suspicious the possibility of acute pulmonary embolism and relook at the ECG that found S1Q3T3. We take a photo of both legs to evaluate more objectively and found a slightly bigger size on the right side. We perform duplex ultrasonography and found a thrombus of the right femoral vein. We asked for CT-pulmonary angiography confirming a left pulmonary artery thrombus. The patient was taken over to the cardiology department, and anticoagulation was started immediately.

Conclusion We report a case of an unprovoked acute pulmonary embolism in a young obese woman. This patient's absence of classical risk factors and masked led edema make the diagnosis challenging. Bedside echocardiography is valuable in the evaluation of pulmonary hypertension sign. However, a high level of suspicion is critical and clinically relevant so that cases should not be missed.

Keywords: Pulmonary Embolism, Obesity, Woman, Pulmonary Hypertension

ACUTE PULMONARY EMBOLISM AND BIVENTRICULAR THROMBUS IN PERIPARTUM CARDIOMYOPATHY

M.R. Giovanni¹, I.R. Yose², M. Yanni³, M. Syafr⁴, M. Syukri⁵

Cardiology Resident of Cardiology and Vascular Medicine, Andalas University/ DR. M. Djamil General Hospital, Padang, West Sumatera, Indonesia.

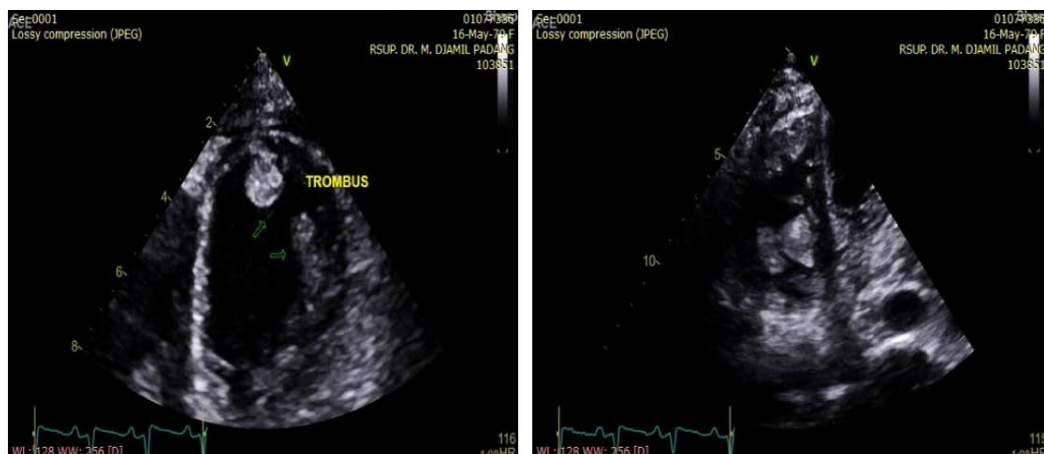
Department of Cardiology and Vascular Medicine, Andalas University/ DR. M. Djamil General Hospital, Padang, West Sumatera, Indonesia.

Background: Venous thromboembolism (VTE) is a common cardiovascular syndrome that presents as deep vein thrombosis (DVT) or pulmonary embolism (PE). Peripartum cardiomyopathy (PPCM) is a rare cardiac disorder that leads to heart failure in the last month of pregnancy or up to five months postpartum. PPCM patients are at an increased risk of thromboembolic complications due to a hypercoagulable state.

Case Illustration: we present a case of a 40-year-old female who presented with acute onset dyspnea and chest pain six weeks postpartum. Echocardiography revealed biventricular thrombi and an acute PE. The patient was started on heparin and thrombolytic and subsequently transitioned to warfarin. She was also started on heart failure therapy with angiotensin-converting enzyme inhibitors, beta-blockers, and diuretics. Follow-up echocardiography showed complete resolution of the thrombi and normalization of left ventricular function. The patient was discharged with recommendations for long-term anticoagulation and close follow-up. PPCM is a rare but serious condition that requires a high level of suspicion for timely diagnosis and management. VTE is a common complication of PPCM that can lead to significant morbidity and mortality. Anticoagulation therapy with heparin followed by oral anticoagulant is the standard of care. The use of thrombolytic therapy should be reserved for patients with massive or sub-massive PE and careful consideration of the potential risks and benefits is required. In addition to anticoagulation, heart failure therapy is also essential.

Conclusion: This case highlights the importance of considering acute PE in the differential diagnosis of dyspnea and chest pain in PPCM patients. A multidisciplinary approach involving cardiology, obstetrics, and hematology is required for the optimal management of these patients. Anticoagulation therapy with heparin followed by oral anticoagulant and heart failure therapy is essential. Follow-up echocardiography is necessary to assess the resolution of thrombi and recovery of left ventricular function.

Keywords: PPCM, Biventricular Thrombus, Pulmonary Embolism



Left figure showing multiple left ventricle thrombus with size 1 cm x 1,2 cm, right figure showing multiple right ventricle thrombus.

A SURVIVING CASE OF RECURRENT LETHAL ARRHYTHMIA IN ADOLESCENT FULMINANT MYOCARDITIS WITH SUSPECTING GNAPS

D.B. Lululangi¹, H.A.K. Cantika¹, L. Dewiyanti², P.R. Dewi³, I.M. Handajaningrum⁴

General Practitioner, KRMT Wongsonegoro State Hospital, Semarang, Indonesia¹

Department of Pediatric, KRMT Wongsonegoro State Hospital, Semarang, Indonesia²

Department of Cardiology, KRMT Wongsonegoro State Hospital, Semarang, Indonesia³

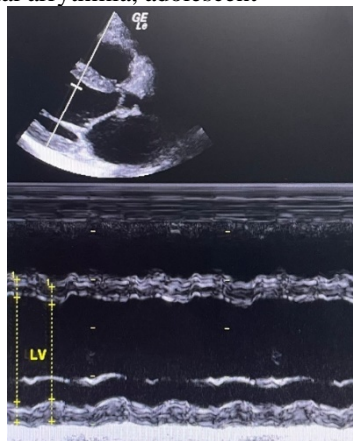
Department of Internal Medicine, Nefrology-Hipertension Subdivision, KRMT Wongsonegoro State Hospital, Semarang, Indonesia⁴

Background: Fulminant myocarditis (FM) is a rare condition of rapidly progressive cardiac inflammation with high mortality profile. Although considered uncommon, arrhythmias may present in FM, leading to sudden cardiac death.

Case Illustration: A 14-year-old female was referred to our emergency department with shortness of breath, cough, and chest pain. The patient also had fever and sore throat five days prior. Physical examination revealed signs of heart failure (HF). Initial blood test showed mild anemia, leukocytosis, electrolyte imbalance, increased levels of serum urea, creatinine, and troponin. Urinalysis findings were in favor of nephritic involvement. Left ventricular dilatation with 30% ejection fraction and severe ventricular wall thickening were confirmed through echocardiography examination, directed to a suspicion of FM. The patient was admitted to the pediatric intensive care unit for further monitoring and received several medications to support cardiac function, treat infection and prevent end-organ damage. Unfortunately, for the next three days the patient experienced several episodes of cardiac arrest and lethal ventricular arrhythmia. Immediate administration of mechanical ventilators, high doses of steroids, continuous antiarrhythmic agents, and inotropics were given during resuscitation effort, followed by return of spontaneous circulation. The patient's clinical condition was dramatically improved, thus allowing the detachment of ventilation support. Our followed-up examination in pediatric ward resulted in resolved HF signs and symptoms with normal resting echocardiography. The patient was discharged on the eleventh day of hospitalization. Outpatient care is undergone for evaluation and assessing the etiology of the disease.

Conclusion: The course of FM is heterogeneous, varying from partial or full clinical recovery in a few days to advanced HF with lethal arrhythmia requiring mechanical circulatory support. Prompt clinical diagnosis and optimal treatment implementation from multidisciplinary approach will be beneficial to avert multiorgan system failure, moreover, increase patient's prognosis.

Keywords: fulminant myocarditis, lethal arrhythmia, adolescent



The patient's echocardiography shows left ventricular dilatation with 30% ejection fraction and severe ventricular wall thickening

Natural Anticoagulants Deficiency Concomitant Silent Atrial Fibrillation in a Transient Ischemic Attack (TIA) Healthy Caucasian Sportaholic Male: A Case Report

A.A. Lukito¹, H. Hutabarat¹, S. Chandra¹, R.A.P. Fernandes¹
Siloam Hospital Lippo Village¹

Background:

Ischaemic stroke is the most common cerebrovascular disease (CVD) which causes a high mortality and morbidity and leads to a disease burden globally. Nevertheless, its incidence in young age is scarce and remarkable. Atherothrombotic diseases are the most common cause of ischaemic stroke, and uncommonly by hypercoagulation disorder. Moreover, atrial fibrillation (AF) as the distinct underlying cause should be also considered.

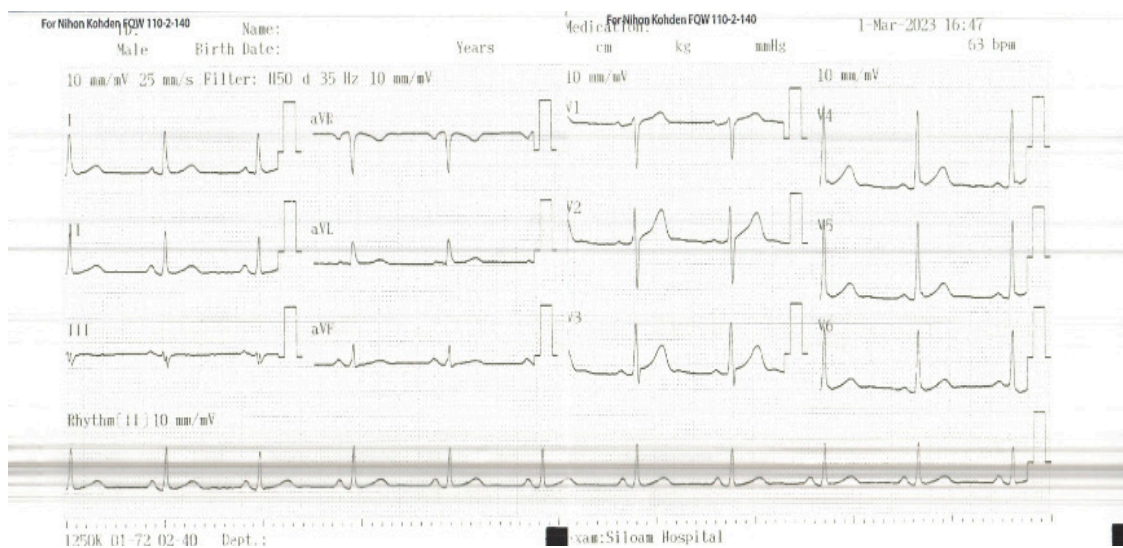
Case Illustration:


A healthy sportaholic 43 years-old Caucasian man without any comorbidity presented to our emergency department with sudden onset of dysarthria and talked incoherently which lasted for a few seconds. Physical examinations revealed BP 104/78 mmHg; HR 71 bpm without any abnormalities. ECG presented was SR with LAE. Laboratory results were in normal limits. Echocardiography showed slight dilated LA, with normal LVEF. MRI/MRA brain and carotid ultrasonography were in normal limits. Diagnostic of TIA and suspicion of AF was confirmed. Further laboratory results showed a protein C and protein S deficiency (36.5 and 57.4), and also an AF on 7 days holter ECG. Oral anticoagulant (OAC) was initiated, and a routine follow-up as well as electrophysiology study with ablation was recommended.

Conclusions:

Due to the low incidence of CVD at young age, therefore a careful and thorough examinations are needed. Suspicion toward silent AF and trombophilic disorders such as protein C, protein S, AT III deficiency, factor V Leiden mutation, antiphospholipid antibodies syndrome, lupus anticoagulant and anticardiolipin should be considered. 7-days holter ECG can be used as a modality in detecting silent AF. OAC should be initiated if a positive result is found.

Keywords: Natural Anticoagulants Deficiency, Atrial Fibrillation, TIA, Young Age





MINOCA Presenting with STEMI: Two Distinct Types and Courses of Takotsubo Syndrome

M.Y. Alsagaff¹, T.T. E. Lusida¹, R.I. Gunadi¹

Faculty of Medicine, Universitas Airlangga – Dr. Soetomo General Hospital¹

Background: Myocardial infarction with non-obstructive coronary arteries (MINOCA) was responsible for some patients presenting with ST-segment elevation myocardial infarction (STEMI). However, many people are unaware that Takotsubo syndrome (TTS) is no longer classified as MINOCA as of the 4th universal definition of myocardial infarction. Furthermore, recognition of atypical TTS (the basal, midventricular, and focal wall motion patterns) has increased in recent years.

Case illustration:

We present two cases of patients who were initially diagnosed with MINOCA but later found to have TTS. Our first case is a classic example of Takotsubo syndrome, based on systolic apical ballooning on transthoracic echocardiography (TTE). Within two days, she made a full recovery. In the second case, TTE revealed an atypical TTS characterized by hypokinesis of the basal segment and reserve of the mid-ventricular and apical segments. He suffered from cardiogenic shock and gradually recovered within 30 days. The international takotsubo (InterTAK) diagnostic score and speckle tracking TTE are two modalities that can be performed rapidly to diagnose TTS. InterTAK score is a scoring model that can differentiate TTS from ACS using all easily obtainable emergency department parameters. Speckle tracing echocardiography has acquired a fundamental role in the evaluation of TTS due to its numerous advantages over the Doppler method, such as early detection of heart muscle damage, angle independence, semi-automatic quantitative analysis, rapid image acquisition, and strain determination without temporal integration, which makes it less dependent on the operator. While higher initial levels of cardiac troponin-I and NT-proBNP are predictors for worse clinical course and slower left ventricle recovery.

Conclusion:

TTS is different from MINOCA. The InterTAK score and speckle TTE are efficient and rapid bedside diagnostic tool for distinguishing TTS from ACS. Higher troponin-I and NT-proBNP levels may be associated with a worse clinical course and slower recovery from LV dysfunction

Keywords: Takotsubo syndrome, MINOCA, Echocardiography

Highlighting The Importance of Assessing Peripheral Stigmata in Early Diagnosis of Infective Endocarditis: A Case Report

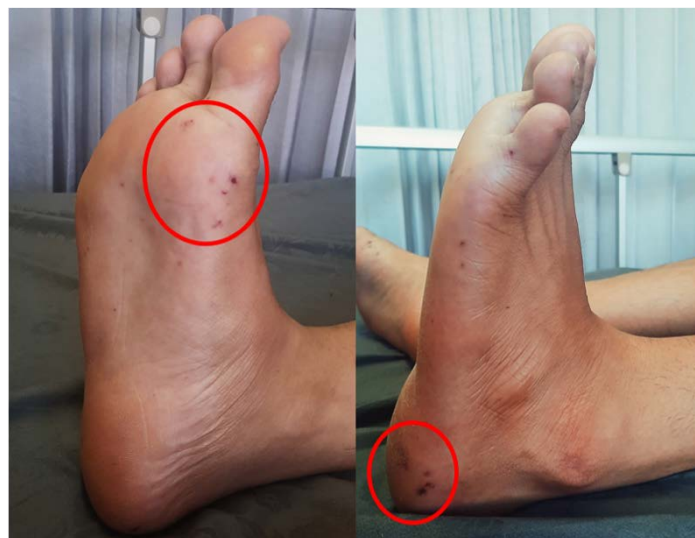T.S. Tartila¹, I.F.A. Putra¹, A.F. Prianda², R. Istisakinah²
General Practitioner, Hasna Medika Kuningan Heart Hospital, West Java, Indonesia¹
Cardiologist, Hasna Medika Kuningan Heart Hospital, West Java, Indonesia²

Background: The diverse spectrum of infective endocarditis (IE) often presents diagnostic challenge that can delay initiation of therapy. A thorough physical examination to assess cutaneous manifestations as classical signs of IE can help in early diagnosis especially at center without advance diagnostic modalities. We report a case of IE with cutaneous stigmata of Janeway lesions.


Case Illustration: A 28-year-old previously healthy man was referred to our hospital with prolonged fever for 2 weeks, chest pain, cough, and myalgia. The patient had already been hospitalized at previous hospital with typhoid fever but showed no improvement. The patient later developed dyspnea and then suspected with acute rheumatic fever. The vital signs were in normal range, but on physical examination we discovered holosystolic murmur near the apex and the presence of irregular, flat, erythematous, and painless macules on the soles consistent with Janeway lesions that led us to the suspicion of IE. The laboratory results showed leukocytosis, renal insufficiency, and elevated titer of ASTO (anti streptolysin O). From chest x-ray we found cardiomegaly and reverse comma sign. The echocardiographic evaluation revealed the presence of vegetation on posterior mitral leaflet and severe mitral regurgitation. The patient met 1 major and 4 minor criteria of Duke Criteria and was classified as definite IE. We diagnosed the patient with IE and concurrent reactivation of rheumatic fever. The patient was treated with intravenous ceftriaxone and gentamycin and recovered well.

Conclusion: Early recognition of peripheral stigmata is important to make early diagnosis of IE. We highlight that dermatologic examination should always be part of physical examination in evaluating the possibility of IE, especially in low-resource settings where diagnosis relies mainly on clinical findings.

Keywords: infective endocarditis, peripheral stigmata, cutaneous manifestations, Janeway lesions, early diagnosis



The appearance of Janeway lesions



SUCCESSFUL RESOLUTION OF TOTAL ATRIOVENTRICULAR BLOCK (TAVB) IN INFERIOR ST-ELEVATION NON REVASCULARIZATION WITH DIABETIC KETOACIDOSIS (DKA) : A CASE REPORT

M. Marpaung¹, D. Krisnawati²

General Practitioner Demang Sepulau Raya Regional Hospital, Lampung, Indonesia¹
Cardiologist Abdul Moeloek General Hospital, Lampung Indonesia²

Background: Total Atrioventricular Block (TAVB) is a common complication of inferior myocardial infarction (MI). An occlusion in the Right Coronary Artery (RCA) can also cause impedance to the cardiac conduction system, such as TAVB. Diabetic Ketoacidosis (DKA) may be the precipitating event for the occurrence of acute MI, serious arrhythmia, and pulmonary edema, while MI is also a well-known precipitant factor for DKA.

Case Illustrations: A 48-year-old woman has typical chest pain accompanied by diaphoresis, syncope, dyspnoea, hypotension, and bradycardia starting 24 hours before admission. She had risk factors for hypertension and Diabetes Mellitus (DM). Electrocardiography (ECG) showed inferior ST-elevation and TAVB. The laboratory found CKMB 69 U/L; hyperglycemic (RBS 512 g/dl), HbA1C 14,8, ketonuria; BGA results of compensated metabolic acidosis; potassium 2.8 mmol/L; creatinine 2,8 mg/dL. Chest X-Ray: cardiomegaly and bronchopneumonia. A temporary pacemaker (TPM) and Percutaneous Coronary Interventions (PCI) cannot be done due to cost constraints. According to unstable hemodynamics, atropine sulfate 1 mg has been given. As an alternative for TAVB, we use dopamine 3-10mcg/kg bb/minute. Initial treatment for MI: oxygenation, DAPT, statin, and UFH 700IU-1000IU/hour. DKA has been treated with saline and insulin resuscitation, metabolic acidosis correction, and antibiotic for infections. After 10 days of treatment, we found ECG evolved from TAVB to 1st-degree AV block and after 14 days of treatment, ECG showed sinus rhythm without TAVB, metabolic acidosis clinically improved, hypokalemia has corrected (potassium: 4.7 mmol/L), and RBS decreased to 141 g/dl.

Conclusion: Hyperglycemia, acidosis, and electrolyte imbalance can directly affect the heart by inducing toxicity, impairing myocardial blood flow, autonomic dysfunction, and altering activation and conduction of electrical impulses throughout the heart, increasing the risk of arrhythmias and ischemia. When DKA is well treated, the arrhythmia in the patient is also resolved.

Keywords: TAVB, inferior ST-elevation, percutaneous coronary interventions, diabetic ketoacidosis.

Lewis Lead: Revelation of the P Wave

A. Laurentius¹, K. Kohar¹, E. Ferdinand¹, S.N. Siagian²
Faculty of Medicine, Universitas Indonesia¹

Division of Pediatric Cardiology and Congenital Heart Disease, Department of Cardiology and Vascular
Medicine, National Cardiovascular Centre Harapan Kita, Universitas Indonesia²

Background: Lewis lead is a method used in electrocardiography in order to magnify the recorded atrial activity in relation to that of ventricles. It values better visualization of P wave in differentiating some well-known arrhythmia, such as atrial fibrillation, atrial flutter, and multifocal atrial rhythm. Correct diagnosis of types of arrhythmia could render optimal treatment.

Case Illustration: We present a case of a 67-year-old Eastern Belitung female who experienced weakness in all extremities while having breakfast two hours before coming to the ER. Her family admits that she was neither aware nor responsive to any call during the event, yet she did not experience syncope. She had uncontrolled chronic hypertension. Her family denied having history of diabetes mellitus, autoimmune disease, and cardiovascular or neurological events, as well as similar past symptoms. During physical examination, her airway was patent, respiratory rate was 19 breaths per minute with oxygen saturation of 96% on air. Heart rate was 59 beats per minute with blood pressure of 130/90 mmHg. Clinically, the patient appeared responsive to pain stimuli but neither speech nor sound with Glasgow coma scale of 13. Her axillary temperature was 37 degrees Celsius. Pulmonary assessment was normal. Cardiac auscultation disclosed slow heart sound with no murmur. Asymmetrical neurological deficit was found in her right arm and leg, as well as slight drooping of right oral commissure with intact forehead strength. Babinski reflex was positive on her right leg. The remainder of physical examination was normal with warm extremities. The electrocardiogram (ECG) showed narrow QRS complexes and irregular R-R interval with no observed P wave. However, slight ECG modification using Lewis lead exhibited coarse fibrillatory P wave, which emphasized diagnosis of atrial fibrillation.

Conclusion: Lewis lead configuration is helpful to prevent misdiagnosis of types of arrhythmia with poor P waves visualization.

Keywords: Lewis lead, P waves, Electrocardiography

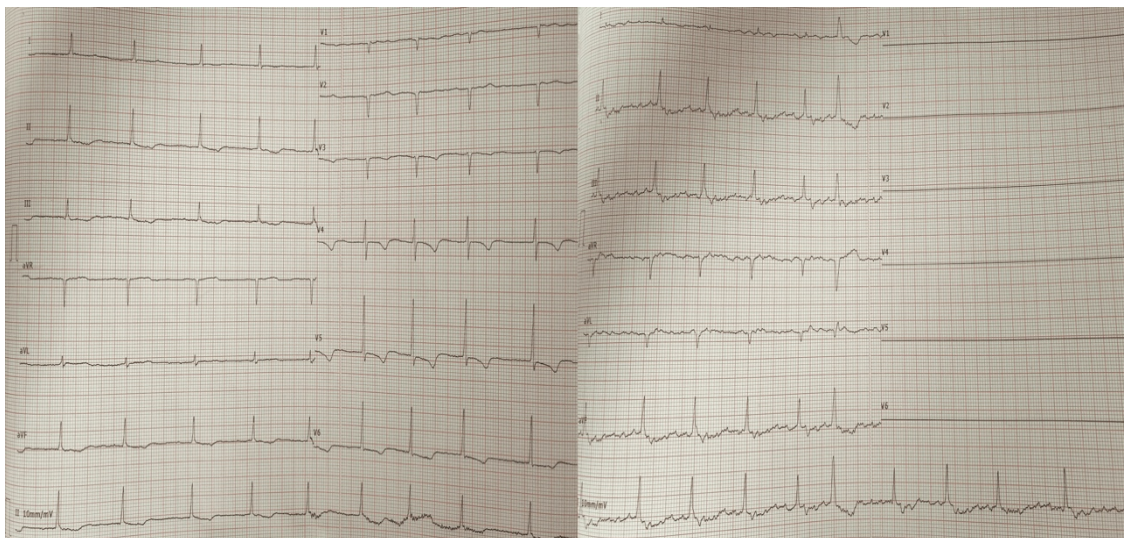


Figure 1. Electrocardiography findings with classic 12-lead configuration (left) and Lewis lead configuration (right).

Atrial fibrillation in barlowish mitral regurgitation: a burden that never end

A. Firmansyah¹, C.K. Krevani²

Cardiology and Vascular Medicine Residency, Andalas University, Padang, West Sumatera.¹
Cardiology and Vascular Medicine Department, M. Djamil Hospital, Padang, West Sumatera.²

Background

Atrial fibrillation (AF) is the most common arrhythmia and associated with an adverse prognosis. Mitral regurgitation (MR) is of particular interest regarding the development of AF because MR is common particularly in elderly and tends to produce left atrial (LA) enlargement, high risk precursor of AF. We report a rare case barlowish type mitral regurgitation who had presented with AF.

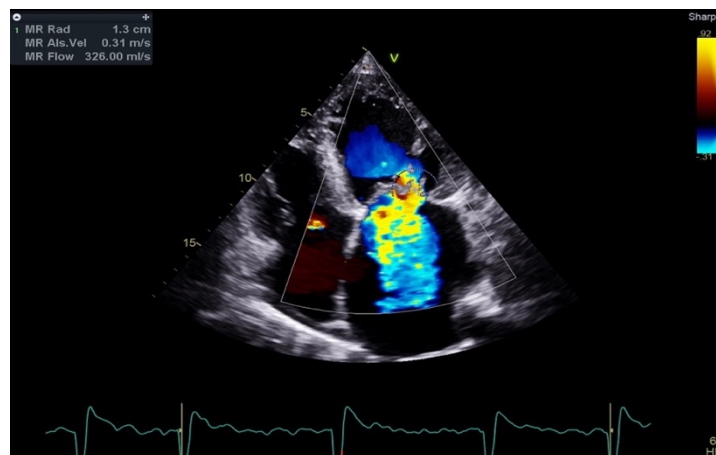
Case Illustration


A 62 years old male presented with palpitations and shortness of breath in emergency room (ER). Patient had history of congestive heart failure from 3 months before with poor compliance to take medicine. His blood pressure was 140/90 mmHg and heart rate was 130-140x/min. Pansystolic murmur grade 3/6 at apex radiating to axilla was found in patient. ECG showed AF with rapid ventricular response. Transthoracic echocardiography showed bileaflet myxomatous mitral valve degeneration barlowish type with severe MR while in AF, LA size was 77mm, with EF 56% and good right ventricular function. Amiodarone intravenous was administered leading to control rhythm but AF still persistant with controlled in rate. The diuretics, anticoagulant, and optimal heart failure medicine was administered in high care unit. The Giant LA indicated the chronic process from MR severe in patient with poor compliance, that make AF became persistant as complicating burden of MR. After multidisciplinary evaluation, he was offered mitral valve repair, however he elected for medical management only.

Conclusion

The case highlights an important mechanism of MR which can be noted in AF patient. Poor compliance make MR and AF became a vicious cycle that increased morbidity to patient.

Keywords: Atrial fibrillation, mitral regurgitation, barlowish disease





The Challenge and Modification Towards Cardiovascular Rehabilitation Program on Post PCI Patient with Permanent Pacemaker: A Case Report

D.Pasahari¹, D. Sarvasti², F.A. Wardani¹, M.E. Saputra¹, A.D. Lamara³
Airlangga University¹
Widya Mandala Catholic University²
University of Airlangga³

Background

The cardiovascular rehabilitation program is eligible for patients who have undergone cardiovascular intervention to improve cardiovascular function and quality of life. This program is also beneficial for patients with a permanent pacemaker (PPM), which have slight modifications for the physical training.

Case illustration

A-67-Years-Old-Women previously diagnosed with non-ST-segment elevation myocardial infarction (NSTEMI) with bradycardia, underwent Percutaneous-Coronary-Intervention, and PPM implantation was referred to our facility. Single-chamber PPM positioned at right ventricle, with 60-pace per minute. The patient had hypertension, diabetes, and dyslipidemia. At the first visit, the patient's blood pressure was measured 110/70mmHg. Electrocardiogram recorded pacemaker rhythm 75-bpm, left-axis-deviation, and left-bundle-branch-block. Chest X-ray suggests cardiomegaly, and echocardiography shows left-ventricle-diastolic-dysfunction-grade-III. The 6-minute walk test (6-MWT) presented Metabolic Equivalents (METs) of 3.30, resembling the patient's exercise capacity. In every session, the patient undergoes moderate-intensity exercise, consisting of flat-track walking and a static bike. The difficulty increases with increasing progression. Training modifications for patients with PPM have specific instructions, regulating target heart rate and aerobic activities within limitation, having a preferred BORG Scale of 11-13.


At the 12th appointment, a stress test using a modified Bruce protocol is usually performed. Due to patient complaints of knee pain, and leg fatigue, the stress test is replaced with 6-MWT, showing the increment in patient's METs to 3.87, with no chest pain and shortness of breath complaints during training. Based on the psychological questionnaire, the patient feels more confident and happier after the program.

Conclusion

Cardiovascular rehabilitation programs, especially physical training, differ slightly for patients with PPM. However, the program could still improve patient quality of life physically and psychologically.

Keywords

Cardiovascular rehabilitation, metabolic equivalent, percutaneous coronary intervention, permanent pacemaker, 6-minute walk test.



Rapid Degradation of Left Ventricular Function after Permanent Right Ventricular Pacing in Patients with High-Grade Atrioventricular Block

D. Setiawan^{1,2}, A. Rizal^{1,2}, I. Prasetya^{1,2}

¹Department of Cardiology and Vascular Medicine Faculty of Medicine Universitas Brawijaya, ²Dr. Saiful Anwar General Hospital

Background:

Permanent right ventricular pacing (RVP) is a standard treatment for high-grade atrioventricular (AV) block. Still, it may cause abnormal ventricular activation, which results in an inefficient myocardial contraction pattern due to ventricular dyssynchrony and may lead to left ventricular (LV) dilatation, systolic dysfunction, and heart failure (HF). Chronic and high-burden RVP can cause pacing-induced cardiomyopathy (PICM) that may occur several months or years after permanent pacemaker (PPM) implantation. We describe a case of a PICM with a significant decrease in LV systolic function in less than two years after PPM implantation. Coronary angiography showed widely patent vessels and subsequently, His-Bundle pacing (HBP) was scheduled on the patient.


Case Illustration:

A 56-year-old Asian female with a history of PPM (VVIR mode) implantation due to a high degree AV block was transferred to our hospital with a diagnosis of acute decompensated heart failure (ADHF). On arrival, she looked restless and had difficulty breathing, with a respiratory rate of 25 tpm and a body temperature of 39 degrees Celcius. Physical examination showed bilateral leg edema, and rhonchi were heard bilaterally. Laboratory tests revealed a white blood cell count of 33.760 /mm³ with 84% neutrophils, and NT pro BNP level was 9.233 pg/L. An electrocardiogram (ECG) showed atrial flutter with ventricular pacing rhythm 60 bpm RVOT origin. Chest x-ray revealed pulmonary edema, infiltrates, and cardiomegaly with a single lead PPM seen at RVOT. Evaluation of her PPM showed good condition with 99.5% RV pacing. Her echocardiogram showed all chamber dilatation, global hypokinetic, and reduced ejection fraction (EF) from 62% to 26% in less than two years. Coronary angiography was performed, which showed non-significant coronary artery stenosis with 20% stenosis at distal LAD. After three days of antibiotics and decongestive treatment, her complaints of fever, bilateral leg edema, and shortness of breath resolved. His-Bundle pacing (HBP) was scheduled to reduced LV dyssynchrony and improve LV function.

Conclusion:

Single-chambered pacemakers create ventricular dyssynchrony, which can cause structural and molecular changes leading to cardiomyopathy. With early intervention, these changes can be reversible. Therefore, timely check-ups and awareness are necessary for patients on PPM.

Keywords: Atrioventricular Block, Right Ventricular Pacing, Pacing-induced Cardiomyopathy



Successful Fibrinolysis on a Cardiac Arrest Survivor Following Ventricular Tachycardia due to STEMI in Toraja Utara

F.J. Tandirerung¹, Y. Iskandar¹
RS Elim Rantepao Hospital¹

Background. Cardiac arrest (CA) following ST-elevation myocardial infarction (STEMI) is associated with a higher mortality rate. Percutaneous Coronary Intervention (PCI) is crucial in lowering the mortality rate in such cases. However, PCI might not be accessible for hospitals in peripheral regions, leaving fibrinolysis as the only feasible option. Furthermore, prolonged/traumatic resuscitation is a relative contraindication for fibrinolysis, complicating the fibrinolysis decision for the post-resuscitation CA survivor. Here we present a case of successful fibrinolysis in a CA survivor secondary to STEMI in Toraja Utara.

Case Illustration. A 66-year-old patient was admitted to the emergency room (ER) due to typical chest pain 30 minutes prior to hospital admission. The pain was described as heavy, radiating to the left shoulder, with diaphoresis and shortness of breath. The patient was a smoker with a history of hypertension. At the ER, the patient had a seizure, which was followed by CA. Cardiopulmonary resuscitation (CPR) was performed, followed by defibrillation due to ventricular tachycardia. Following a 5-minute CPR with defibrillation, the patient returned to spontaneous circulation, fully conscious with stable hemodynamics. A 12-lead electrocardiogram (ECG) assessment was carried out that showed ST-elevation on leads V1-V3, therefore assessed and treated as STEMI. However, the nearest PCI center is approximately 400 kilometers (8 hours) away in Makassar. Hence, fibrinolysis with streptokinase was selected for initial reperfusion and the patient was discharged after six days of hospitalization with no neurological or cardiopulmonary complications. The patient refused PCI referral during the hospitalization period and was only referred months later with favorable clinical outcomes.

Conclusion. Despite reperfusion through PCI remains the stronger survival predictor in STEMI with CA, successful reperfusion with fibrinolysis is attainable with timely intervention following CPR. This is clinically substantial, especially in peripheral areas with difficult access to PCI.

Keywords: STEMI, Fibrinolysis, Cardiac Arrest

A 42-Year Old Male Patient with Wellen's Syndrome: A Rare Case Report

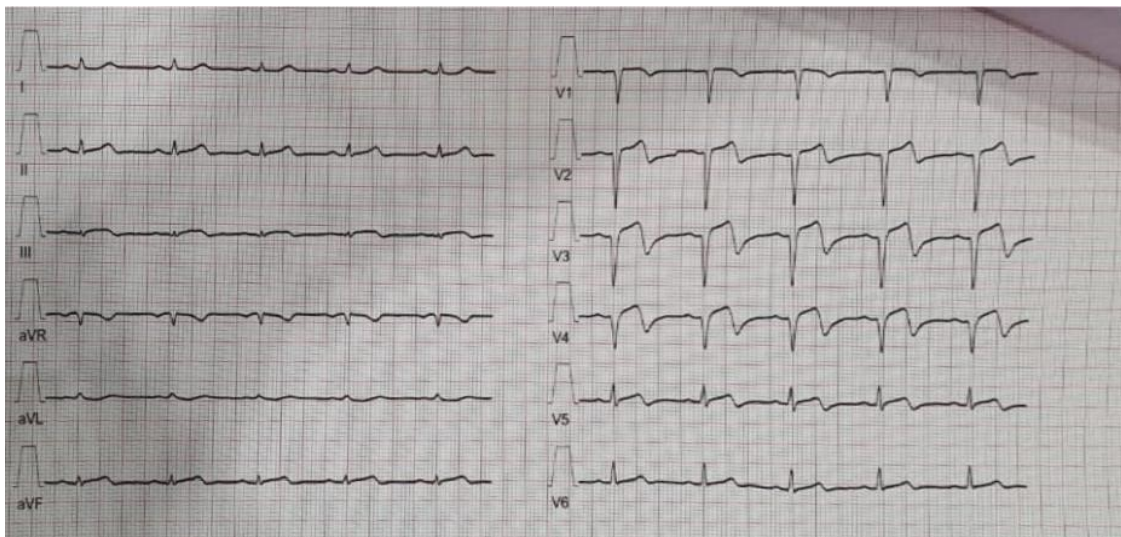
M.F.A. Akbar¹, Y.B. Saragih¹
Aceh Tamiang General Hospital¹

Background: A characteristic electrocardiogram (ECG) pattern of T-waves in the precordial leads that were associated with a critical stenosis (>90%) of the proximal left anterior descending (LAD) coronary artery was described in 1982 by Wellens. Wellen Syndrome (WS) criteria include T-wave changes in precordial leads, plus a history of anginal chest pain without marked serum marker abnormalities and Q-waves.


Case Illustration: A 42-year-old male patient came to the emergency ward with intermittent moderate chest pain and shortness of breath over a few days. The patient has a history of smoker and uncontrolled hypertension. A history of the same symptoms was found, and misdiagnosed several times. The initial vital sign depicted 160/90 blood pressure and ECG displayed slight ST depression on V1-V5 lead. T-troponin was normal on initial finding. He was hospitalized and conducted ECG serial. At the pain-free, ECG displayed biphasic t wave on leads V2-V5, specific for Wellen's Sign. He referred and an angiography study showed mid stenosis 90% on the left anterior descendent artery with the consecutively reduced coronary flow. The patient is treated by drug-eluting stent implantation and angioplasty.

Conclusion: Wellen's syndrome is a life-threatening case characterized by abnormal T-waves found on ECG. The ECG changes during pain relief. In our case, the patient presents with biphasic T-wave on anterior leads after being pain-free, on this point, it is crucial to conduct an ECG serial. Therefore, the physician should be aware of recognizing ECG features to help identify high-risk patients who require immediate invasive strategy. An invasive strategy is a cornerstone of the therapy to make a good prognosis.

Keywords: Keywords: Myocardial infarction, T-wave abnormality



ST-segment elevation with biphasic T wave in lead V2-V5



Facing Junctional Bradycardia with Cardiogenic Shock Case in ER : A Case Report

P. Yeantesa¹, N.A. Byant¹, S.D. Utami¹
Awal Bros Panam Hospital¹

Background: Sinoatrial node is a default pacemaker in human's heart, they trigger electrical activity, so the heart can beating. In some cases, someone's heart using atrioventricular node to make rhythm, one of their rhythm is junctional bradycardia, this rhythm has rate below 60 bpm. This rhythm can decrease heart pumping and blood supply to the heart cells, so somebody can fall into cardiogenic shock.

Case illustration: 54-Year-Old patient came into ER with feeling weakness and have no energy since 3 days before admission. Ten days before admission, she started felt nausea, then vomited until she didn't know how many times it happened. Before that, she went to the clinic and checked peripheral blood, the result is she had anemia and trombositosis. She had diabetic mellitus type 2, hypertension heart disease, aorta regurgitation, atrial fibrillation, congestive heart failure. On physical examination, we obtained BP 88/55 mmHg, HR 44 bpm and pulse was so weak, RR 20 x/min, afebrile and SpO₂ 93% room air, conjunctival pallor, crackles(+), other examination were normal. Twelve leads ECG showed junctional bradycardia (44 bpm), echocardiography showed EF 66%, Global N, LVH+, MR mild, AR mild. She also had anemia, renal insufficiency, hyperkalemia and hyponatremia. In ER, twelve ampoules of atropine sulfate is just administered, but heart rate still between 40-50 bpm, so that, dopamine is administered, the normal rate and blood pressure is just achieved and then she transferred to HCU.

Conclusion: Electrolyte imbalance such as hyperkalemia make biphasic effect for cardiac: action potential being short, the conduction getting faster, but in the end, this conduction being slowly and induce junctional bradycardia. As bradycardia running, our heart doesn't ability to pump enough blood to the whole body and person would fall into condition like cardiogenic shock.

Keywords: Junctional Bradycardia, Hyperkalemia, Cardiogenic Shock

Apical Hypertrophic Cardiomyopathy Mimicking Acute Coronary Syndrome Presentation: What is the Important Clue?

M. Reeiner¹, L.O.S. Suastika², N.M.A.W. Sari², I.B.R. Wibhuti²

¹Faculty of Medicine, Udayana University, Denpasar, Indonesia;

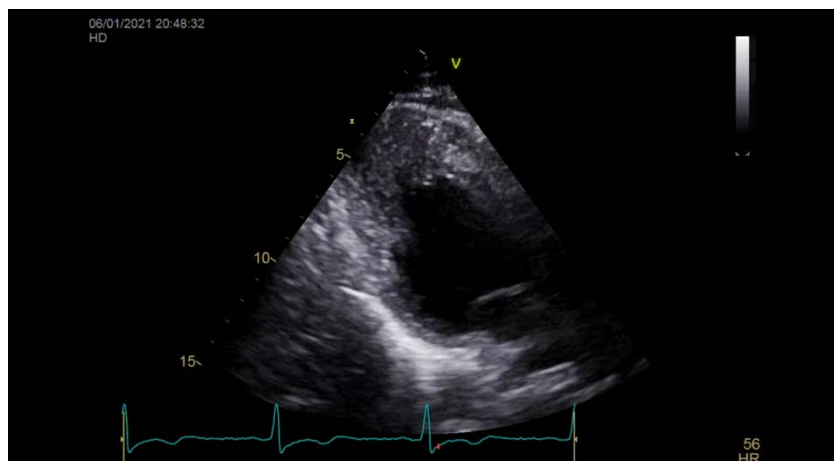²Sanglah General Hospital, Denpasar, Indonesia

Background: Apical hypertrophic cardiomyopathy (ApHCM) is a rare variant of hypertrophic cardiomyopathy, characterized by a spade-like left ventricular cavity, and more commonly seen in the Asian population. The electrocardiographic changes and symptoms associated with apical hypertrophic cardiomyopathy often mimic acute coronary syndromes. Distinguishing between these conditions was important to determine early and definitive treatment.


Case Illustration: A 56-year-old man came to our emergency room with severe chest pain three hours after the onset of symptoms. His chest pain was induced by physical activity but persisted at rest. Similar symptoms had occurred prior to the current event, he had done coronary angiography several years ago and the result was normal. His medical history was hyperlipidemia and family history of hypertension. His cardiac enzymes were not elevated. The electrocardiogram showed giant negative T wave inversion in the lateral precordial leads (V2–V6, I, and aVL). As a result of the typical symptoms of unstable angina pectoris, electrocardiographic repolarization disturbances indicative of acute myocardial ischemia, and his cardiovascular risk profile, the decision was made to carry out cardiac catheterization. Coronary angiography excluded significant coronary artery disease. However, echocardiography demonstrated a typical spade-like configuration of the left ventricular (LV) cavity. The wall thickness of the apical septal regions and the apical posterior region was 16 mm and 18 mm, respectively, and systolic LV function was normal. Apical myectomy was deferred in this patient and beta blocker was our first choice of treatment.

Conclusion: ApHCM can mimic the symptoms and electrocardiographic changes of acute coronary syndromes and should be considered as a differential diagnosis, especially in patients with giant T wave negativity, normal cardiac marker and spade-like configuration of the LV cavity. Echocardiography of the apical segments, and CMR is helpful in establishing the diagnosis of ApHCM.

Keywords: Apical hypertrophic cardiomyopathy, acute coronary syndrome, giant T wave inversion, echocardiography



Lower extremities bilateral post thrombotic syndrome



Challenging STEMI with Ventricular Tachicardia Case in ER : A Case Report


R.P. Putra¹, S.D. Utami¹, N.A. Byant¹
Awal Bros Panam Hospital¹

Background: of the ACS cases ended in Cardiac Arrest. The presence of myocardial ischemia due to reduced coronary blood flow will cause the myocardium to become necrotic (myocardial infarction). In addition to myocardial infarction, ischemia can also cause myocardial contractility disorders. The occurrence of myocardial infarction will cause disturbances in the conductivity of the heart's electricity which often triggers the occurrence of malignant arrhythmias. However, not all types of ACS can trigger malignant arrhythmias, depending on the location of the infarction.

Case Illustrations: 53-Year-Old patient presented into ER with left chest pain since 7 hours before admission. 30 minutes before admission, he complained of palpitations. He had uncontrolled hypertension and a smoker. On physical examination, we obtained BP 80/60 mmHg, HR 242 bpm, RR 20 x/min, SpO₂ 97% room air with normal in other general physical examination. 12-lead ECG showed inferior STEMI with Ventricular Tachicardi, echocardiography showed EF 53% concentric LVH, Coronary Arterial Disease anterior, good valve. He also had renal insufficiency and hyperglykemia in type 2 DM is newly recognized. In ER, he got heart loading, dobutamine drip and also amiodarone drip until he was transferred to the ICU.

Conclusion: Myocardial Infraction can cause serious complications, one of which is malignant arrhythmia. It can even lead to cardiac arrest.

Keywords: STEMI, Ventricular Tachicardia, Malignant Arrhythmia



Ventricular Tachycardia During Balloon Atrial Septostomy in a Neonate with TGA: A Rare but Life-Threatening Complication

A. Yudha¹, A. Priyatno²

Department of Cardiology and Vascular Medicine, Faculty of Medicine, Diponegoro University – Dr. Kariadi Central General Hospital, Semarang, Indonesia¹

Department of Pediatric, Faculty of Medicine, Diponegoro University – Dr. Kariadi Central General Hospital, Semarang, Indonesia²

Background :

Ventricular tachycardia is a rare but potentially life-threatening complication that can occur during balloon atrial septostomy procedures in neonates. In this case report, we describe the management of a term neonate with complete transposition of the great artery (TGA) who developed ventricular tachycardia during a balloon atrial septostomy procedure.

Case Illustration :

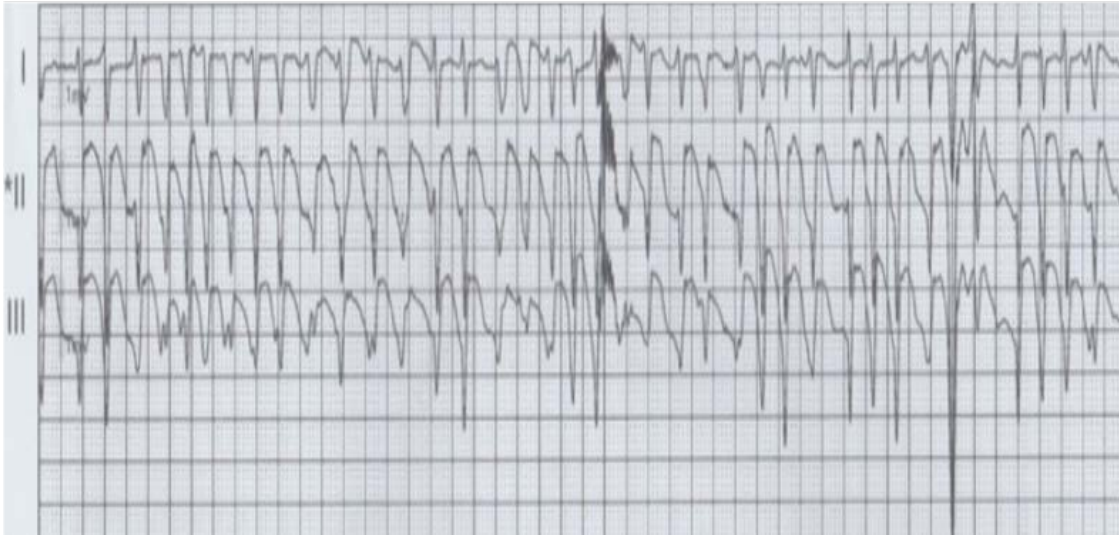
A 4-day-old male neonate who was diagnosed with complete TGA shortly after birth. Balloon atrial septostomy was planned as a palliative procedure to improve the patient's oxygenation. During the procedure, the patient developed ventricular tachycardia, which was initially managed with anti-arrhythmic medications. However, the patient remained hemodynamically unstable, and electrical cardioversion was required to restore normal sinus rhythm.

Following the cardioversion, the patient's rhythm stabilized, the septostomy was successfully completed, and there was an improvement in oxygen saturation from 50% to 80%. The patient ultimately made a full recovery and was discharged from the hospital with stable cardiac function. The occurrence of ventricular tachycardia during balloon atrial septostomy is a rare but serious complication that requires prompt recognition and management. In our case, the prompt recognition of the arrhythmia and the immediate administration of anti-arrhythmic medications and electrical cardioversion were crucial in stabilizing the patient's condition. With timely and appropriate intervention, such as anti-arrhythmic medications and electrical cardioversion, the patient's condition can be stabilized and the procedure can be successful.


Conclusion :

In conclusion, ventricular tachycardia during balloon atrial septostomy in neonates is a rare but potentially life-threatening complication that requires immediate recognition and management. This case report emphasizes the potential for ventricular tachycardia during balloon atrial septostomy in neonates with transposition of the great arteries and emphasizes the importance of prompt recognition and management of this rare but potentially life-threatening complication. With timely and appropriate management, the outcome for neonates with this complication can be favorable.

Keywords: balloon atrial septostomy, transposition of the great artery, ventricular tachycardia, neonates



Ventricular Tachycardia occur during BAS procedure



Arrhythmias in Leptospirosis, too fast or too slow; a case series

T. Pramitasari, S. Fatimah, A.E. Satuti¹
RSUD Kota Yogyakarta¹

Background

Leptospirosis is a zoonotic disease with significant morbidity and mortality. Although infrequent, leptospirosis can affect the heart. Some cardiac manifestations are arrhythmias to myocarditis, pericarditis, endocarditis and cardiogenic shock. Electrocardiographic changes are not specific and may resolve after clinical recovery.

Case illustration

Case-1: A 70 years-old male came to ER complaining fever, nausea and vomiting frequently for 3 days. He had low blood pressure, oliguria, conjunctival suffusion and gastrocnemius pain on examination. The laboratory test showed leukocytosis, thrombocytopenia, increased level of urea and creatinine. The electrocardiogram was atrial fibrillation normal ventricular response. Hours later, he suffered from general seizure and serial electrocardiogram showed atrial fibrillation slow ventricular response with sinus pause. He was treated accordingly with temporary pacemaker.

Case-2: A 52 years-old male came to ER complaining difficulty of breathing and diarrhea. He had history of fever for 4 days. He had low blood pressure, tachycardia (the heart rate was 148 bpm) and gastrocnemius pain. The laboratory findings were thrombocytopenia, elevated urea and creatinine level. The electrocardiogram showed atrial flutter with variable conduction. Amiodarone as antiarrhythmic drug was given to control the sepsis-related tachycardia.

These two patients had evidence of acute kidney injury and reactive antibody of *Leptospira*, were treated by antibiotics, serial hemodialysis and vasopressor for maintaining the blood pressure. As the improving leukocyte count, urea and creatinine blood test on day 7, the heart rate was getting better. Temporary pacemaker for case-1 was removed on day 9 and amiodarone for case-2 was no longer used on day 8. The patients were significantly improved and discharged by day 12 and 11.

Conclusion

Leptospirosis can affect the heart manifesting various range of arrhythmia. Physician should be aware of cardiac involvement because the symptoms are not specific due to co-existence with multi-organ dysfunction.

Keywords

Arrhythmia, Leptospirosis

Keywords: Arrhythmia, Leptospirosis

Infective Endocarditis in 18-year-old Male Adolescents

P.G. Fernandez¹, L. Tiluata¹
Prof Dr. W. Z Johannes Hospital, Kupang¹

Background

Infective Endocarditis is an infection of the endocardial lining of the heart that includes heart valves, mural endocardium, and endocardial covering of the implanted material.¹ Based on the modified Duke criteria, a definitive infective endocarditis requires two major criteria, or at least one major plus three minor criteria.² Positive blood culture results and endocardial damage detected by echocardiography provide the strongest evidence for the diagnosis of infective endocarditis and are considered the major criteria. Up to 90% of patients present with fever, often associated with systemic symptoms of chills, poor appetite and weight loss. Heart murmurs are found in up to 85% of patients.³ Infective endocarditis has a mortality rate of 20-25% at six months, even when treated appropriately.

Case Illustration

An 18-year-old male admitted to the emergency room at Prof. Dr. W. Z. Johannes Hospital with chief complaint of fever for more than a month, accompanied by shortness of breath. Accordingly, He was firstly treated by a pulmonologist with suspicion of pneumonia. But, heart murmurs was also found, He was than referred to cardiologist with suspicion of rheumatic heart disease. Blood culture showed the growth of *Staphylococcus aureus* bacteria. Echocardiography showed, moderate mitral regurgitation, tricuspid regurgitation, left ventricular dilatation and vegetation on the valve. He than got antibiotic therapy : Gentamicin, Levofloxacin, and Erythromycin, and symptomatic therapy.

Conclusion

A case of an 18-year-old male, diagnosed as Infective Endocarditis with echocardiography showed vegetation on the heart valve. The patient has been given antibiotic specifically sensitive to the blood culture. Surgery is the further option of therapy, so the patient was referred to another facility.

Keywords: Infective endocarditis, vegetation, fever

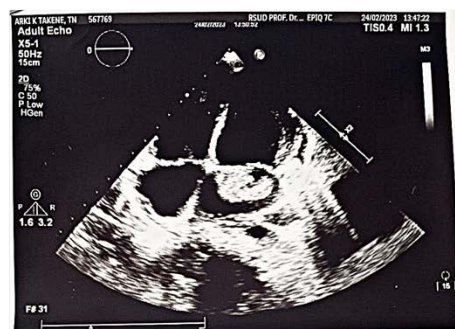

Figure 1. Echocardiography showed vegetation on the heart valve.

Troubleshooting A Permanent Pacemaker Lead Dislodgement in Patients with Persistent Left Superior Vena Cava

M. Reeiner¹, I M.P.S. Antara²

Faculty of Medicine Udayana University¹,

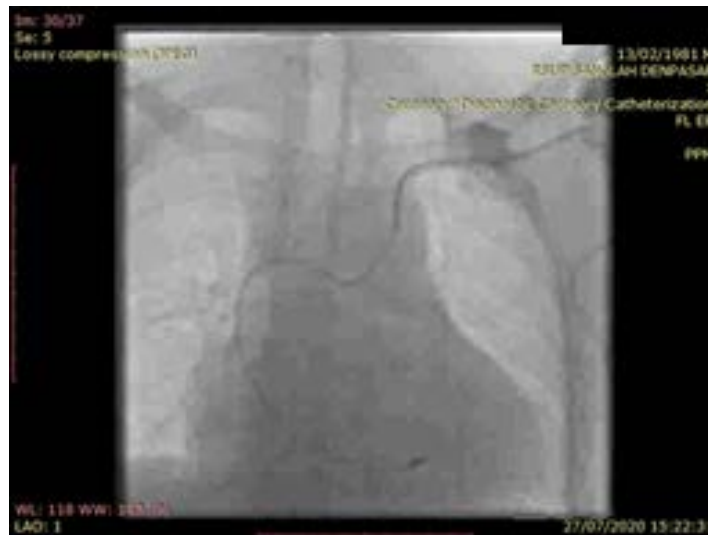Electrophysiology Division of Department of Cardiology and Vascular Medicine Prof. I.G.N.G. Ngoerah Hospital Bali²

Background: Persistent left superior vena cava (PLSVC) is often discovered incidentally during cardiac imaging or at the time of implantation of a cardiac implantable electronic device. It can be challenging because of the sharp angle between the subclavian vein and the PLSVC and, extreme angle that exists between the CS and the tricuspid valve. This anatomy not only makes right ventricular (RV) lead implantation difficult but also predisposes to lead dislodgement.

Case Illustration: A 40-years-old man came for routine control and permanent pacemaker reprogramming. The patient's initial complaint was that he almost fainted few times in the last six months. This situation was felt when the patient was on the road trip, felt like dark and almost fainted lasted for a few seconds. Complaints of chest pain, tightness, palpitations, nausea, and vomiting were denied by the patient. A permanent single chamber VVIR pacemaker was installed a year ago. Placement of the ventricular leads was difficult because PLSVC was found on venographic examination, but finally it could be done through PLSVC. The result of last reprogram was output 4.5 mA with pulse with 0.76 ms, and impedance 522 ohm with intermittent pacing rhythm. The battery voltage was 0.76 V with battery life estimation 3 years. Permanent pacemaker repositioning was carried out by trying to reposition the leads using a stylet wire, but failed, so it was decided to extract the lead and install a permanent pacemaker through the right SVC with access to the right subclavian vein.

Conclusion: Technical problems are often encountered using standard technique in patient with PLSVC, therefore alternative approaches have been developed. For this reason, a thorough evaluation of the venous system is required in PLSVC patients prior to re-intervention of the pacemaker system to reduce the risk of further complications.

Keywords: Persistent left superior vena cava, permanent pacemaker, lead dislodgement



Lower extremities bilateral post thrombotic syndrome

Not too old to be Closed: Transcatheter ASD Closure in Elderly Using Zero Fluoroscopy Technique, First Experience in North Sulawesi

C. Kurniawan¹, G. Soemara¹, Subiyanto¹, G.P. Lumentut¹, J.A. Pangemanan¹, A.L. Panda¹, G.E.H. Reppi¹,
M.P.F. Rotty¹, R. Prakoso², R. Ariani²
RSUP Prof RD Kandou Manado¹

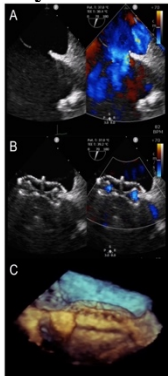
National Cardiovascular Center Harapan Kita, Department of Cardiology and Vascular Medicine, University of Indonesia²

Background: Transcatheter closure of secundum type atrial septal defect (ASD) has emerged to be a preference compare to conventional surgical methods, given its non-inferiority. Echocardiography guided Transcatheter ASD closure without fluoroscopy has become more popular worldwide. Hereby, we present a case report on the first successful ASD closure with zero fluoroscopy technique in Manado.

Case Illustration: 69 years old female complains dyspnea worsening for the last 3 months. TTE (transthoracic echocardiography) showed 20 mm ASD with L-R shunt, enlarged right heart chamber with good RV function, high probability of pulmonary hypertension with normal LV function. The patient was treated for her PH (Pulmonary Hypertension) and sent to the Cath Lab for evaluation. A diagnostic right heart catheterization revealed pulmonary and systemic blood flow ratio (Qp:Qs) was 1.66 and PVR 3.9 woods unit, thus ASD closure is safe to be performed. Pre-procedural TEE (Trans Esophageal Echocardiography) revealed secundum 14-16 mm secundum ASD with L-R shunt, adequate rims, and mild tricuspid regurgitation. Transcatheter ASD closure with zero fluoroscopy technique was planned. The procedure started with insertion of 5F MP catheter through 5F sheath in the right femoral vein, directed into LUPV (left upper pulmonary vein) under TEE guidance. Cera ASD occluder was engaged to 10 F delivery sheath to be delivered into LA (left atrium) after crossing the RA (Right atrium). Then, LA disc was deployed first followed by RA disc later. Wiggle test was done to confirm the device rest in stable position. Post-procedural TEE documented the device was successfully placed without any residual shunts or complications. Evaluation within 12 weeks reveal successful closure of interatrial communication, device *in situ*, preserved LV function, and improvement of patient's symptoms.

Conclusion: Transcatheter closure of secundum ASD with zero fluoroscopy in elderly is feasible, safe, and improving symptoms.

Keywords: transcatheter ASD closure, zero fluoroscopy



Refusing Surgery for Chronic Type A Aortic Dissection: A Bold Choice or a Gamble with Life?

I.P. Farissa¹, A.Z. Abidin¹, N. Anggriyani¹, M.A. Sobirin¹

Department of Cadiology and Vascular Medicine, Faculty of Medicine Diponegoro University, Semarang¹

Background

Stanford Type A aortic dissection is a rapidly progressing disease process, often fatal without emergent surgical repair. A small proportion of Type A dissections go undiagnosed in the acute phase and found delayed presentation or incidentally. An increasing number of acute phase survivors and outlive initial hospitalization for many years. Late complications, driven predominantly by chronic false lumen degeneration and aneurysm formation, often require surgical, endovascular, or hybrid interventions to treat or prevent aortic rupture.

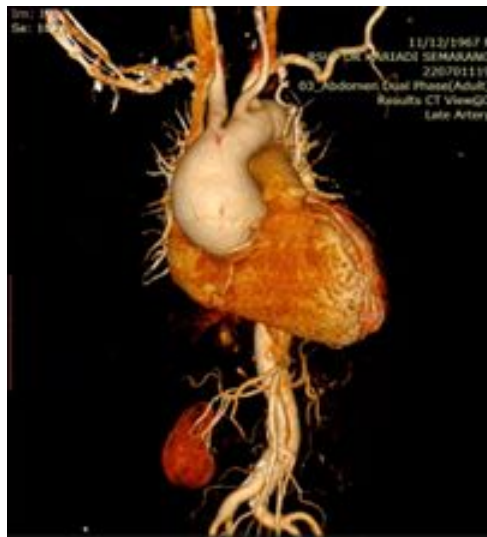Case Illustration

A 54-year-old woman complained sharp chest pain penetrated her back 3 hours before admission. Physical examination showed different right and left pressure 95/56 mmHg right and 147/63mmHg left, pulse 120x/minute, SpO2 93%, and fine crackles in both lung fields. Her past medical history was long standing aortic dissection and severe aortic insufficiency since June 2018. Echocardiography showing flap dissection of the ascending aorta with moderate to severe aortic regurgitation, LVEF 64%. The patient was diagnosed with Stanford A aortic dissection from cardiac MSCT. She refused for surgical procedure and continued medical therapy. MSCT evaluation in July 2022 showed Stanford A Debackey I aortic dissection without contrast extravasation, dissection of the right common carotid artery and left subclavian artery, thin thrombus in the false lumen of the ascending aorta. The patient was given intravenous diuretics to reduce congestion, and optimize medical therapy due to refusal of surgical therapy.

Conclusion

Type A aortic dissection patients who are undiagnosed in the acute phase may become Chronic Type A Aortic Dissections (CTAD), that prone to additional dissection, enlargement, aneurysmal dilatation, rupture, and death. In patients who refuse surgery or non-surgical interventions, it is a medical challenge to prevent re-hospitalization, improve quality of life and reduce risk of death.

Keywords: Aortic Dissection, Heart Failure, Aortic Regurgitation



MSCT

Reverse Spider View for hidden occlusion in ostial Left Anterior Descending Artery : Case Series with a comprehensive review

D.A.K. Purba¹, A. Sitepu²

Faculty of Medicine, Universitas Sumatera Utara, Medan, Indonesia¹

Department of Cardiology and Vascular Medicine, Faculty of Medicine, Universitas Sumatera Utara, Medan, Indonesia²

Background: Bifurcation of the Left Main Coronary Artery (LMCA) is a complex area where occlusion in the vessels may not be visible on a single projection, including Spider View, due to the foreshortening effect. The Reverse-Spider view, oriented with Right Anterior Oblique (RAO) 90°- 120° and Hyper Cranial Angulation (CR) 30°- 40°, is a rarely used angiographic angle that has the potential to unravel occlusions.

Case Illustration: We present five cases diagnosed as Anterior ST Elevation Myocardial Infarction (STEMI). Routine ECG and laboratory examinations, including cardiac enzymes, were carried out with CK-MB level $104 \pm 77,002$ U/l, and the medial Troponin-T level was 1280 (40 - >2000) ng/L. All patients planned for Percutaneous Coronary Intervention (PCI). In angiography, we compare Reverse Spider View to Spider View and other routine projections to evaluate LMCA and its bifurcation. The reverse-spider view could diagnose sub-occlusive lesions and total occlusion in ostial Left Anterior Descendent (LAD) that were not previously seen or obscured in Spider View. After PCI, an echocardiographic examination was performed with an average Ejection Fraction of $46,60 \pm 10,52\%$. All patients were discharged from the hospital in good condition.

Conclusion: Reverse Spider View is good at detecting a hidden occlusion in the bifurcation area of LMCA, providing a clearer view of the ostial and proximal parts of the Left Anterior Descendent (LAD), Left Circumflex (LCx), and Intermediate Branch. The reverse-spider view is also recommended when the Spider view or other projection results seem dubious to diagnose an occlusion.

Keywords: Reverse Spider View, Ostial Left Anterior Descendent, Coronary Artery Disease, Percutaneous Coronary Intervention, Angiography

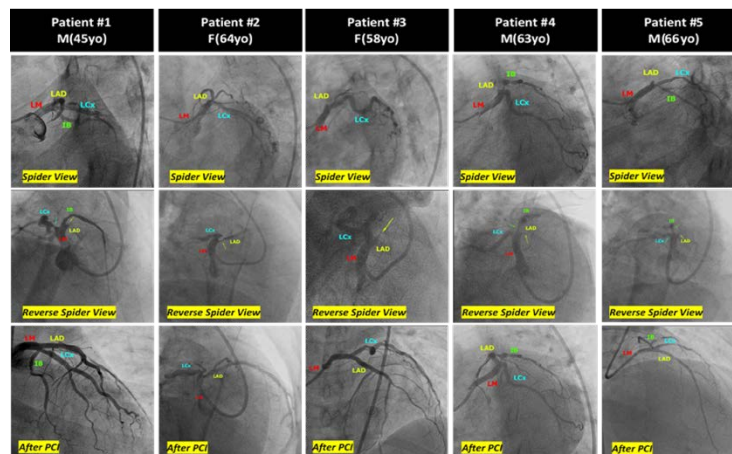


Figure 1. Comparison of Left Stem Coronary Angiography Evaluation in 5 patients; LM = Left Main Artery; LAD= Left Anterior Descending Artery; LCx= Left Circumflex Artery; IB= Intermediate Branch



Case Report : Alcoholic Cardiomyopathy with LV Thrombus in Young Adult Patient

F. Ladediska¹, V. Rosady¹, M. Syafri²

¹Cardiology Resident, ²Cardiologist dr.M Djamil Hospital

Background

Alcoholic cardiomyopathy (ACM) is a cardiac disease caused by chronic alcohol consumption. The major risk factor for developing ACM is chronic alcohol use. ACM is characterized by increased left ventricular mass, dilatation of the left ventricle, and heart failure (both systolic and diastolic). Left ventricular thrombus (LVT) is a serious complication of acute myocardial infarction (MI) and also of non-ischemic cardiomyopathies.

Case illustration

A 22 year old patient came to the Emergency Departement of dr. M Djamil hospital with worsening shortness of breath since 1 day ago. The patient smokes and drinks alcohol since 10 years ago. Physical examination found JVP: 5+2cmH₂O, cor: cardiomegaly was found on palpation, pansystolic murmur grade 3/6 at RIC III LLSB, extremity warm and no oedema. Laboratory found normal liver function, moderate hypokalemia (2.9), hyperbilirubinemia. CXR showed cardiomegaly. The ECG showed sinus rhythm with LVH. Echocardiography revealed LV EF 27%, eccentric LVH, hypertrophied with restrictive disorders LV diastolic dysfunction, mild MR, moderate TR, intermediate probability PH, sec(+) in LV, multiple thrombus (+) apical. Patient was diagnosed with ADHF w/w on CHF ec susp alcoholic cardiomyopathy, Multiple LV thrombus, TR moderate high probe PH, Mild hypokalemia, Susp Community Acquired Pneumonia. Patients were given furosemide 40 mg iv followed by drip furosemide starting at 3 mg/hour, correction of KCL 35 meq and KSR 3x600 mg, Uperio 2x50 mg, spironolactone 1x25 mg, warfarin 1x4mg, Lansoprazole 1x30mg IV, laxantia 1x10mg and consulted to the lung department. The patient was discharged after being hospitalized for 6 days.


Conclusion

Anamnesis, physical and supporting examinations, especially TTE, are needed to establish the diagnosis of ACM. LVT is one of the serious complications of ACM to be aware of.

Keyword

Alcoholic cardiomyopathy, thrombus, young adult

Keywords: Alcoholic cardiomyopathy, Thrombus, young adult



A RARE AND CHALLENGING CASE TO CONTROL: HEMORRHAGIC TRANSFORMATION STROKE DURING THE ACUTE PHASE OF MYOCARDIAL INFARCTION: A Case Report

Y. Afifah¹, A.Y. Suprpta¹, A.F. Rahimah¹, C.T. Tjahjono¹
Rumah Sakit Saiful Anwar, Malang¹

Background

In patients with STEMI who underwent percutaneous coronary intervention, DAPT and an anticoagulant have been recommended. However, antithrombotic therapy was also associated with an increased risk of hemorrhagic stroke or intracranial hemorrhage. Although it only occurs in 0.3% of patients receiving DAPT, intracranial hemorrhage has serious consequences.


Case Illustration

45 years old male, suffered from heavy like sensation chest pain and syncope. He had risk factor of hypertension and was an active smoker. 10 months ago, he has sluggish accompanied with weakness of the left limb but improved by itself. From physical examination the BP 160/92mmHg with HR 90bpm and ictus cordis was displaced without any murmur or gallop. ECG examination showed ST elevation at V1-V4, biphasic T in leads V2-V5, Inverted T at I, AVL, and QS pattern at III, AVF, V1-V4. The level of cardiac troponin rose from 0.6 to 2.2. With a crusade score of 40, he received loading DAPT and LMWH injections, underwent PPCI with result Acute Total Occlusion at mid LAD then implanted 1 DES Cre8 3.0x16mm. The patient experienced a general motor onset tonic-clonic seizure on the second day of treatment. A CT scan revealed a subacute CVA with hemorrhagic transformation and an NIHSS score of 5. The patient's DAPT and anticoagulant were stopped. For patients who underwent PCI, some studies advise restarting DAPT within one month of the ICH to reduce the risk of stent thrombosis.

Conclusion

One of the uncommon side effects for patients who received DAPT is hemorrhagic stroke. For some high-risk patient subsets, such as those who have had a previous stroke or TIA, the risk of ICH associated with DAPT must be carefully considered. Physicians may use risk prediction scores to outline this trade-off, which can improve the process of making decisions together with patients who are at high risk for bleeding.

Keywords: Acute myocardial infarction, CVA hemorrhage, Anticoagulant, Antiplatelet, DAPT



Important Roles of Early Loading DAPT and Fibrinolytic on STEMI Patients in Non-Capable PCI Hospital: Case Series

P.N. Permatasari¹, I. Handirosiyanto²

General Practitioner, Baptis Batu Hospital, Malang, Indonesia¹

Cardiologist, Baptis Batu Hospital, Malang, Indonesia;Karsa Husada Hospital, Malang, Indonesia²

Background: STEMI is life-threatening. The longer ischemic time increases morbidity and mortality in patients. It's time-critical to recognize STEMI and decide to manage the patient with pharmacological or mechanical reperfusion. From the onset of ECG patients with ischaemic symptoms interpreted as STEMI, PCI must be done within 120 minutes, if longer, immediate fibrinolysis and transfer to PCI Centre if indicated.

Case Illustration: We describe 2 cases of typical chest patients with ST-segment elevation on ECG. Case 1: A 44-year-old man was referred from Primary Healthcare Centre with typical chest pain, nausea, and vomitus within 1 hour, ECG-12 leads showed STMI Inferior and got DAPT before being referred to ER. He had uncontrolled Hypertension. In ER, BP: 159/96 mmHg, HR: 83 times/minute without congestion or pulmonary edema. ECG showed no elevation ST-Segment. Thrombocyte aggregation was autolyzed by DAPT.

Case 2: Women, 53 years old, came to ER with typical chest pain within 1 hour. She had controlled HTN. BP: 110/80 mmHg, HR: 60 times/minute. ECG showed STEMI inferior. The patient got DAPT and a fibrinolytic agent, then transferred to ICU. After 2 hours, ECG showed successful fibrinolytic.

Conclusion: Time is muscle. Early reperfusion by pharmacological therapy is needed if access to PCI Centre is longer than 120 minutes from the first diagnosis of STEMI. Loading DAPT and DAPT with Fibrinolytic made an important role in each case.

Keywords: autolysis, DAPT, reperfusion, STEMI, fibrinolytic

Unusual Case of Critical Limb Ischemia as a Complication of Blood Culture Negative Infective Endocarditis in Children: A Rare but Serious Condition

A. Alamsyaputra¹, S.Y. Pradana¹, I.P. Farissa¹, A. Priyatno²

¹Faculty of Medicine, Diponegoro University – Dr. Kariadi Central General Hospital,
Semarang, Indonesia

²Department of Pediatric, Faculty of Medicine, Diponegoro University – Dr. Kariadi Central
General Hospital Semarang, Indonesia

Background:

Blood Culture Negative Infective Endocarditis (BCN-IE) is a type of Infective Endocarditis (IE) characterized by lack of growth of bacteria or other microorganisms in blood cultures. One of IE complication are Embolic Events (EE) which caused by migrating cardiac vegetations. The incidence of EE ranged from 20-50%, and 6% happen in peripheral artery.

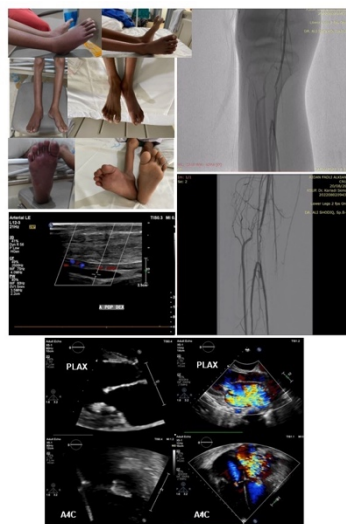Case illustration:

A 10 years old boy admitted to hospital with exertional dyspnea and orthopnea. He was indolent, low-grade fever, distended abdomen, and swollen legs. Pansystolic murmur was heard at the apex and Chest X-Ray showed left atrial and left ventricle cardiomegaly. Echocardiography revealed severe mitral insufficiency with vegetation at the posterior mitral leaflet. Blood culture was shown negative, but based on Clinical Criteria on Modified Duke Criteria he graded as Definite IE and managed with empirical antibiotics for a month. Half year after antibiotics, he developed right leg claudication, reddish, and swelling. Doppler Ultrasonography showed no flow from popliteal to tibialis anterior and posterior artery, no thrombus was seen. Arteriography was performed and shown total occlusion at proximal tibialis artery with collateral vessel filled the distal part unto pedis. Embolectomy was performed and revealed occlusive, crushed artery at the distal femoral arteries. Repair the damaged arteries was done afterward.

Conclusion:

Multiple clinical series have shown that the risk of EE decreases generally to 10-15%, within 1 week after initiation of appropriate antibiotic therapy. In BCN-IE no pathogen was isolated in blood cultures or in other specimens (embolism, valve tissue), so choosing treatment regimen can be difficult. Empiric antimicrobial therapy can be started and epidemiologic features of each case should be evaluated to assist broader coverage in defining treatment regimen. We also have to distinguish BCN-IE with Non-Bacterial Thrombotic Endocarditis caused by systemic lupus erythematosus, antiphospholipid syndrome or malignancy so we can treat the underlying cause.

Keywords: Infective Endocarditis, Peripheral Arterial Disease, Embolic Event



A Simplified Technique Ductal Stenting in A Complex Duct-Dependent Pulmonary Circulation Infant: The Transfemoral Venous Shortcut

A. Alamsyaputra¹, I.P. Farissa¹, M. Helthayana¹, A. Yudha¹, A. Priyatno²

¹Faculty of Medicine, Diponegoro University – Dr. Kariadi Central General Hospital, Semarang, Indonesia

²Department of Pediatric, Faculty of Medicine, Diponegoro University – Dr. Kariadi Central General Hospital Semarang, Indonesia

Background:

Transcatheter Patent Ductus Arteriosus (PDA) stenting currently an acceptable palliative treatment in newborns suffering from duct-dependent pulmonary circulation requiring neonatal repair or palliation with a secure source of pulmonary blood flow until more definitive surgery can be performed. This procedure remains technically a challenge in complex ductal morphology, which may eventually lead to detrimental outcomes with a failure rate of 16-20%.

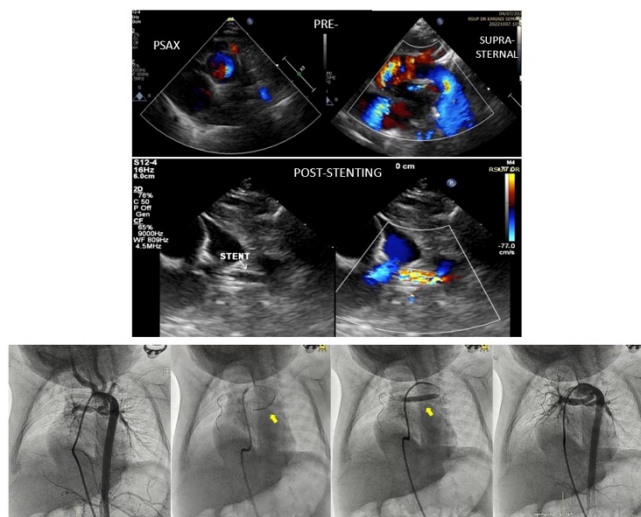
Case illustration:

A 3 months old girl admitted to hospital with cyanosis and shortness of breath. She appeared to be under weight, rapid breathing and bluish with the saturation is 64% room air. Continuous machinery murmur was heard on the left infraclavicular area. Transthoracic Echocardiography showed PA-VSD (Fallot Type), PFO and a vertical duct PDA under the aortic arch. We performed catheterization procedure through femoral vein, MPA2 catheter successfully passed through from IVC, RA, RV to the distal of aortic arch via Ventricular Septal Defect. Aortography was performed and revealed a long tortuous vertical duct PDA \varnothing 11 mm under the aortic arch with stenosis at the proximal part of RPA and LPA. There was no MPA. Wire crossed through the PDA to distal of RPA using JR3.5/4F catheter and a 4.0 x 19 mm DES was successfully deployed. The peripheral saturation increased to 88%. Later Unfractionated Heparin was given for two consecutive days and switch to acetylsalicylic acid the day after. There were no complications afterward.

Conclusion:

Ductus arteriosus morphology and location influences technique and determines complexity, safety, duration, and final outcome of ductus arteriosus stenting.² In PDA with very proximal origin, a stable position of the Judkin's right catheter tip in the PDA can be accomplished by the antegrade transvenous route, across the VSD and into the ascending aorta, however, negotiating multiple angles and curves in the PDA may still be cumbersome and arduous procedure.

Keywords: PDA, PDA stenting, Pulmonary Atresia, Duct-Dependent Pulmonary Circulation



Multiple Culprit Lesion in A Patient with ST-Segment Elevation Myocardial Infarction: A Double Trouble Rare Case Report

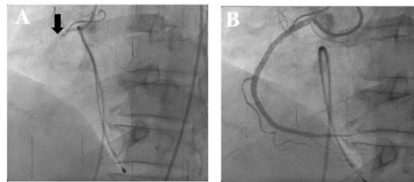
S. Andrian¹, W. Erlanda¹, M. Prasetya¹, C.K. Krevani¹, M. Syukri¹, S. Phalguna¹
Universitas Andalas, Padang/RSUP Dr. M. Djamil Padang¹

Background: The reported incidence of multiple thrombotic coronary occlusions reached 50% in an autopsy series of patients who died from sudden cardiac death and occur in about 4,8 % of the cases, suggesting that the incidence is low in clinical practice because most of the patients die before medical contact. Although for the most part, this occlusion involves a single coronary artery, simultaneous thrombotic occlusions in multiple coronary arteries in the setting of STEMI are rare, and poorly understood.

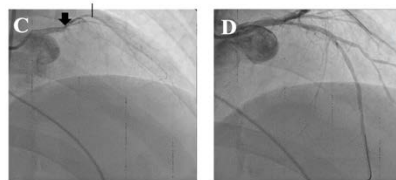
Case Illustration: A 57 years old man came to the emergency room of Dr. M Djamil Hospital with typical chest pain 11 hours before admission. The pain scale was 6/10. The patient also complained of fainting for less than 1 minute while in chest pain, then soon recover. The patient was compos mentis with BP 87/60 mmHg, HR 36 x/min regularly, SO₂ 98 % on room air. The ECG revealed TAVB with ST elevation at lead II, III, aVF, V1-V4, V3R-V4R, and V7-V9. Troponin-I was increased (14.499 ng/mL). The patient performed TPM and continued to primary PCI. The angiography result was CAD 2VD with total occlusion at proximal LAD and proximal RCA and normal LM, LCX. The patient continued with PCI then stented DES 3,0x46 mm at ostial-mid RCA, POBA at ostial-distal LAD with residual stenosis at proximal-distal LAD, TIMI flow 3 MBG 3. After being hospitalized for 6 days, the patient was discharged in stable condition.

Conclusion: Simultaneous thrombosis of the coronary artery in the course of AMI is an uncommon entity. A step-by-step approach in decision making about device utilization and pharmacotherapy, in adherence with the most recent and widely accepted guidelines, alongside a flexible interventional strategy, is crucial in effectively managing such complex and unusual cases.

Keywords: Multiple thrombotic coronary occlusion, PCI




(A) Right coronary artery occlusion, (B) Final angiographic result after stenting of the right coronary artery



(C) Left anterior ascending (LAD) coronary artery Occlusion, (D) Final angiographic result after POBA of the left anterior descending coronary artery

Coronay Angiography



Brugada in Elderly, What Should We Do?

I.V. Nugroho¹, A.F. Rahimah²
Fakultas Kedokteran Universitas Airlangga¹
RS Saiful Anwar²

Background

Brugada syndrome (BrS) is a rare autosomal-dominant inherited arrhythmic disorder characterized by coved-type ST-segment elevation with negative T wave in the right precordial leads ECG pattern without structural heart disease. Patients with Brugada syndrome are at risk for sudden cardiac death (SCD) due to ventricular arrhythmia with predominantly occur in men (5.5-fold risk) compared with women. The mean age of patients with ventricular arrhythmia episodes is 26-56 years old. Arrhythmic events observed at rest or while asleep with most frequently occur from 12 am to 6 am, and the least frequent occur during the daytime. It can be asymptomatic for life or present with syncope (range from 17 to 42%) in some patients.

Case Illustration

We present a 65 years-old woman with typical chest pain at rest in early morning (03.00 am) with ST-segment elevation in the right precordial leads (V1-V3) Brugada pattern. Patient with risk factor of uncontrolled diabetes mellitus type II, from laboratory examination we found a hyperglycemic state with FBG 227, RBG 302, and HbA1C 7.7. History of syncope or cardiac disease was denied. Serial ECG and cardiac enzyme examination was no resolution in ST-segment and no alternation in cardiac enzyme. From DCA examination was found a stenosis 20-30% at proximal RCA. Calculation on Shanghai Score System was 3.5 score, with conclusion possible Brugada Syndrome. Because there was no clinical criteria in this patient, we conclude the patient with asymptomatic Brugada pattern type 1. Patient was being closely monitoring and advised to do EP study to stratify the possibility of ventricular arrhythmia events in the future.

Conclusion

Patient with asymptomatic Brugada pattern type 1 could be advised to do close follow up and do EP study to stratify the possibility of ventricular arrhythmia events in the future without any medication therapy.

Keywords:

Cor triatriatum dextra: A rare disease with a common presentation

T.Y. Nugraha¹, A. Rizal¹, C.T. Tjahjono¹
saiful anwar hospital¹

Background

Cor Triatriatum Dextra (CTD) is a rare congenital cardiac anomaly which can be found in adults and should be considered as a differential diagnosis when patients present with atrial tachycardia and heart failure. Although it is rare, there has been an increase in diagnosis due to developments in diagnostic imaging techniques. Echocardiography has an important place in the diagnosis of congenital pathologies in this rare group.

Case Illustration

A 25-year-old female patient was admitted to our hospital with the complaint shortness of breath was accompanied by palpitation. On physical examination, There were rales in the lung basals by auscultation. There was an apical 2/6 systolic murmur on cardiac auscultation. Blood pressure was 128/76 mmHg, respiratory rate was 32/ min and pulse was 180/ min. 12-lead ECG revealed atrial tachycardia with intermitten WPW. Ejection fraction was normal in transthoracic echocardiography. Left atrium and right atrium were large. Transthoracic echocardiography revealed moderate mitral regurgitation, mild tricuspid regurgitation. In addition, a fibromuscular membrane dividing the right atrium in two, compatible with the CTD was observed in the right atrium. Cardiac magnetic resonance imaging and multiclice computed tomography were recommended to determine additional congenital anomalies and to determine the need for surgery. Surgical treatment was recommended for the treatment of CTD because of symptomatic valvular diseases and the need for additional cardiac surgery.

Conclusion

Although CTD is a very rare congenital anomaly in the society, the development of diagnostic methods has increased the diagnosis of this anomaly. Symptoms and signs of right heart failure and supraventricular arrhythmias are common in this anomaly. The present case demonstrates the use of different modalities to evaluate CTD; each modality has its own limitation. In most cases, more than one diagnostic imaging modality is necessary to come to a definitive conclusion.

Keywords: Keyword : Cor Triatriatum Dextra, Atrial Tachycardia

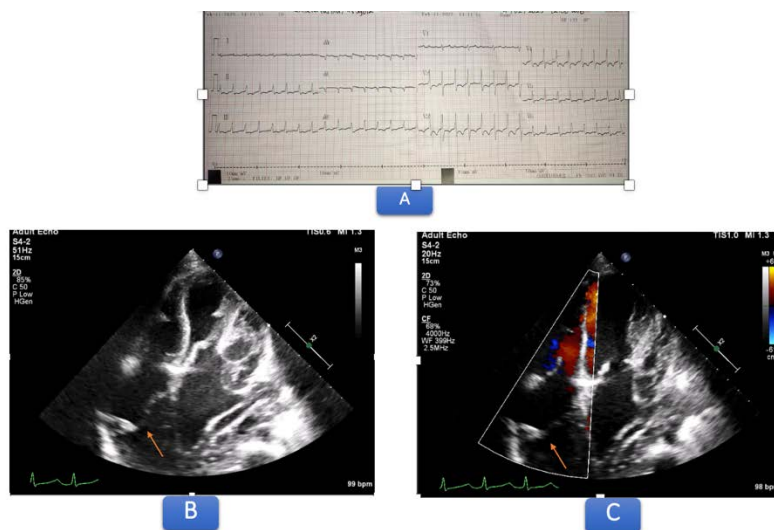



Figure A. ECG at dr. Saiful Anwar Hospital showed atrial tachycardia with intermitten WPW, Figure B and C TTE Showed a fibromuscular membrane dividing the right atrium



Severe Mitral Regurgitation (MR) due to Chronic Rheumatic Heart Disease (RHD) with Increase in Pulmonary Arterial Pressure : How to treat conservatively?

J.E. Yulianto¹, A.K. Syammarhan¹
RSUD Inche Abdoel Moeis Samarinda¹

Background : RHD is a sequel of ARF resulting from an abnormal immune response to GAS infection that triggered valvular damaged. MR is the most common valvular abnormality at the early RHD stages, associated with ongoing inflammatory rheumatic activity and may resolve with effective treatment of the acute carditis and continued prophylactic therapy. In the late time course, MR is often associated with stenosis owing to intrinsic valvular lesions like fibrosis with retracted leaflets, restricted mobility and commissural fusion. According to ESC guideline, valve surgery is indicated in patient with persisting severe MR and symptoms. But the most problem in Indonesia, especially in Samarinda, patients often refused to do surgery, so the Cardiologist should do improvisation for an optimal medical therapy without surgery.

Case Illustration: Mrs.E, 34th years old, come to the ER with her chief complain is shortness of breath, PND, Orthopneu and swelling in abdomen. She was diagnosed with VHD during her first pregnancy in 12 years ago. Since childhood, she often experienced fever, sorethroat, with joint swelling. Physical examination show normotensive, takipneu, irregular pulse, raised JVP, rheels in bilateral lungs, holosystolic murmur in apex, and ascites. Laboratory findings normal limit, except increase of ASTO titer (800 IU/mL). ECG shows AF RVR and RVH. Chest X-ray shows RAH, RVH, with pulmonary oedema. Echo results EF 49% with all chambers dilatation, severe MR (MR ERO 1,3 cm²) with SEC in LA, and severe TR. MV characteristic fit to definite RHD: MR seen in all view, jet length ≥ 2 cm, velocity 4,20 m/s, chordal thickening and restrictive leaflet motion. She refused to do surgery, so we treat conservatively with triple diuretic, ACEi, BB, Anticoagulant, and GAS Eradication with erytromycin.

Conclusions: RHD and severe MR patient who refuse to do surgery need a strategy for optimal medical therapy.

Keywords: severe MR, RHD, optimal medical therapy

STEMI WITH COMPLETE SPONTANEOUS RESOLUTION OF ST-ELEVATIONS AND CLINICAL SYMPTOMS: FRIEND OR FOE

V. Mayangsari¹, N. Kurnianingsih¹, C. Kahadi¹
Brawijaya University - Saiful Anwar General Hospital¹

Background:

ST Elevation Myocardial Infarction still become an emergency condition and need perform primary PCI in PCI Centre. However, we also see patients who present with significant ST-elevations on the initial electrocardiogram but show complete spontaneous resolution of ST-elevations and clinical symptoms. This clinical condition is referred to as 'transient STEMI' and is reported to occur in 6% of all patients presenting with acute coronary syndrome. Early invasive strategy was a procedure that perform for this case. We describe a case of a Transient STEMI which perform early invasive strategy.

Case Illustration:

A 48-year-old Asian male come to ER dr. Saiful Anwar General Hospital with typical chest pain, with VAS 9/10, and 6 hour onset. He was an active smoker more than 20 years old. He in hemodynamic without support, with BP 100/60, HR 71bpm, RR 18tpm, SpO2 97%. At First Medical Contact (FMC) onset 1,5 hours, we found ST Elevation in Lead II (3mm), III (2.5mm), aVF (4mm); ST depression in lead V1-V4, aVR, I, aVL (reciprocal). He got Loading ASA 320mg from FMC, then at 3 hours onset his chest pain was release with VAS 2-3/10 then perform ECG again, that ST Elevation got resolution without ECG evolution. From laboratory, Troponin I level 1,9 (onset 6h), 4,6 (onset 10h) then 1,6mcg/L (onset 16h). He performs an early invasive strategy and did not any significant lesion with TIMI Flow 3 in all Coronary Artery, unlike other cases with significance lesion. He got heparinization, then after four days of care his chest pain was relieved and discharged in good condition.

Conclusion:

ST-elevations with complete spontaneous resolution of ST-elevations and clinical symptoms is still be happen in patient with acute coronary syndrome. Early invasive strategy should be performed, although its significance or not significance lesion in coronary artery for definite treatment.

Keywords:

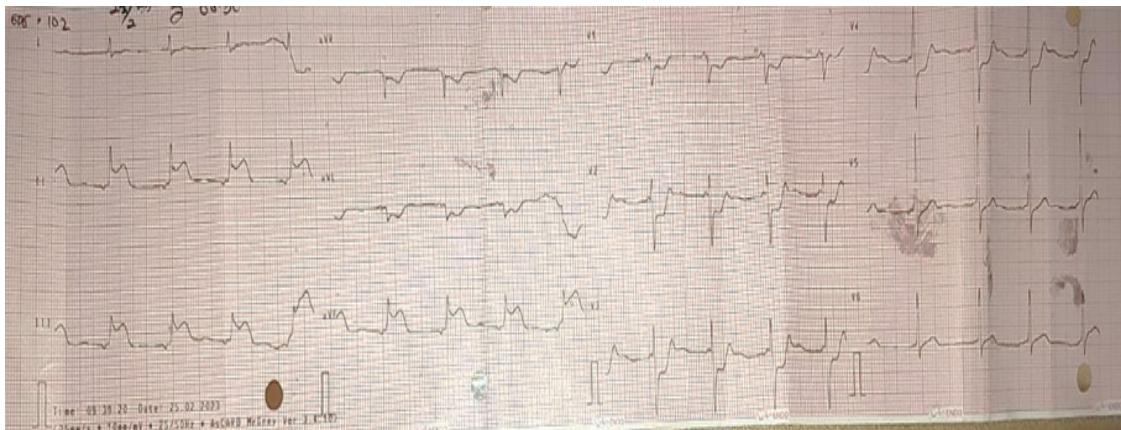


Figure 1. ECG at 1,5 hours onset

BRASH SYNDROME IN SECUNDUM ATRIAL SEPTAL DEFECT: LOST IN PLAIN SIGHT

S. Manurung¹, A.R. Pratama¹
Sultan Suriansyah General Hospital¹

Background :

Bradycardia, Renal failure, AV-Nodal blockers, Shock, Hyperkalemia Syndrome (BRASH syndrome) is fundamentally a synergistic process created by a combination of hyperkalemia and renal failure synergizes with AV-nodal blockers, consequently between the clinical condition of patients with the degree of hyperkalemia and bradycardia are inappropriate. Therefore, rapid diagnosis and management of this entity are crucial to reduce mortality. We report a case and the management of BRASH syndrome in the Emergency Department.

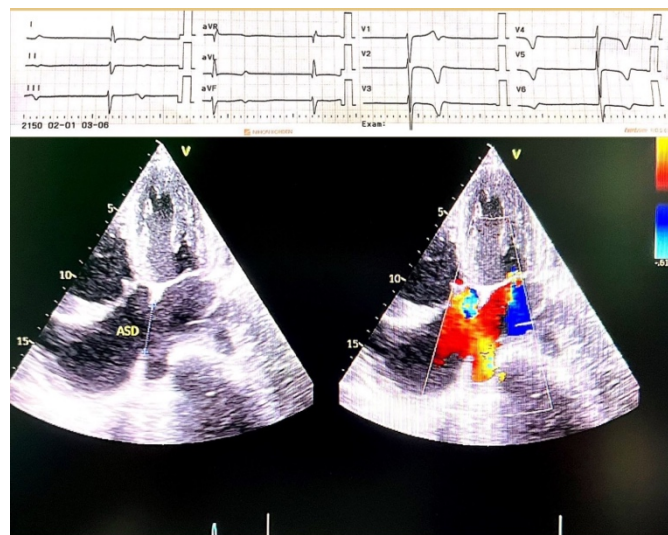
Case Illustration :


A 48-year-old female with chronic kidney disease stage 5, essential hypertension, chronic heart failure, and receiving bisoprolol presented to the Emergency Department with lethargy and weakness that started 3 days ago, with rapid deterioration into shock with bradycardia. She denied any family history of congenital heart disease. Laboratory findings hyperkalemia (6,33 mmol/L), and acute kidney injury (urea 86.8 mg/dL, creatinine 7.19 mg/dL, CrCl 8) was presented. The initial electrocardiogram was remarkable for junctional rhythm with heart rate of 39 bpm. Chest x-ray showed cardiac enlargement with features of pulmonary edema. The echocardiogram revealed large sized secundum Atrial Septal Defect (ASD) with a left to right (L to R) shunt and intermediate probability pulmonary hypertension. The right atrium, right ventricle were dilated suggestive of a significant L to R shunt. Her biventricular contractility was noted to be normal with ejection fraction 77%. Bisoprolol was immediately held. Potassium-lowering agents and diuretic were begun, as were dopamine for vasopressor support. sildenafil was given to treat pulmonary hypertension. Hyperkalemia can be overcome. Renal function improved and heart rate stabilized at 80 bpm. The patient was discharged and advised to avoid atrioventricular-blocking agents, with Cardiology follow-up.

Conclusion :

BRASH syndrome guarantees increased awareness among clinicians because early recognition of this syndrome can initiate the proper management and recovery of the patient.

Keywords: BRASH, ASD, hyperkalemia, bradycardia





Post Myocardial Infarction Acute Pericarditis

I. Yaqzhan¹, M. Syafri¹
Universitas Andalas¹

Background

Acute pericarditis post myocardial infarction (MI) is one of post cardiac-injury syndrome (PCIS) type. Pericarditis post myocardial infarction divided into 2 : early onset and late onset. MI didn't get successful reperfusion increased risk of post MI complication. Acute pericarditis post MI is not dangerous, however can be life threatening if accompanied with massive pericardial effusion that can develop into cardiac tamponade.


Case Illustration

A 67 years old male presented with chest pain since 9 hours in emergency room (ER). Chest pain accompanied by diaphoresis, duration more than 30 minutes, not improved by rest. There was no shortness of breath and palpitation. Patient was an active smoker as a risk factor of coronary artery disease (CAD). ECG showed sinus rhythm with rate 94 beat per minute, Q pathologic at V1-V4 lead, ST elevation 1-4 mm at lead I, aVL, V1-V6, ST depression at lead II, III, AVF. Chest x-ray showed no pathologic finding. Blood laboratory showed troponin I 13.310 ng/L. Patient underwent primary percutaneous coronary intervention (PPCI) got implanted 1 stent at proximal left anterior descendant (LAD) on CAD 1 vessel disease (VD) TIMI flow 2 MBG 2. The patient got therapies ASA 1x100 mg, ticagrelor 2x90 mg, enoxaparin 1x0,4 cc SC for 3 days, atorvastatin 1x40 mg, and ramipril 1x2,5 mg. The patient had progressive massive pericardial effusion. The patient observed for 14 days and not underwent pericardiosentesis because not showing tamponade sign. The patient discharged with stable condition with therapies ASA 3x800 mg for one month tapering off, clopidogrel 1x75 mg, colchicine 1x0,5 mg, atorvastatin 1x40 mg, ramipril 1x2,5 mg, and lansoprazole 1x30 mg.

Conclusion

This case highlights complication that can happen in STEMI patient, moreover in failed revascularization. Acute pericarditis post MI can be life-threatening condition especially if accompany with massive pericardial effusion. Watchful monitoring is essential in these patients.

Keywords: Myocardial infarction, acute pericarditis, pericardial effusion



Furosemide-Induced Thrombocytopenia in Heart Failure: A Case Report

S.E. Laelaem¹, I. Haryana², S. Tiro³
Puskesmas Masohi¹
Universitas Pattimura²
Siloam Hospitals Ambon³

Background

Most of the symptoms related to acute heart failure (HF) are caused by congestion, and loop diuretics represent the mainstay of its treatment. Furosemide as a potent loop diuretic is one of the main therapies given to heart failure patients with congestion. The diuretic effect of furosemide can cause fluid and electrolyte depletion in the body, influenced by the dose and preparation given. Furosemide has been rarely reported as the cause of thrombocytopenia.

Case Illustration

In this report, we present a case of a 55-year-old female with congestive heart failure, who had been treated with Furosemide which was identified as the probable cause of her drug-induced thrombocytopenia. She had been receiving oral furosemide for her heart failure. She was brought to the Emergency Department (ED) caused of shortness of breath. In ED she received intravenous (IV) furosemide 20mg/day. The patient's labs revealed for leukocytosis, thrombocytopenia, high serum creatinine, hyponatremia and hypochlorhydria. At first, her platelet counts were $51 \times 10^3/\text{mm}^3$, when the dose of IV furosemide increased to 120mg/day her platelet counts dropped to $33 \times 10^3/\text{mm}^3$. After a dose reduction back to 60mg/day the patient's platelet count $38 \times 10^3/\text{mm}^3$. A peripheral blood smear found platelet count below the lower limit of normal and morphology was normal so its analyze as suspect drug-induced thrombocytopenia.

Conclusion

Based on this case report, clinicians should consider furosemide as one of the drugs potentially causing thrombocytopenia.

Keywords: Furosemide, heart failure, drug-induced, thrombocytopenia

The Worsening Pneumonia Leading to The Type 2 Myocardial Infarction : a case report

M. Septian¹, T. Nandhika², A.F. Prianda¹, A.R. Ruhukail¹
RS Hasna Medika Kuningan¹
RSUD 45 Kuningan²

Background :

It is recognized that acute myocardial infarction (MI) can occur not attributable to atherothrombosis. The fourth universal definition of MI defined type 2 MI as an ischaemic MI in the context of mismatch oxygen supply and demand.¹

Case illustration :

A 59-year old female came to the emergency room with the aggravating dyspnea since 4 days, fever and phlegm cough before admission, no chest discomfort felt. The respiratory rate was 27 times per minute with 94% room air saturation. Rhonchi were heard but no others significant findings. Electrocardiogram (ECG) showed no remarkable results. The patient was diagnosed with pneumonia, chronic obstruction pulmonary disease (COPD) and chronic cor pulmonale.

The saturation dropped below 80% on day 3, the dyspnea have worsened, also chest discomfort felt. Marked ST segment depression in lead V3-V6 and II, III, aVF have seen on repeated ECG with elevation of Troponin T (140 ng/L). We concluded the patient had type 2 MI as it met the criteria of cardiac biomarkers elevation and evidence of myocardial ischaemia², also the patient not presumably having a history coronary artery disease (CAD) and there was evidence of oxygen supply deficit. It was also in coherent with the patient's sex, old-age and COPD comorbid.^{2,3}

No specific therapy was given, the treatments were for the underlying diagnosis resulting in type 2 MI. The key points are pretest probability of type 1 MI and risks of giving or withholding the type 1 MI treatments.⁴ On the day 4, the complaints were subsided and the oxygen saturation went back to 92-93% after antibiotics therapy. We repeated the ECG and it showed normalization.

Conclusion :

We provide the case of MI that result from non-atherothrombotic cause, thorough investigations and therapeutics approaches are needed for better outcome.

Keywords: myocardial infarction, oxygen supply and demand mismatch

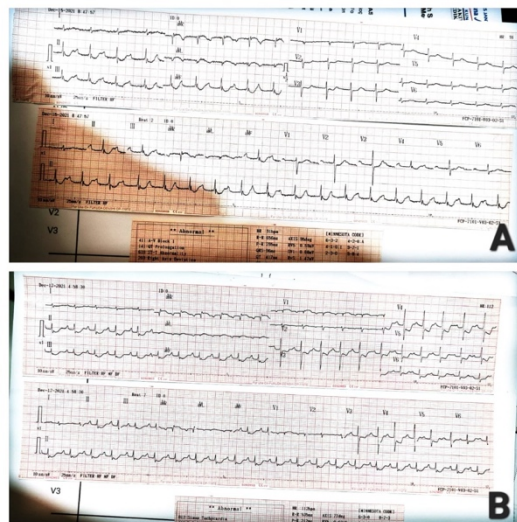


Fig. (A) Electrocardiogram (ECG) of first patient came to the ER. (B) Repeated electrocardiogram (ECG) with depression of ST segment in lead V3-V6 and II, III, aVF

Challenging Management of Sinus Valsava Rupture and Aortic Regurgitation as a Complication of Doubly Committed Subaortic Ventricular Septal Defect : A Case Report.

W. Mubarok¹, M.H. Trisnawan¹, S. Sungkar²

¹ Faculty of Medicine, Diponegoro University, Semarang, Indonesia

² Departement Cardiology and Vascular Medicine, Dr. Kariadi General Hospital Semarang, Indonesia

Background

Doubly committed subarterial ventricular septal defects account for 10% of ventricular septal defects. The management of aortic regurgitation and rupture of sinus valsava in the setting of ventricular septal defect has always been challenging.

Case Illustration

A 22 years old man was referred to our hospital because of shortness of breath, palpitation and deterioration in exercise capacity. The complains worsen in last 6 month. Cardiac ecamination found a thrill and loud continous murmur along the left sternal border. The ECG represent sinus rythm 89 bpm with multifocal PVC. Distended jugular venous pressure, ascites and edema at lower extremity were present. Chest x-ray showed pancardiomegaly and the echocardiography were found a doubly committed subaortic ventricular septal defect with the severe aortic regurgitation and rupture of sinus valsava. The management of this patient including diuretic, ACE-i, digoxin and drainage of ascites. For further management, the patient underwent surgical correction with ventricular septal defect closure and aortic valve replacement.

Conclusion

Ventricular septal defects can lead to aortic regurgitation and ruptur of sinus valsava because of ventury effect. Echocardiography provided a complete evaluation of such cases and prohibited missed diagnosis of other coexistent congenital heart defects. Management of such condition include therapy of heart failure and surgical correction.

Keywords: aortic regurgitation, ventricular septal defect, rupture of sinus valsava

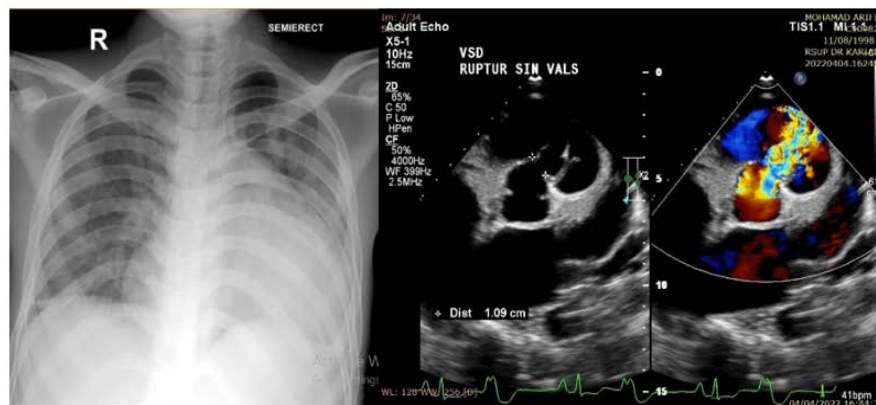


Figure 1. Left picture, showed chest x-ray. Right picture, echocardiography showed vsd with rupture of sinus valsava.

Where is the culprit lesion?: A case report

A.A. Lukito¹, H. Hutabarat¹, R.A.P. Fernandes¹, S. Chandra¹
Siloam Hospital Lippo Village¹

Background

The culprit lesion is used to designate the coronary stenosis thought to be responsible for the acute coronary syndrome.

Case Illustration

A 54-year-old male with typical chest pain during badminton and called for ambulance. The patient had previous history of PCI 5 years ago and had permanent afib. There is no significant finding in physical examination and hemodynamic. Patients routinely take rivaroxaban 15mg once daily, aspirin 80mg once daily. The loading dose of aspirin 160mg, clopidogrel 300mg was given by the ambulance physician and ticagrelor 90 mg at the emergency room.

ECG showed atrial fibrillation normoventricular response, rate 60 bpm, LAD, borderline ST elevation II, III and avf.

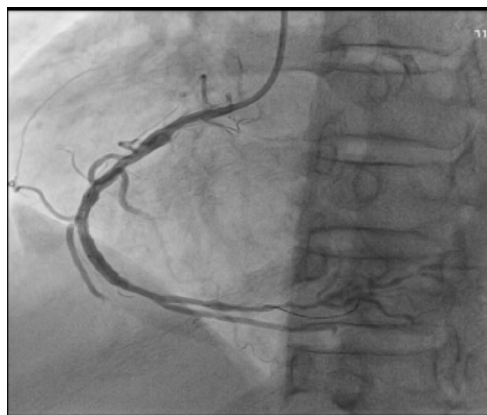
Coronary angiogram showed right dominant, proximal classification in RCA, ectasis from proximal to distal, 80% lesion in middle RCA, multiple mild lesions in distal+middle RPL and proximal RPDA. Normal left main coronary. 20% lesion in proximal LCX, 80% lesion in distal LCX (small calibre), 30% lesion in OM2, 80% lesion in ostial LPL, TIMI 3 distal flow and in LAD: proximal calcification, 35% mild lesion intra old stent in proximal mid LAD, 50% calcified lesion in mid distal LAD (from old stent), TIMI 3 distal flow. All coronaries flow were normal TIMI 3. In this case, IVUS is not possible because it is under maintenance.

Judging from the typical chest pain & history of previous heart attack and atrial fibrillation, it was decided to stent the RCA that looked as a stable lesion that create confusion which is the culprit lesion.

Conclusion

In case with clinical and typical investigations of STEMI, normally it will be easy to find the culprit lesion. This case did not find a typical culprit lesion, IVUS can play a role in providing information of the stability of suspect lesion based on borderline ST changes of the ECG

Keywords: STEMI, Culprit, AFib



Angiography RCA

SUCCESSFUL PERCUTANEOUS CLOSURE OF ATRIAL SEPTAL DEFECT USING ZERO FLUOROSCOPY TECHNIQUE IN PREGNANT WOMAN

I. Kamelia¹, H. Martini², V. Yogibuana², A.F. Rahimah², A. Wicaksono¹, E. Fathoni¹

¹Cardiology Resident, Faculty of Medicine Universitas Brawijaya- Saiful Anwar Hospital, Malang, Indonesia;

²Departement of Cardiovascular Medicine, Faculty of Medicine Universitas Brawijaya-Saiful Anwar Hospital, Malang, Indonesia

BACKGROUND

Atrial septal defects (ASDs) are one of the most common acyanotic congenital heart lesions with the initial clinical presentation and diagnosis or getting worsening clinical symptoms during pregnancy. If indicated, percutaneous closure can be performed safely. We report successful percutaneous closure by zero fluoroscopy technique in pregnant patient with ASD-PH.

CASE ILLUSTRATION

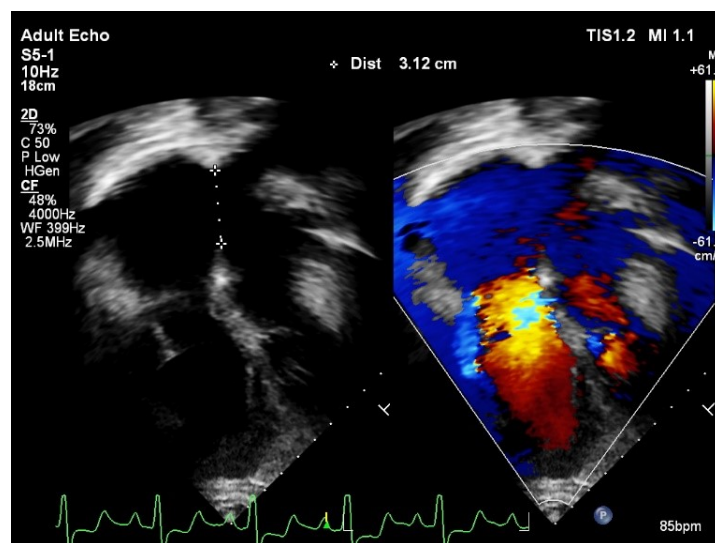
A 38-year-old woman with diagnosis ASD-PH. TEE was demonstrated a large ASD measuring 28 - 32 mm with adequate rim suitable for closure by device. Result from RHC was ASD secundum with pulmonary hypertension high flow high resistance (mPAP 58mmHg and PARI 2.4 wu.m² post oxygen test). She scheduled to performed ASD closure by device. But before closure had been done, she had got pregnant. Doctor in charge planned to perform closure as soon and safe as possible in second trimester of pregnancy.

The procedure then performed under general anesthesia, using TEE guidance. Femoral venous access was achieved with a 14 F sheath inserted into the right femoral vein. The defect was crossed with a guide wire using TEE guidance. Considering the defect size and not available balloon assist device, operator decided to use modified-catheter assisted technique. The defect was then closed percutaneously using a 40 mm ADO device with no residual shunting and sufficient rim attachment on evaluation by TOE. After procedure done, there is no complication and patient came home safely.


CONCLUSION

Pulmonary hypertension who may develop in patient with congenital heart diseases is one of contraindication of pregnancy. In our case, in spite of unexpected pregnant condition in patient with ASD-PH, the team in charge can give prompt treatment by perform percutaneous closure using zero fluoroscopy technique at second trimester. The timing of ASD closure is important to minimize the risk of radiation exposure to the developing fetus.

Keywords: Atrial septal defect (ASD), percutaneous closure, Pregnancy, Zero fluoroscopy technique.



Transthoracic Echocardiography showed Atrial septal defect 31mm



Clozapine-induced Cardiomyopathy: A Reversible Outcome With Lethal Effects

Y. Newary. D.L. Munawar¹
Binawaluya Hospital¹

Background

Drug-induced cardiomyopathy is a potentially reversible form of acquired CM and a common consequence of exposure to numerous medically prescribed drugs. It is particularly a common serious adverse side effect of anticancer, antiretroviral and antipsychotic therapies. Rarely, clozapine, an antipsychotic drug used to treat schizophrenia, has been reported to cause cardiomyopathy, as we report in this case.

Case Illustration

A 17-year-old man who was known to have schizophrenia and was on clozapine therapy, presented in our emergency department with clinical heart failure worsening 6 hours before admission. On physical examination, he was tachycardia, tachypneu and . ECG demonstrated left ventricular hypertrophy and chest x-ray showed cardiomegaly with pulmonary congestive. Echocardiography showed a reduced left ventricular ejection with dilated all cardiac chamber. CT coronary showed no abnormality. Other laboratory results high NTproBNp with negative respiratory viral panel including COVID-19 PCR, negative blood cultures and BTA. Then the patient was performed CT thorax with result thrombus in left pulmonary artery and the branch of segmented left pulmonal.

The patient received management of heart failure with reduced ejection fraction. He improved clinically and was continued on anticoagulant therapy for embolism pulmonary.

Conclusion

Several researches have discussed possible mechanisms to explain clozapine-related cardiac side-effects such as cardiomyopathy. Given the potential risk to patients, it is obviously important to make the diagnosis as early as possible. Careful monitoring of cardiac function in patients started on clozapine would therefore have to be considered an important part.

Keywords: cardiomyopathy, clozapine, heart failure

Pulmonary Embolism Mimicking NSTEMI-ACS

P. Maulina¹, M. Yanni²

Faculty of Medicine, Andalas University, Padang, Indonesia¹

Department of Cardiology and Vascular Medicine, DR M Djamil Hospital, Padang, Indonesia²

Background

Acute pulmonary embolism (PE) and acute coronary syndrome (ACS) are considered to be potentially life threatening. Both have signs and symptoms that are common to either presentation such as dyspnea, chest discomfort and hemodynamic instability.

Case Illustration

A 56-year-old male admitted to emergency room with chest pain and dyspnea since 4 hours before admission. On physical examination, blood pressure was 123/66 mmHg, tachycardia 135 bpm, tachypnea 33x/minute, and oxygen saturation 92 % with NRM 15 L/minute. Coarse rales were heard in both of lungs. ECG showed Q pathologies and inversion of T wave in lead III and aVF. Troponin I level was remarkably high. Due to hemodynamic instability with signs of acute heart failure, patient was sent to cathlab for immediate invasive strategy as very high-risk NSTEMI-ACS. However, coronary angiogram demonstrated normal coronary arteries. Bedside echocardiography showed McConnell's sign as a sign of pulmonary embolism. Patient was treated with systemic thrombolytic therapy using Streptokinase, and continued with subcutaneous Enoxaparin. Computed tomography pulmonary angiography (CTPA) demonstrated thrombus in both of pulmonary arteries (Figure 1), and Doppler ultrasound showed deep vein thrombosis in both of popliteal vein. After 10 days of Enoxaparin, an evaluation of CTPA showed decreased in the size of thrombus. He was discharged with Vitamin K antagonist therapy and CTPA evaluation after 3 months showed no residual thrombus in pulmonary arteries.

Conclusion

Physician in emergency room must be aware that pulmonary embolism can present as chest pain and misdiagnosed as ACS. After excluded ACS with coronary angiogram, in hemodynamic instability patient, bedside transthoracic echocardiography can be done to see the right ventricle dysfunction. And when CTPA was not available, we can treat the patient as high risk PE, and systemic thrombolytic was recommended (Class I B), as demonstrated in this case.

Keywords: Pulmonary embolism, NSTEMI-ACS

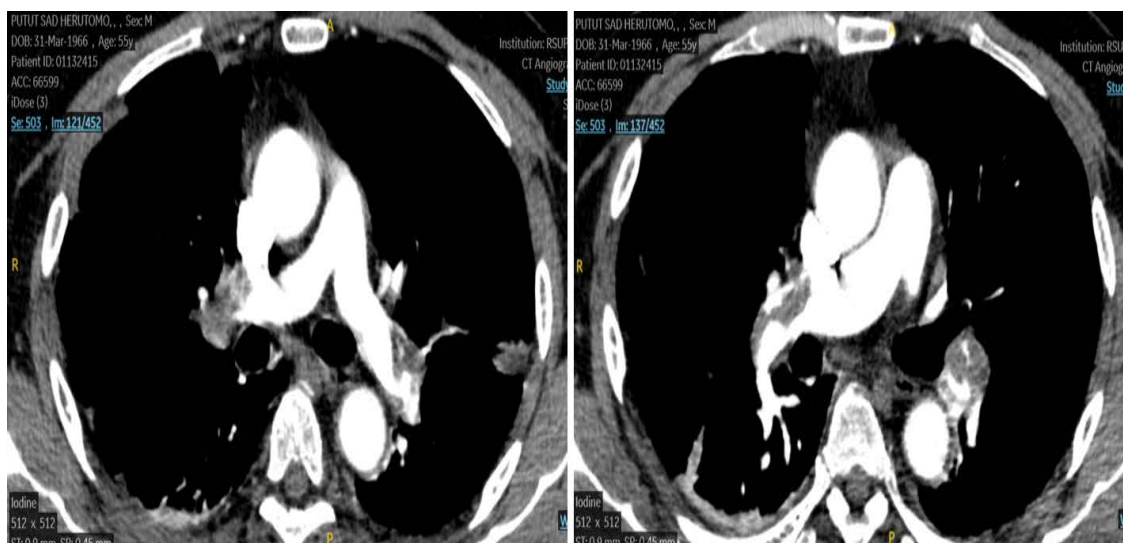


Figure 1. CTPA demonstrated thrombus in both of pulmonary arteries

A Case of Autoimmune-induced Acute Limb Ischemia in Patient with Systemic Sclerosis Preceded by Secondary Raynaud's Phenomenon

R. Istisakinah¹, T.S. Tartila², I.F.A. Putra²

Cardiologist, Hasna Medika Kuningan Heart Hospital, West Java, Indonesia¹

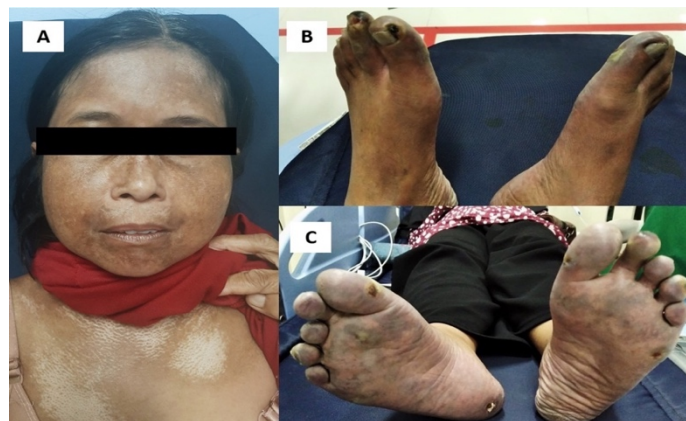General Practitioner, Hasna Medika Kuningan Heart Hospital, West Java, Indonesia²

Background: Secondary Raynaud's phenomenon (RP) is common first manifestation of connective tissue disease and presented in nearly 95% patients with systemic sclerosis (SSc). Secondary RP can indicate severe underlying vasculopathy with greater risk of tissue ischemia and ulceration. We present a case of autoimmune-induced acute limb ischemia in patient with SSc preceded by secondary RP as heralding manifestation.


Case Illustration: A 44-year-old female came to our outpatient clinic with years history of episodic painless discoloration of fingers and toes on exposure to low temperature. The patient also developed skin dyspigmentation and stiffness in the last 1 year. General examination revealed skin hyperpigmentation and thickening, with the appearance of salt-and-pepper pigmentation around forehead, nose bridge, and upper chest. There was no ulceration found from initial encounter. Demographic and clinical features suggested secondary RP caused by SSc, further confirmed by positive antinuclear antibody. We gave oral nifedipine and nitrate for routine treatment. Three months later, the patient came to ER with a week history of digital ulcers accompanied by darkening of the skin and pain. Physical examination discovered multiple bilateral ulceration with gangrene on her toes, with absence of peripheral pulsation of both right and left dorsalis pedis arteries. Doppler ultrasound showed no flow with no thrombus in bilateral tibialis anterior and dorsalis pedis arteries. We concluded that ischemic injury was induced by autoimmune-mediated vasculopathy. The patient was treated with oral nifedipine, nitrate, cilostazol, and enoxaparin injection. There was only slight improvement, so we referred the patient to vascular surgery.

Conclusion: We emphasize the need for early recognition of secondary RP and its underlying connective tissue disease as the condition can lead to severe ischemic injury. Once established, comprehensive management should be started early to prevent permanent tissue damage and disability.

Keywords: systemic sclerosis, acute limb ischemia, autoimmune



(A) Salt-and-pepper appearance over forehead, nose bridge, and upper chest, (B) Dorsal and (C) Plantar view of ulceration and gangrene of the toes



Myocardial Infarction With Nonobstructive Coronary Arteries (MINOCA) : a case series

S. Fatimah, T. Pramitasari, A.E. Satuti¹
RSUD Kota Yogyakarta¹

Background

Myocardial infarction with non obstructive coronary arteries (MINOCA) is a syndrome characterized by clinical evidence of MI and angiographically normal or almost normal coronary. Its albeit rare with prevalence only 5 to 6% of all MIs but the reported prevalence keeps rising due to better recognition of this syndrome.

Case illustration

Case 1 : A 65 years old female came to ER complaining chest pain, described as heavy pressure on her left chest radiating to the back accompanied by diaphoretic and dyspnea. Electrocardiogram showed ST segment elevation with frequent VES and elevated troponin I suggest for high lateral STEMI. She was treated with dual antiplatelet, heparin, diuretic, beta blocker, ARB, and statin. Slow flow in LAD coronary artery without any occlusion was found during coronary arteriography. In the fifth day of treatment patient was discharged without any complain.


Case 2 : A 55 years old female came to ER complaining shortness of breath. Symptoms began 6 hours before and progressively worsened. She had high blood pressure, tachypnea and low oxygen saturation. There were rales and wheezing. Electrocardiogram showed some pathological q wave and laboratory test showed elevated troponin I. Chest radiograph showed mild pulmonary oedema. She was treated with dual antiplatelet, heparin, vasodilator, diuretic, statin and ARB. During two days of hospitalization patient continuous experiencing symptom and suddenly had a very low BP suggest for high risk NSTEMI. She was taken for coronary angiography which reported no signs of obstructive CAD. In the fifth day of treatment patient was discharged without any complain.

Conclusion

The causes of MINOCA are several and the optimal management depends mainly on it. Careful consideration and identification of the underlying cause is important to make a better prognosis and to improve the quality of life of the patient.

Keywords

Myocardial infarction, MINOCA



**Risk factors for cardiovascular disease in patients with non ST segment elevation myocardial infarction :
A case report**

H. Junianto¹, P. Jeremiah¹
RS BK Woodward Palu¹

Background : Non ST segment elevation acute coronary syndrome is a clinical syndrome consisting of unstable angina pectoris and non ST segment elevation acute myocardial infarction. Characteristic include chest pain typical of infarction accompanied by elevated cardiac enzymes (*Troponin*).

Case illustration : A 63 year old man came with complain of left chest pain that had appeared since one day ago. The chest pain was felt to radiate to the shoulder, and felt like being hit by a heavy load. Tightness is also complained of when experiencing chest pain. Chest pain is felt to arise and disappear, appearing during light activities and at rest. Duration of chest pain is more than 20 minutes, nausea is present, previous history of hypertension and smoking, history of taking amlodipine 5 mg daily but not regularly. Physical examination, blood pressure 190/90, pulse 88, respiration 25, and SpO₂ 98%. Laboratory examination, total cholesterol 223, HDL 40, trigliserida 236, troponin 1,0. EKG examination showed NSTEMI V4-V5, T inversion and LVH. The patient was recommended for hospitalization and observation for complaint of chest pain. Drug therapy aspilet 80 mg, clopidogrel 75 mg, isdn 3 x 5 mg, atorvastatin 20 mg, amlodipine 5 mg, ramipril 5 mg, diviti 2.5 mg sc for 3 days. The patient experienced improvement and was educated to stop smoking, reduce high fat foods, take medicine regularly and healthy lifestyle. After 3 days of hospitalization, the patient was allowed to be outpatient and routine control at the outpatient clinic.

Conclusion : In this case, cardiovascular disease risk factors play an important role in patient suffering from acute coronary syndrome disease. Appropriate and routine treatment should be carried out, and healthy lifestyle can be implemented to prevent the risk of more severe complication.

Keywords: Risk factors for cardiovascular disease, Acute coronary syndrome.

Acute Heart Failure Following Acute Myocardial Infarction in a 25 years-old Male: A Reality

M.N. Hutapea¹, N.P. Pranidya¹, A.A. Hakim², N.R. Utantyo², A. Parlautan², P. Wulandari², F. Ahmad², A. Nandiwardhana²

General Practitioner, Badan Pengusahaan Batam Hospital, Riau Island, Indonesia¹
Cardiologist, Badan Pengusahaan Batam Hospital, Riau Island, Indonesia²

Background

Acute heart failure (AHF) commonly is an impending complication to acute myocardial infarction (AMI). AMI is statistically uncommon in the young adults. Heart failure following AMI is the major driver of late morbidity, mortality and healthcare cost.

Case Illustration

A 25-year-old man was referred to our emergency room (ER) due to typical chest pain. He was a heavy smoker without any medical history before. Physical examinations were found normal during the initial assessment at the ER. ECG showed an ST elevation in anterior leads and elevated serum troponin I was reported. The chest x-ray and other laboratories were normal. A coronary angiogram (CAG) was carried out and revealed single vessel disease with total occlusion in the ostial-proximal part of left anterior descending (LAD) coronary artery. PCI was successfully done with one stent implanted at ostial-proximal of LAD without any complication. However during the monitoring in CVCU, the patient's condition showed symptoms and signs of Heart Failure (HF). Echocardiography showed eccentric LVH and hypokinetic in anterior wall with EF 48%. IVC diameter were found to be dilated. We perform decongestion strategy using intravenous loop diuretic therapy. We initiated guideline-directed HF therapy to achieve euvolemic state and good perfusion. Monitoring HF treatment includes careful measurement of fluid intake and output, vital signs, and clinical signs and symptoms of congestion and hypoperfusion is an essential part.

Conclusion

AMI in young patients remains a challenge in the emergency department. Knowledge of the mechanisms responsible for ventricular dysfunction after MI is major importance. Better identification of patients at risk of HF development after MI is needed because timely initiation of guideline-directed HF therapy can reduce the risk of further LV remodelling, morbidity, and mortality.

Keywords: Acute Heart Failure, Acute Myocardial Infarction, Young patients

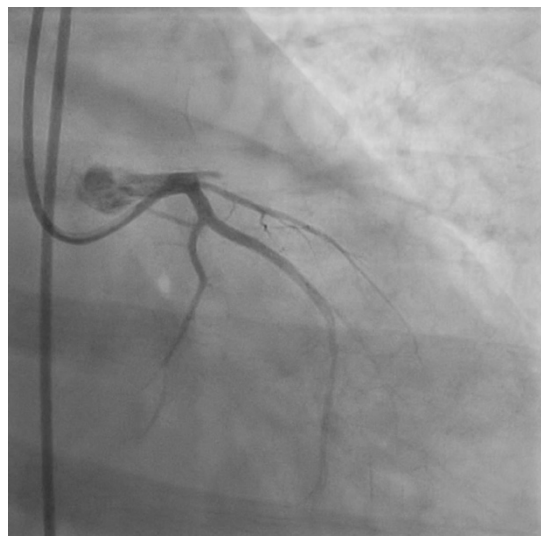



Figure 1. Coronary angiogram showed total occlusion at ostial-proximal part of LAD



Breaking the Silence: An Insightful Case Series on Hypertensive Emergency in Acute Aortic Syndrome Patients

A. Alamsyaputra¹, I.P. Farissa¹, M.F. Ahnaf¹, L.D. Pradipta¹
RSUP Dr. Kariadi Semarang / Universitas Diponegoro¹

Background

Hypertensive emergency is an abrupt and significant rise in arterial blood pressure in individuals with established hypertension or spontaneously, causing immediate end-organ damage and requiring fast-acting medications. Acute aortic syndromes are symptomatic thoracic and abdominal aorta disease that require immediate evaluation and treatment. Acute aortic dissection, intramural hematoma, and penetrating atherosclerotic ulcer are examples.


Case illustration

First case was 47 years old man with 5 years uncontrolled hypertension history, presented to emergency room complaining about high intensity and sharp abdominal pain 5 days prior to admission, continuous, and referred to the back. His blood pressure was 201/112 mmHg with symmetrical peripheral pulses. Electrocardiography and troponin were negative. Abdominal computed tomography angiography (CTA) showed abdominal aorta intramural hematoma. Second case was 52 years old man with 3 years uncontrolled hypertension history, presented to emergency room with a chief concern of 2 days continuous and tearing abdominal pain. His blood pressure was 182/99 mmHg, ECG and troponin were unremarkable. Abdominal CTA revealed dissection of descending thoracic aorta and abdominal aorta. We managed the patient with surgery preparation, intravenous nicardipine and morphine sulphate, oral beta blocker, targeting systolic blood pressure <120 mmHg and heart rate <60 bpm before surgery.

Conclusion

The primary management in acute aortic syndrome is to normalize blood pressure and to reduce the force of left ventricular ejection (dP/dt), which are the main determinants of dissection extension and rupture, by using beta blocker, opiates for pain control, and non-nitrate vasodilator. The importance of timely diagnosis and intervention, and offers practical strategies for managing this complex and potentially life-threatening condition. Diagnosis and treatment of hypertensive emergency in acute aortic syndrome patients serve as valuable resource for clinicians seeking to improve their understanding and management of this critical condition.

Keywords: hypertensive emergency, acute aortic syndrome, left ventricular ejection force



Increasing Successful Rate of Percutaneous Transluminal Angioplasty in Immediate Diagnosis and Management Central Venous Stenosis in Hemodialysis Patient: Faster Better

A.R. Akbar^{1,3}, N. Kurnianingsih^{1,3}, A. Gunawan^{2,3}

¹*Department of Cardiology and Vascular Medicine, Faculty of Medicine Universitas Brawijaya;*

²*Department of Internal Medicine, Faculty of Medicine Universitas Brawijaya;*

³*dr. Saiful Anwar General Hospital*

Background:

Stasis, thrombosis, and impaired arteriovenous (AV) fistula are possible problems to manifest Central venous stenosis (CVS). Almost 25% dysfunctional fistulas at patient with dialysis are known to have these problems. Proper and immediate identification of CVS is critical to improve the successful rate of percutaneous transluminal angioplasty (PTA) in hemodialysis patient. We present the immediate decision of CVS in hemodialysis patients.

Case illustration:

A 53 year old woman complaining of left arm swelling since 2 weeks. These Complaints are not combined by pain, fever, or accidental injuries at the arm. She routinely undergoes hemodialysis twice a week with AV fistula access in the left arm for 12 years. Hemodialysis can still run smoothly even with swelling in her left arm. PTA was performed without waiting hemodialysis problem as an immediate management of CVS and resulting without any complications.

Discussion:


CVS is generally associated with long term AV fistula. The Endothelial injury from physical stimulation of the vein wall preceded the development of CVS and also developed smooth muscle proliferation and microthrombic. PTA as an immediate procedure for CVS has high rate success although patentability is low in long-term condition. This patient is still needed to Follow-up for determining long-term patency.

Conclusion:

Percutaneous transluminal angioplasty is one of immediate managements for better result of CVS in hemodialysis patient

Key words: Central venous stenosis, Percutaneous transluminal angioplasty, Hemodialysis patient

Keywords: Percutaneous Transluminal Angioplasty, Central venous stenosis



29 Years Old Woman with Triple Vessel Disease: A Case Report

W.N. Yuandika¹, S. Sungkar¹

¹ *Department of Cardiology and Vascular Medicine, Faculty of Medicine,
Diponegoro University – Dr. Kariadi General Hospital, Semarang*

Background

In recent decades, the incidence of Acute myocardial infarction (AMI) is increasing in younger women in the context of increasing metabolic syndrome, diabetes mellitus, and non-traditional risk factors. Compared with men, women have greater in-hospital, early and late mortality, as a result of baseline comorbidities.

Case illustration

A 29-year-old woman referred from regional hospital ICU to dr. Kariadi Hospital with chief complaints of typical chest pain for 44 hours prior to dr. Kariadi hospital admission. Patient was fully alert with blood pressure of 99/72, and heart rate was 108 bpm. ECG showed a Q wave in lead II III AVF, ST segment elevation in II III AVF, V5-V6, V7-V9, V4R-V6R, with ST Depression in I AVL; V1-V3 and T inverted in V7-V9, V4R-V6R. Chest X-Ray showed pulmonary oedema with suspected cardiomegaly. Blood panels showed Dyslipidemia, Diabetes, elevated Lactate and Transaminase. Echocardiography finding was LV dilatation with eccentric type LVH, positive RWMA in inferoseptal, inferior, inferolateral and apicoinferior segment. LVEF was 40%(B) with LV DD grade II. Percutaneous coronary intervention was performed and showed 80% stenosis in Mid RCA, 70% in LAD, and 70% LcX. Revascularization was successfully performed with 2 DES in RCA.

Conclusion

Although rare, AMI in very young woman usually happen because of poorly controlled risk factors, as in this case a history of Gestational Diabetes, Dyslipidemia and Obesity. AMI has historically been regarded as a man's disease, and for many years, women have been underdiagnosed and undertreated. This case reminds us how secondary prevention acts as a corner stone in managing coronary artery disease.

Keywords: Myocardial Infarction, Angiography, Triple Vessel Disease, Young Adults, Woman

NEW ONSET ATRIAL FIBRILLATION IN STEMI PATIENT: CASE REPORT

Herlina, D.J. Tito¹
Puri Husada Hospital Tembilahan¹

Background: Atrial fibrillation is one of the abnormalities in the heart rhythm that causes irregular or arrhythmia as a result of abnormal impulses on heart. Atrial Fibrillation (AF) is a common arrhythmia in the setting of acute coronary syndrome and acute ST-elevation myocardial infarction (STEMI). A population-based study demonstrated that the incidence of AF in the setting of Acute Myocardial Infarction (AMI) tended to increase up to 13.3% during last decade. AF in the setting of AMI has a worse impact on the clinical course and prognosis of the disease. AF should be diagnosed, treated and convert to sinus rhythm as soon as possible, since its duration correlates with mortality.

Case illustration: A 55-year-old male patient presenting an acute STEMI as initial presentation with AF as complication. The electrocardiogram (ECG) showed AF with a rapid ventricular response with ST segment elevation in extensive anterior on the second day of hospitalization. Chest X-ray found a cardiomegaly and laboratory result found increased high sensitive cardiac troponin I (hs-cTnI) level on admission, 7032.4 ng/L. During hospitalization, patient was treated with dual antiplatelet therapy (DAPT), anticoagulant, vasodilator, beta blocker, and antiarrhythmic medication. Oral amiodarone 200 mg as antiarrhythmic agent, is effective in the conversion of AF to sinus rhythm in this patient. Patient showed an improvement of his clinical condition and discharged on the fourth day of hospitalization with controlled heart rhythm.

Conclusion: An arrhythmia complication in STEMI patient was detected with ECG on second day hospitalization. In addition to acute coronary syndrome therapy, the patient was also given antiarrhythmic drugs and showed good results.

Keywords: atrial fibrillation, acute myocardial infarction

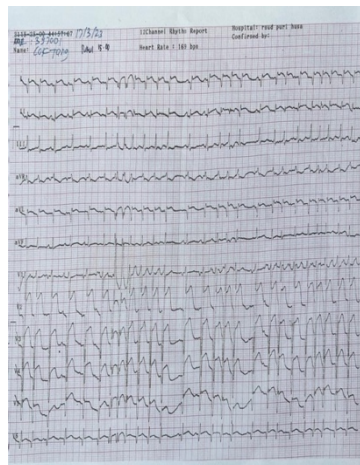


Figure 1. The electrocardiogram (ECG) showed AF with a rapid ventricular response with ST segment elevation in extensive anterior on the second day of hospitalization.

Echocardiography as A Tool in Differentiating Left Atrial Myxoma and Other Intracardiac Masses

W. Valerian, M. Yanni, M. Syafri¹
Universitas Andalas¹

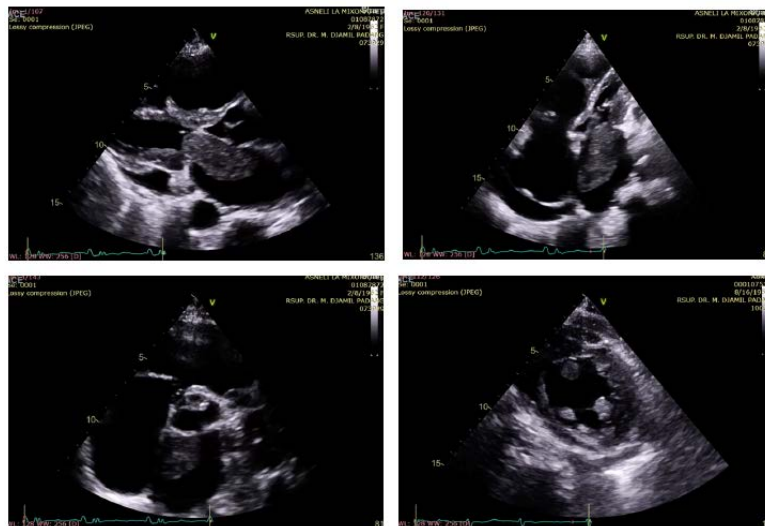
Background: Myxoma of the left atrium is the most common benign tumor that can be found, accountable for almost 70% of primary cardiac tumors. Myxoma is often described as a mobile, lobular mass located in the left atrium, particularly at the fossa ovalis, and rarely found in the right atrium or ventricle. The ability to differentiate tumors and other intracardiac masses is what makes echocardiography needed.

Case Illustration: A 58-year-old female came to the emergency room with shortness of breath. The symptoms persisted for more than 1 year, which worsened with activity. Other complaints were denied, but the patient admitted to having uncontrolled diabetes for more than 10 years. From the physical examination, we found mid-diastolic murmur at the apex. ECG showed sinus rhythm with P wave terminal force at V1-V2 and low voltage with right ventricular hypertrophy. Echocardiography findings showed a mobile, regular mass, 29 mm x 45 mm in size, attached to the intra-atrial septum. The mass prolapsed into the left ventricle covering mitral inflow in the diastolic phase resulting in relative mitral stenosis with a transmitral gradient of 15 mmHg.

Conclusion: Echocardiography has an important role in diagnosing myxoma and evaluating tumor sizes and locations, as it can be similar to thrombus, vegetations, papillary fibroelastosis, lipomas, sarcomas, and other intracardiac masses. It also has a role in evaluating the patient's hemodynamic state, determining the location of the incision, and predicting the outcome of the surgery.

KEYWORD: *myxoma, echocardiography, intracardiac masses*

Keywords: myxoma, echocardiography, intracardiac masses



Catheter-Induced Spinal Coronary Arteri Dissections: A Case Report

S.G. Maharani¹, F.I. Shahab¹

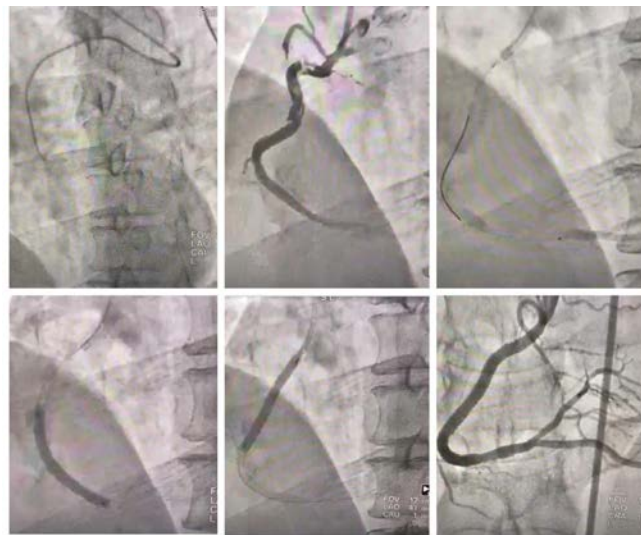
Intensive Coronary and Cerebrovascular Care Unit, Sentra Medika Cibinong Hospital, Bogor, Indonesia¹

Background: Catheter-induced coronary artery dissection (CICAD) is a rare but severe complication of coronary angiography (CAG), with the incidence <0.1%. In a retrospective 10-year cohort study of 56,968 patients undergoing CAG, catheter dissection was more common in the Right Coronary Artery (RCA) and mostly due to guiding catheter. Dissection without complications of acute ischemia will heal on its own. Whereas in a spiral dissection, a stent is needed to prevent the expansion of dissection.

Case Illustration: A 40-year-old male patient came to the cardiac clinic with typical chest pain of angina. The patient had a history of smoking and dyslipidemia. The results of Coronary Multislice Computerized Tomography (MSCT) examination were found in Left Anterior Descending (LAD) 70% proximal stenosis, 50% mid-distal stenosis. On the Left Circumflex (LCX) 50% distal stenosis. ECG result was sinus rhythm. Echocardiogram showed EF 66% with global normokinetics. CAG was performed via radial access. There was aortic elongation which makes cannulation to the ostial coronary quite difficult. In LAD there is calcification with 70-80% stenosis in the ostial-mid. Normal LCX. When cannulated into the RCA, spiral dissection occurred in proximal-distal. The patient had progressive chest pain. Access was immediately transferred to the femoral. Two stents were implanted in the RCA to close the dissection with the results of Thrombolysis in Myocardial Infarction (TIMI) 3 flow. One day after PCI the patient's hemodynamics were good and sent home. For the management of LAD lesion with calcification that would involve the left main artery, we planned elective PCI with Intravascular ultrasound (IVUS) guided.

Conclusion: A 40-year-old male patient, underwent coronary artery spiral dissection due to a catheter during angiography. 2 stents were implanted in the dissection area with good results.

Keywords: Spiral Coronary Artery Dissection



Cardiac Manifestation in Heterotaxy Syndrome: Case Report

I.B.U. Kramasanjaya¹, Y. Ardelia¹, R. Aviana¹, K. Rizky²

¹General Practitioner, Balaraja General Hospital

²Cardiologist, Balaraja General Hospital

Background

Heterotaxy Syndrome is an abnormality where the internal thoraco-abdominal organs demonstrate abnormal arrangement across the left-right axis of the body. Heterotaxy Syndrome divided into right isomerism and left isomerism. It occurs in 1:5.000-7.000 live birth with CHD.

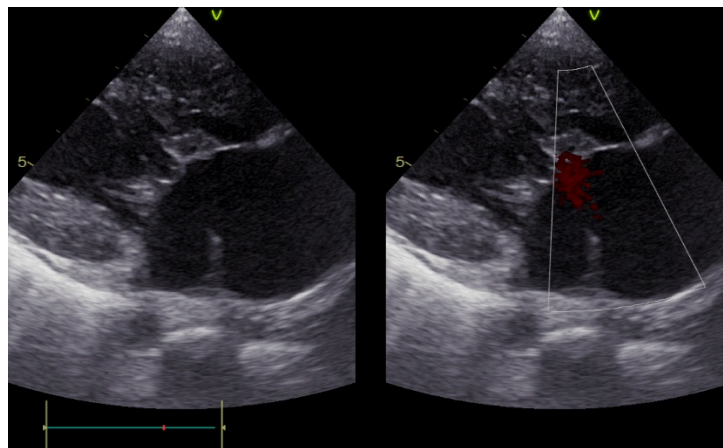
Case Illustration

A 6 year old male admitted to hospital for dyspnea exacerbating in the last 3 days and accompanied by fever and cough. He was easily tired and bluish even with light activities, since 2 years ago, severely wasted and stunted (14 kg, 105 cm), lethargic, BP 100/59, HR 145, RR 38, SpO₂ 75-78%. Central cyanosis, distended jugular vein, 4/6 pansystolic ejection murmur, palpable thrill on the right side of the chest, and clubbing fingers. Chest x-ray showed dextrocardia with increased pulmonary vascularity. Echocardiography exhibited large ASD, common AV Valve, single ventricle and hypoplastic pulmonary arteries. Thoracal CT scan showed dextrocardia with cardiomegaly, the left lung consists three lobes meanwhile the right lung consists two lobes, and spleen was not well visualized. His consciousness worsened, GCS E2M4V1, in day 6 hospitalization. Facial tic and jerking extremities appeared frequently. Brain CT scan showed multiple hypodense lesions with hyperdense areas at right basal ganglia and left parietal lobe were found. The patient was treated with broad spectrum antibiotics, diuretics, anticonvulsant, and other supportive therapies. He was prepared to craniotomy with abscess excision and aspiration but unfortunately he suffered cardiac arrest the next day.

Conclusion

HS is a rare congenital disorder with high mortality rate in early life. Early diagnosis and prompt treatment in cardiology or paediatric center may give better outcome for HS.

Keywords: Heterotaxy Syndrome



Echocardiography

A Case Series of Stent Thrombosis : Nightmare of The Interventional Cardiology in The Modern Era

F.H. Alkaf¹, S. Sungkar², I. Uddin², Y. Herry², S. Rifqi²

Faculty of Medicine, Diponegoro University, Semarang, Indonesia¹

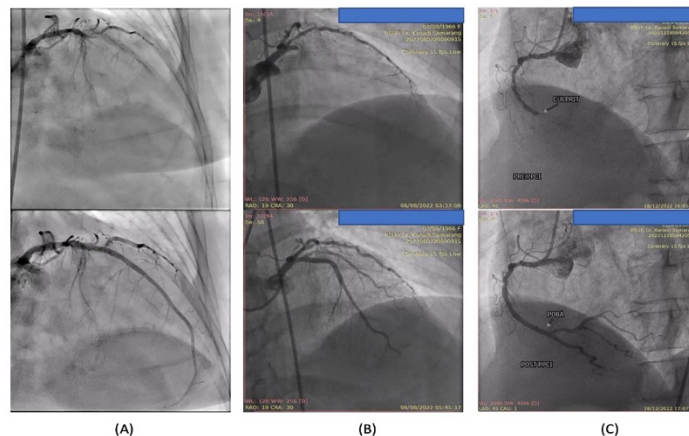
Department Cardiology and Vascular Medicine, Kariadi Hospital, Semarang, Indonesia²

Background: Coronary stents have marked an era in interventional cardiology and have significantly decreased the rates of stent thrombosis. But stent thrombosis is still a major problem of interventional procedures. Stent thrombosis after percutaneous coronary intervention (PCI) is a rare and usually poor prognostic event that might result in myocardial infarction and sudden death

Case Illustration: A 74-year-old woman presented to the emergency department (ED) with typical chest pain. The first ECG showed Non-ST Elevation, with PCI procedure was performed approximately 2 weeks before admission with Everolimus-Eluting Stent in LAD, but didn't consume DAPT (aspirin and clopidogrel) for 1 week before admission to the hospital. She developed multiple episodes of ventricular fibrillation and received defibrillator shocks. After ROSC, The second ECG showed ST-Elevation in the anterior lead. She underwent successful PCI with Plain Old Balloon Angioplasty (POBA). A 56-year-old woman presented to the ED with chest pain onset 1 hour, with the first and second ECG (H0/H1) showing Non-ST Elevation. The echocardiography examination was performed to rule out aortic dissection. The third ECG (H4) showed ST-Elevation in the anterior lead. She was performed with PCI with Everolimus-Eluting Stent in LAD 10 days before admission and didn't consume ticagrelor for 1 day before admission. She underwent successful PCI with stent-in-stent. A 67-year-old man came to the ED with typical chest pain. He had a history of PPCI in bifurcation of RCA-PDA after Inferior STEMI 7 days ago. He had good compliance with DAPT (aspirin and clopidogrel). He underwent successful PCI with POBA.

Conclusion: Stent thrombosis remains a significant complication in interventional cardiology, even in the modern era. In the present era, complications associated with stent thrombosis are rare but fatal if not managed appropriately. There are many factors related to stent thrombosis such as procedure, patient and lesion, antiplatelet, and thrombogenicity.

Keywords: Stent thrombosis, PCI, ticagrelor, intervention



Before and After PPCI in Stent Thrombosis Event. (A) Case 1, (B) Case 2, (C) Case 3

Before and After PPCI in Stent Thrombosis Event

PERIMYOCARDITIS, MIMICKING ACUTE CORONARY SYNDROME, ASSOCIATED WITH COVID-19

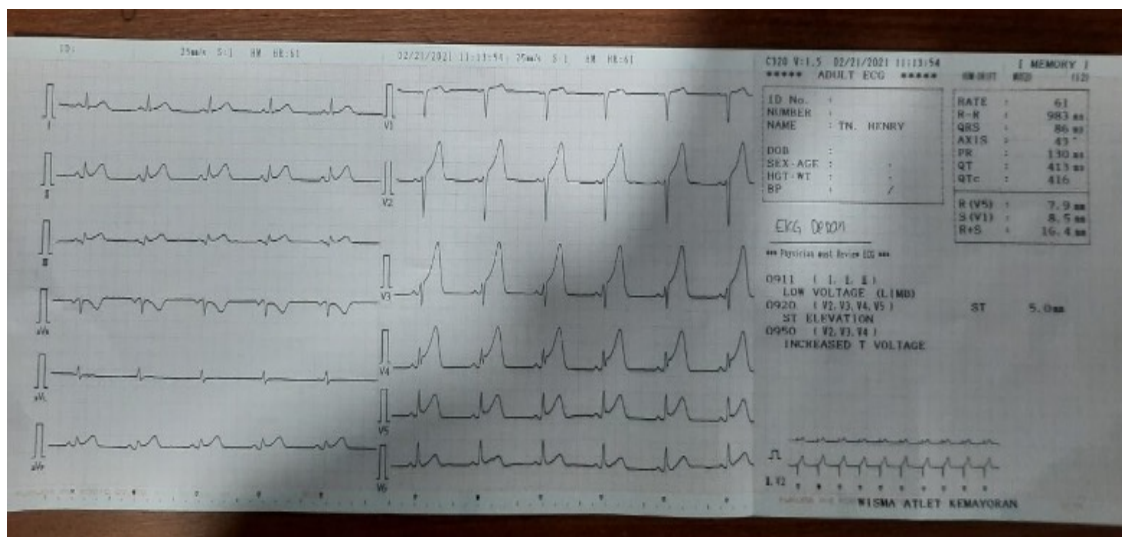
P. Habibie¹, S. Aghnia¹, C. Amalia¹
Emergency Hospital of COVID-19 Wisma Atlet Kemayoran¹

Background: Perimyocarditis is an acute inflammation involving both of pericardium and myocardium which is commonly caused by viral infection. Several investigations found that COVID-19 is much related to the perimyocarditis. Damage to the pericardium/myocardium in COVID-19 patients increases mortality and morbidity. The immediate awareness of this condition provides better treatment and prognosis.

Case Illustration: A 46-year-old male inpatient room after five days treatment as COVID-19 confirmed patient presented with angina type chest pain lasted more than 20 minutes since about 2 hours ago. It was described as squeezing and tightness in substernal area, radiating to the left arm, accompanies by cold sweats and was not improving with rest. The patient did not complain of nausea and vomiting, dizziness nor shortness of breath. Previously, chest pain had never been felt. There was no prior medical history of hypertension, diabetes mellitus, heart disease in the patient. The patient was an active smoker. Physical examination showed stable hemodynamic condition. Laboratory examination showed leucocytosis. ECG showed ST elevation in II, III, aVF, V2-V6. The patient was diagnosed with inferolateral STEMI and immediately referred to ER. The patient was treated with nitrates, antiplatelet, anticoagulant, ACE inhibitor, beta blocker, and statins. A few hours later, chest pain was not improving. The serial ECGs had been performed with no ECG evolution of STEMI was found. PR depression was also shown in the ECG. Furthermore, the patient was diagnosed with probable perimyocarditis associated to COVID-19. The patient was referred to Harapan Kita Hospital for cardiac marker, echocardiography, and coronary angiography.

Conclusion: Pericarditis as well as myocarditis can show ST segment elevation in ECG, mimicking acute myocardial infarct that can cause inappropriate treatment. Therefore, it requires proper early diagnosis to the patient.

Keywords: Perimyocarditis, myocardial infarct, COVID-19



The serial ECGs

Suspicion of Contrast-Induced Neurotoxicity following Coronary CT Angiography: A Case Report

R.Ayuningtyas¹, A. Novitasari¹, S. Inayasari¹, W. Pamungkas¹, A. Muthmaina¹, L. Pribadi¹, M.G. Suwandi¹, A. Ciptasari¹
RSPAU dr. S. Hardjolukito¹

Background: Coronary CT Angiography (CCTA) has emerged as an essential diagnostic modality for the detection and assessment of coronary artery disease (CAD). Contrast-induced headache is an important clinical entity that must be considered during and after angiography.

Case illustration: A 52-year-old male admitted to the ER with severe headache, nausea, and later vomitus. Patients was gotten CCTA with contrast and metoprolol 9 hours ago. Patient's history were recurrent headache and ACS. Patients presented with bradycardia heart rate 43. Head MSCT result was normal. Thus, patient was diagnosed with contrast-induced headache, hypoglycemia ec adrenal insufficiency, bradycardia symptomatic, CAD1VD ec APS CCS II. Patient admitted in regular ward with intensive monitoring. Patient was having history of primary headache, thus contrast-induced headache can occur but relieved with symptomatic treatment.

Conclusion: The occurrence of contrast-induced headache is common among patients with a history of primary headache. Therefore, this adverse effect was considered mild and treatable.

KEYWORD: Headache, CAD, CCTA, Coronary CT Angiography

Keywords: Headache, CAD, CCTA, Coronary CT Angiography

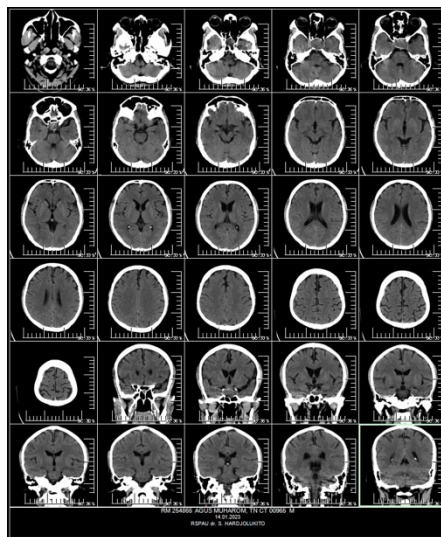



Figure 1. Patient's Head MSCT showing normal result



Diagnosis, risk stratification, and treatment in unprovoked acute pulmonary embolism: a case report

H. Martini¹, N. Kurnianingsih¹, L.H. Zunardi¹


Dr.Saiful Anwar General Hospital/ Faculty of Medicine Brawijaya University¹

Background: Pulmonary embolism (PE) are serious conditions that can be life threatening and have high rates of morbidity and mortality. Despite the high prevalence of PE, its diagnosis is still challenging, mainly due to the unpredictability of symptoms and physical signs and unexplained cause (Unprovoked PE). Risk Stratification of acute pulmonary embolism is important because it determines the right steps in decision-making.

Case Illustration: A 45-year-old man, He presented to the ER private hospital with complaints of sudden shortness of breath after taking a bath. His family brought him to the private hospital 30 minutes after its onset. At Private hospital, He came with desaturation and shock condition. He was assessed as having an acute coronary syndrome (ACS). He got loaded with dual antiplatelets and was referred to our hospital. Because the patient's complaint is not angina but sudden shortness of breath accompanied by desaturation, we did not conclude that the patient was headed for ACS. we considered the possibility of a pulmonary embolism, so we performed bedside TTE in the ER and found RV dysfunction and the McConnell's sign leading to acute PE. We continue with the CT examination and found thrombus in the pulmonary artery. we assessed patients with high risk pulmonary embolism and performed thrombolysis with rTPA. The patient's complaints gradually improved.

Conclusion: Every case of dyspnea that shows up at an emergency room should have acute PE taken into consideration in the differential diagnosis. In patients with suspected PE without obvious risk factors, we can use CT for the triple rule out (ACS, Aortic dissection and pulmonary embolism). Patients treated with thrombolytic therapy show rapid improvement which may lead to a lower rate of mortality and morbidity.

Keywords: Unprovoked, Acute Coronary syndrome, acute pulmonary embolism, shortness of breath.



Acute Stroke and Limb Ischemia Secondary to Massive Intracardiac Thrombus in a Young Female 20-Year-Old Patient with Dilated Cardiomyopathy

D. Lestari¹, C. T. Tjahjono², N. Kurnianingsih², W. Karolina, A. F. Rahimah²

¹Cardiology Resident, Faculty of Medicine Universitas Brawijaya- Saiful Anwar Hospital, Malang, Indonesia;

²Departement of Cardiovascular Medicine, Faculty of Medicine Universitas Brawijaya-Saiful Anwar Hospital, Malang, Indonesia

Background:

Dilated cardiomyopathy has been associated with left ventricular (LV) thrombosis, caused by myocardial systolic dysfunction which leads to substantial morbidity and mortality as a site for systemic emboli. We report a case of a stroke and acute limb ischemia secondary to a massive LV thrombus in a young female 20-year-old patient with dilated cardiomyopathy.

Case Illustration:

A 20-year-old female was referred to our hospital due to right lower extremities pain and right limb weakness. She was diagnosed with peripartum cardiomyopathy 5 years ago. A general physical examination found cold and pulseless in right lower limbs. From neurologic examination was found hemiparesis on the right side. Chest radiography showed cardiomegaly. Electrocardiography showed normal sinus rhythm with LVH. Transthoracic echocardiograms (TTE) revealed severe global LV systolic dysfunction with LVEF of 23%, LV dilatation with massive thrombus at LV. Duplex ultrasound showed a thrombus at the right dorsal pedis artery. A head CT scan revealed an acute infarct at capsula interna et externa sinistra and corona radiata sinistra. The patient was started on heparin and bridged with warfarin 5mg orally daily. The patient was uneventfully discharged one week after admission.

Conclusion:

The common causes of thrombus formation in the left ventricle remain ischemic cardiomyopathy, LV aneurysm, and dilated cardiomyopathy, although, it can be associated with cardiac impairment, stroke, and thromboembolic risk. The benefits of anticoagulants in patients with dilated cardiomyopathy have been reported as a reduction of thromboembolic events.

Keywords: *Acute Stroke and Limb Ischemia, Massive Intracardiac Thrombus, Young Female, Dilated Cardiomyopathy*

Successful Arrhythmia Control in Electrical Storm with Acute Coronary Syndrome and High Probability Long QT Syndrome

S. Phalguna¹, S. Andrian¹, W. Erlanda¹, H.E. Rasyid¹
RSUP dr. M Djamil Padang¹

Background: Electrical storm (ES) defined clustering of three or more episodes of ventricular tachycardia(VT)/ventricular fibrillation(VF) within 24 hours. Patient with history of myocardial infarct and channelopathies will increase risk of ES as a life threatening condition.

Case illustration: A 50-years-old male referred to emergency room with typical chest pain since 48 hours ago. Patient had seizure, unconscious, and got chest compression, patient return conscious before went to hospital. In referral hospital, patient returned seizure, electrocardiogram(ECG) showed VT unstable, patient got cardiopulmonary resuscitation(CPR), defibrillation, amiodaron bolus followed maintenance dose. In our emergency room, patient still chest pain, ECG revealed Q pathologic, ST elevation in V1-V4, T biphasic V1-V6, diagnosed with Recent ST Elevation Myocardial Infarct(STEMI) of Anterior wall, we decided primary percutaneous coronary intervention. Angiography revealed subtotal occlusion mid LAD, stenosis 70-80% mid RCA, we stenting proximal-mid LAD. Next day patient returned seizure, unconscious, monitor showed VT unstable. Patient underwent CPR and intubated caused of inadequate respiratory, we performed complete revascularization. After extube, patient felt anxiety, patient returned of seizure and was being ES. QT interval was prolong, schwartz score: 7, echocardiography revealed reduced ejection fraction. We gave lidocaine in acute phase of ES, but had no effect. We sedated, gave propranolol, patient still ES. We knockdown patient, down-titrated sedation, gave metoprolol, and optimal therapy for heart failure. Patient wasn't had ES anymore and discharged.

Conclusions: We report case 50 years old male with recent STEMI Anterior with complete revascularization and high probability LQTs. Administration of propranolol as in a recent study for ES is not always successful. In this case, the effect of metoprolol combined with sedation, anti anxiety, and optimal treatment of heart failure success for arrhythmia control. However, we should perform genetic test and cardiac MRI to find main problems of ES.

Keywords: Electrical Strom, Recent STEMI Anterior, LQTs

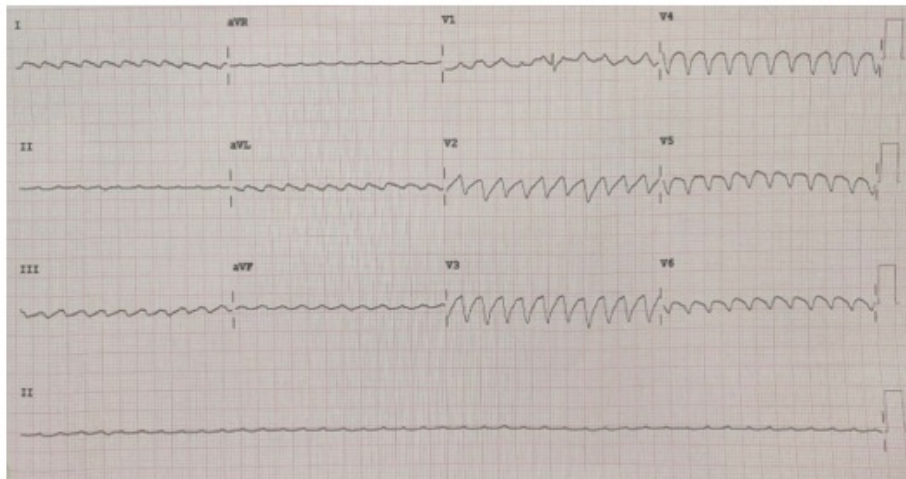



Figure 2. ECG VT

ECG patient with Ventricular Tachycardia



Diagnosis and Treatment Patent Ductus Arteriosus with Eisenmenger Syndrome in Young Adult Female

P.M. Bahri¹, C.K. Krevani²
Faculty of Medicine, Andalas University¹
Andalas University²

Background

Patent Ductus Arteriosus (PDA) is a congenital heart defect which is the ductus arteriosus failed to close spontaneously after birth. Incidence of this condition is about 6 per 10,000 in full-term infants and 1 per 3 in preterm infants. Untreated PDA leads to Eisenmenger syndrome (ES). ES patients need special consideration especially for pregnancy because of complication and maternal mortality. Risk of foetal and neonatal are higher due to maternal cardiac output and hypoxaemia.

Case Illustration

A 19 years old female presented with shorthness of breath since 1 year before admission. Patient has already been diagnosed with PDA and pulmonary hypertension. Patient was planned to did right heart catheterization (RHC) procedure. On the second day of hospitalization, patient complained that shorthness of breath was increased. From physical examination, the respiratory rate was 29 times/minute, saturation was 96% in the right upper extremity, 77% in the others with fines rales, increased second heart sound, pansystolic murmur 3/6 at left parasternalis border 3rd ICS, pretibial edema. On the 7th day, she didn't feel shorthness of breath. RHC was done on that day. RHC result was PDA with eisenmengerization, low flow high resistance, not reactive oxygen test. On the next day, she went home with therapies slidenafil 3x20 mg, furosemide 2x20 mg, spironolactone 1x25 mg, ramipril 1x2,5 mg, bisoprolol 1x2,5 mg. We explained to her and family that PDA closure is a not recommended in patient with Eisenmenger syndrome and pregnancy should be avoided.

Conclusion

PDA closure is not recommended in patient with Eisenmenger syndrome and unreactive oxygen test. Pregnancy should be avoided because of maternal mortality rate.

Keywords: Patent ductus arteriosus, Eisenmenger syndrome, pregnancy

Tackling Calcified Lesion with Orbital Coronary Atherectomy and IVUS: A Case Report

D.N. Ghassani¹, R.A. Fagi¹, Y.H. Oktaviono¹

Cardiology and Vascular Medicine Department, Medical Faculty of Airlangga University – Dr. Soetomo General Hospital, Surabaya, Indonesia¹

Background: Percutaneous coronary intervention (PCI) is a common treatment for coronary artery disease (CAD), but it may not always be effective in cases with heavily calcified lesions. Orbital atherectomy is a novel technique that uses a diamond-coated burr to ablate calcified plaque within the vessel wall. Intravascular ultrasound (IVUS) is a high-resolution imaging modality that provides detailed information about coronary anatomy, including the location and extent of plaque build-up. The combination of orbital atherectomy and IVUS has shown promising results in the treatment of heavily calcified coronary lesions.

Case illustration: Male, 56 years old, with type 2 diabetes, dyslipidemia, and chronic coronary syndrome CCS III, has a history of PCI at proximal right coronary artery (RCA) and distal left circumflex artery (LCx) in 2020. His coronary map showed diffuse calcified lesion up to 85% at left anterior descending artery (LAD). During follow-up, he was still symptomatic and he was referred to our hospital. His vitals were stable. The physical examination and ECG were unremarkable. TTE showed preserved ejection fraction (Biplane 50%) with hypokinetic segments at septal and inferior, and eccentric left ventricular hypertrophy. The patient underwent PCI at proximal-mid LAD with orbital atherectomy using Diamondback 360 Coronary OAS Micro Crown with the help of IVUS, resulting in complete revascularization.

Conclusion: The combination of orbital atherectomy and IVUS in treating calcified coronary artery disease is promising to improve outcomes. Orbital atherectomy effectively modifies calcified plaque and prepares the vessel for stent placement. IVUS provides real-time information about vessel size, plaque burden, and stent deployment, which help optimize procedural outcomes. The combination of these two techniques can improve the success rate of stent placement and reduce the risk of complications. Further studies are needed to evaluate the long-term outcomes of this approach.

Keywords: Orbital coronary atherectomy, IVUS, PCI, Chronic Coronary Syndrome

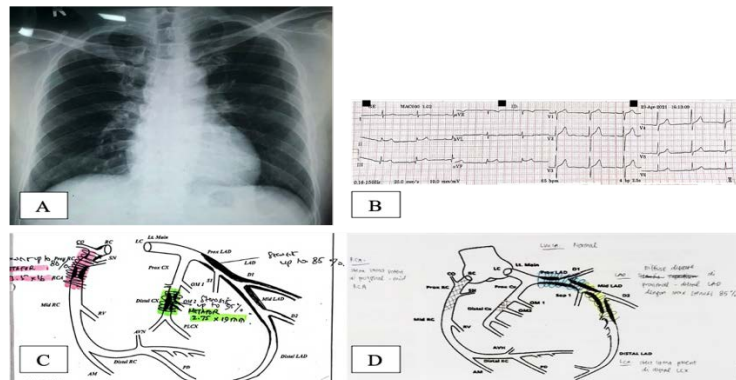


Figure 1. Chest X-ray of the patient (A); Electrocardiogram of the patient (B); Pre-procedure (C); and Post-procedure (D)

An Unusual Case of Femoral Deep Vein Thrombosis with Bullae Formation

R. Ayuningtyas¹, A. Ciptasari¹, A. Novitasari¹, W. Pamungkas², N.A. Novebri¹, M. Mohamad¹, A. Muthmaina¹,
L. Pribadi¹, M.G. Suwandi¹, S. Inayasari¹
Rumah Sakit Pusat Angkatan Udara Suardi Hardjolukito¹
Adisutjipto Air Force Base²

Background: Blood clots may be formed in deep veins, most frequently the legs, and are medically referred to as deep vein thrombosis (DVT). One of the rarest complications of DVT is a blockage of large proximal vein, likely resulting in bullae formation and blistering, which can be confused with bullous skin disorder.

Case illustration: A 63-year-old male patient in the ward complained about sudden hard swelling on his left leg that was accompanied by pain, discoloration, reduced range of movement, and multiple bullae. History of previous similar complaints, DVT, malignancy, and surgery were absent, either in the patient or his family. However, the patient has recurrent history of leg swelling after travelling long distances, and provides with grade I hypertension, obesity, and type II diabetes mellitus as risk factors. The Wells score on this patient was 5, and rising D-Dimer levels > 10.000, therefore digital ultrasound was performed with the result of total thrombus on the left femoral vein and patent flow of arteries and veins on both legs. The patient was treated with intravenous unfractionated heparin, antibiotic ointments, and saline compresses. The bullae were aspirated, and blister roof was maintained. After two weeks of treatment, swelling was reduced and no new bulla was formed. Warfarin therapy was continued on outpatient basis.


Conclusion: Bulla formation as a result of DVT is a very rare complication that must be distinguished from skin disease based on clinical findings, physical examination, and imaging. It was challenging to determine the best treatment approach since there were no clear guidelines existed. However, the principle of treatment is to continue anticoagulant therapy while keeping the blisters' roofs intact to prevent secondary infection.

KEYWORD: *deep vein thrombosis, bullae formation, blisters*

Keywords: deep vein thrombosis, bullae formation, blisters

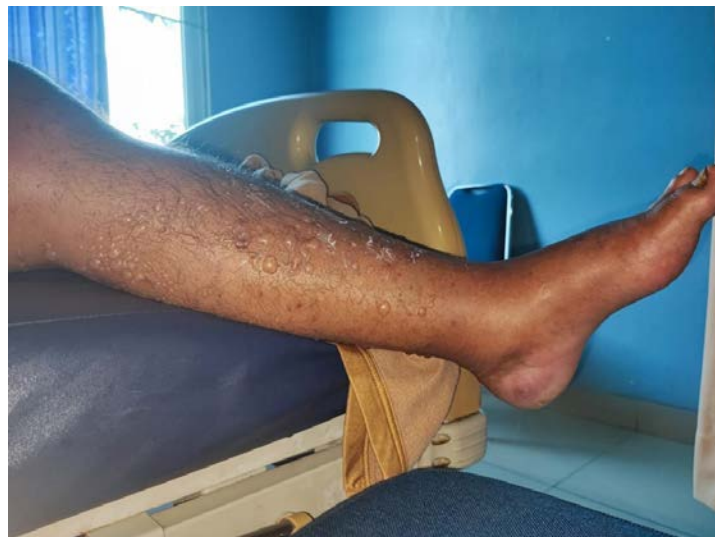

Figure 1. Bulla formation due to deep vein thrombosis



A Life-Threatening Effect of Doxorubicin: What We Should be Aware of?

D. Lestari¹, W. Karolina², A. F. Rahimah²

¹Cardiology Resident, Faculty of Medicine Universitas Brawijaya- Saiful Anwar Hospital, Malang, Indonesia

²Departement of Cardiovascular Medicine, Faculty of Medicine Universitas Brawijaya-Saiful Anwar Hospital, Malang, Indonesia

Background:

Anthracyclines such as Doxorubicin is an antibiotic with a broad spectrum of activity in human neoplasms that have demonstrated an increased risk of HF and cardiomyopathy with significant morbidity and mortality. We present a case report of a patient on going chemotherapy with breast cancer treated with Doxorubicin who presented with symptoms of AHF.

Case Illustration:

A 37-year-old female patient with left-sided breast cancer on going chemotherapy presented with progressively worsening shortness of breath and worsened exercise tolerance for the past 1 month. On May 2022, her breast cancer was treated with chemotherapy including doxorubicin and cyclophosphamide. On physical examination was found bilateral crackles with jugular venous distention and lower extremity edema. Electrocardiography showed sinus tachycardia. Laboratory findings were elevated N-terminal pro-brain natriuretic peptide (NT-proBNP). Transthoracic echocardiograms (TTE) pre-chemotherapy showed normal LV systolic with LVEF 68% by biplane, global normokinetic. TTE after 4 months revealed diffuse left ventricular hypokinesis, left ventricular ejection fraction (LVEF) of 22%, and reduced right ventricular contractility. Given the clinical presentation, the patient was treated for acute heart failure and was admitted to the Cardiac Intensive Care Unit. The patient got ventilator support, loop diuretic and inotropes/vasopressors.

Conclusion:

We should be aware of the effect of doxorubicin that induces cardiomyopathy. It typically presents earlier. Prevention and management of doxorubicin-induced cardiotoxicity involve a multidisciplinary approach that entails careful assessment of cardiac function.

Keywords: *Doxorubicin, Cardiomyopathy, Breast Cancer*

Cervical Angina: Kindly Reminder that not All of Angina Come from the Heart

I. Fauzie¹, D. Arara¹
Primaya Hospital Depok¹

Background:

Cervical angina has been defined as chest pain that resembles true cardiac angina but originates from the disorders of the cervical spine. Cervical angina can be diagnosed according to negative cardiac workups, positive neurologic examination, and cervical radiographic findings. Cardiac imaging examination with coronary CTA should be the primary imaging test to define the possible cause of angina which it has high overall sensitivity about 95.2%.

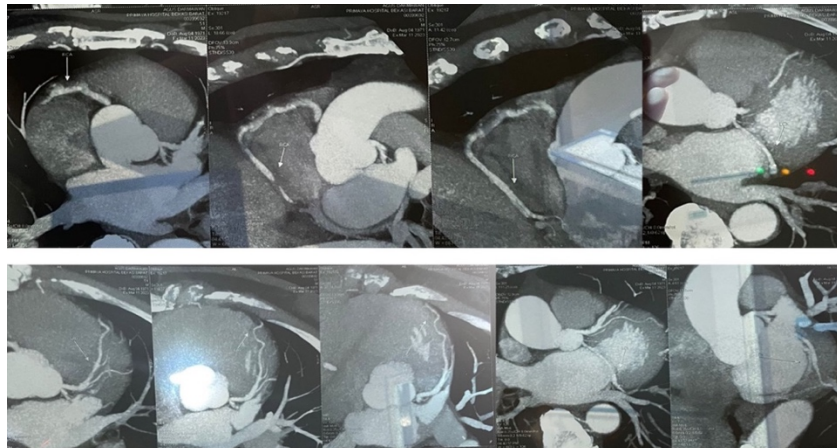
Case Illustration:

A 51-year-old man was admitted to ER with chest pain since 7 hours before admission, felt like squeezing, wasn't accompanied by dyspnea or palpitation. It already felt since a day before admission, then getting worse in the next hours. Six months ago, he reported a similar condition and underwent TMT with normal result. He was smoker and had hypertension and dyslipidaemia. Physical finding was unremarkable. An ECG revealed sinus tachycardia, LAD without ST-T changes, Troponin I was 0.01 ng/ml. CXR showed found cardiomegaly. Patient was diagnosed as UAP. We administered DAPT, statin, beta-blocker, anticoagulant, nitrate and transfer him to HCU. ECG serial revealed no evolution. Echocardiography showed LVEF 65%, global normokinetic, LVH, mild AR. In the 2nd day, chest pain was slightly relieved but he complains neck stiffness with intermittent hypesthesia on left arm. In the 3rd day, we performed CCTA with result minimal plaque burden and stenosis at LAD & RCA. We consulted the patient to neurologist then was performed Cervical X Ray with result spondylosis cervicalis. We stop nitrate and patient was administrated with mecobalamine and eperisone. In the 4th day, the complaint was relieved and discharged from the hospital.


Conclusion:

Coronary CTA is a modality of choice to define angina causes in low risk patient. Cervical angina is one of possible diagnosis after rule out the cardiovascular cause.

Keywords: cervical angina, coronary ct angiography, cardiac imaging



The coronary CTA showed minimal plaque burden and stenosis at LAD and RCA



The Deadly Silent of Atrial Fibrillation with Total Atrioventricular Block : A Case Report.

C.F. Montang*; P. Jeremiah**; Hassanuddin**; V. Chairidi***

*Intern in Cardiology and Vascular Medicine Departement, Undata General Hospital, Palu

**Cardiologist in Cardiology and Vascular Medicine Departement, Undata General Hospital, Palu

***Cardiologist, Head of Cardiology and Vascular Medicine Departement, Undata General Hospital, Palu

Background :

Atrial fibrillation and total atrioventricular block are two different type of arrhythmia. Although the two arrhythmias can co-exist. Atrial fibrillation (AF) is a most common type cardiac arrhythmia characterized by uncoordinated and dyssynchronous atrial contraction resulting in irregular and often rapid excitation. Total atrioventricular (AV) block is the complete dissociation between the atrium and the ventricle. There is limited cases had been reported of AF with total AV block, can make a misinterpreted. A correct recognition is essential due to the risk of sudden cardiac death.

Case Illustration :

A 63-year-old man patient presented with dyspnea and fatigue. His symptom were consistent with a class 3 New York Health Association cardiac function. His blood pressure was 140/80, heart rate 33/beats, auscultation of the chest revealed murmur. ECG showed absences of P waves with a regular QRS complexes. Echocardiography showed MR severe, TR moderate intermediate probability of PH, EF 62%, TAPSE 1,94cm. LVH (+) concentric, diastolic dysfunction (+). The patient was given a sulfas atropine 0,5mg injection, dopamine 5cc/hours up titration, furosemide 40mg 1x1, spironolactone 25mg 1x1, candesartan 4mg 1x1 and simarc 2mg 1x1. After administration of atropine sulfate and dopamine intravenous injection the heart rate increased to 62/beats.

Conclusion :

Electrocardiography is a diagnostic for co-existing AF with total AV block, a correct diagnosis will provide initiation of definitive management.

Keywords: Atrial fibrillation, total av block, bradycardia, sudden death

Rapid Management of Unstable Bradycardia Reveals Inferoposterior STEMI and Hyperkalemia: A Case Report

K.A. Fitra¹, K.A. Hasyaputra¹, P.S. Bustanul²

General Practitioner, Royal Prima Hospital, Jambi, Indonesia¹

Departement of Cardiology and Vascular Medicine, Royal Prima Hospital, Jambi, Indonesia²

Background: Sinus bradycardia is a common arrhythmia in patients with inferior or posterior acute myocardial infarctions (AMIs). Sinus Bradycardia is unstable when is associated with hypotension or shock, slower heart rates, changeable morphology of the P wave. The incidence of bradyarrhythmias in patients with ACS is 0,3% to 18%.

Case Illustration: A 49-year-old man complained of typical angina 1 hour before admission. Vital signs show hypotension (75/39 mmHg), severe bradycardia (27 beats/min) and RR : 40 breathes/min. An ECG revealed junctional bradycardia and prolonged QT interval . Junctional bradycardia can be caused by hyperkalemia, and according to laboratorium examination, hyperkalemia is caused by Acute Kidney Injury. Bradycardia improved after administration of dopamine and CA Gluconate, but the patient still complained of chest pain, so a repeat ECG examination was performed which showed the results Atrial Fibrillation Normal Ventricular Response with ST-Elevation in the inferoposterior and right leads (**Figure 1**). The patient was diagnosed with Inferoposterior STEMI with Right Ventricular infarction and AF NVR exacerbated by Cardiogenic Shock and Hyperkalemia ec Acute Kidney Injury. It can be stated that the greatest possibility of bradycardia is caused by acute myocardial infarction and electrolyte disturbances in the form of overlapping hyperkalemia, so PCI management is needed. The patient received DAPT and statins as management for STEMI before being referred to Primary PCI.

Conclusion: Early identification of STEMI and potential complications, including bradycardia, is necessary for proper care of the chest pain patient. It is imperative that the EM physician continues to remain up to date with management of the unstable patient with STEMI and be prepared to intervene if complications arise.

Keywords: Bradyarrhythmias, Myocardial Infaction, Hyperkalemia

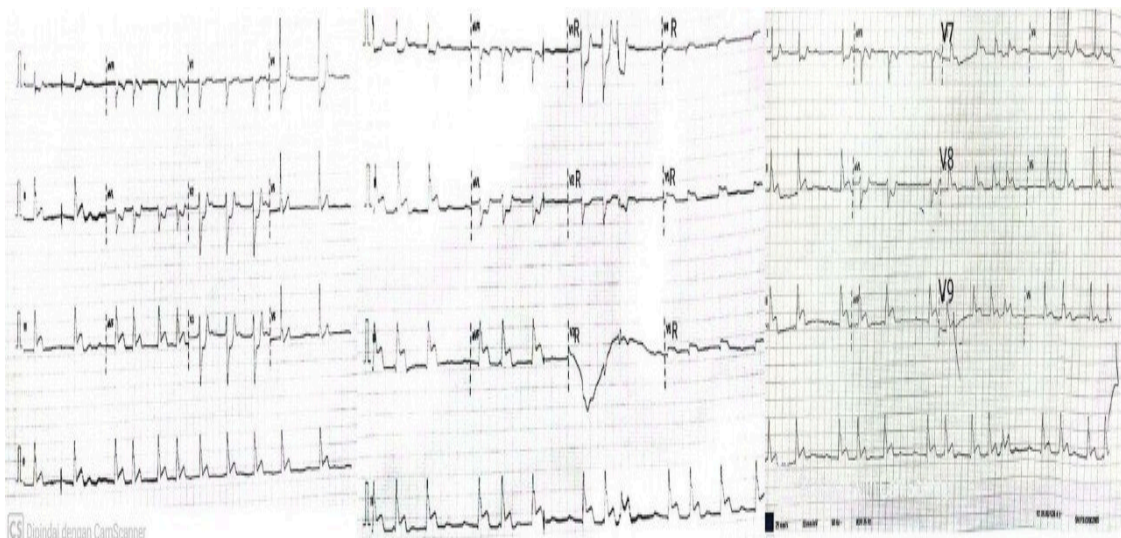


Figure 1. ECG shows ST-Elevation in inferoposterior and right leads after the bradycardia was resolved.

Management of Acute Coronary Syndrome in Limited Resource Setting: a Case Series

V. Calosa¹, M. Valeria², N. Dewi³

General Practitioner, Bajawa Public Hospital, East Nusa Tenggara, Indonesia¹

General Practitioner, Inerie Public Health Center, East Nusa Tenggara, Indonesia²

Department of Internal Medicine, Bajawa Public Hospital, East Nusa Tenggara, Indonesia³

Background: Acute coronary syndrome (ACS) is a spectrum of coronary heart disease (CHD), which includes ST-elevation myocardial infarction (STEMI), non-ST elevation myocardial infarction (NSTEMI), and unstable angina. Prevalence of CHD in Indonesia is 1.5% based on the 2018 Indonesia Baseline Health Research. It is estimated 12.9% of deaths in Indonesia is caused by CHD based on the Sample Registration System survey in 2014. Classic symptom of ACS, substernal pressure-like chest pain that radiates to the jaw and/or left arm, does not always present. Often, other symptoms such as difficulty breathing, light-headedness, isolated jaw or left arm pain, nausea, epigastric pain, diaphoresis, and weakness present instead of the classic symptoms. The main treatment is to achieve reperfusion, either by fibrinolytics or percutaneous coronary intervention (PCI). In rural area, treating patients with ACS in the unavailability of reperfusion therapy might be challenging. Hereby we present a case series of four patients with ACS treated in limited-resource settings.

Case Illustration: A sixty-nine-year-old man (Patient A), a seventy-six-year-old woman (Patient B), a sixty-two-year-old woman (Patient C), and a forty-one-year-old man (Patient D) were admitted with complaints of typical chest pain. A history of hypertension or dyslipidemia were noted in all patients. Electrocardiogram (ECG) findings were elevated ST-segments (Patient A, C, D) and flattened/inverted T-waves (Patient B). Reperfusion therapy was unavailable, thus we administered a loading dose of aspirin and clopidogrel followed by a maintenance dose, heparin infusion of 10,000 units/day for three days, isosorbide dinitrate, bisoprolol, and atorvastatin. Improved conditions and ECG findings were achieved within three-to-four-day hospitalization. Patients were referred to have coronary angiography and further management.

Conclusion: In limited-resource settings where reperfusion therapy is unavailable, heparin infusion of 10,000 units/day with a loading dose of aspirin and clopidogrel followed by maintenance therapy may improve the patient's conditions and ECG findings.

Keywords: acute coronary syndrome, limited resource, heparin infusion, reperfusion, rural area

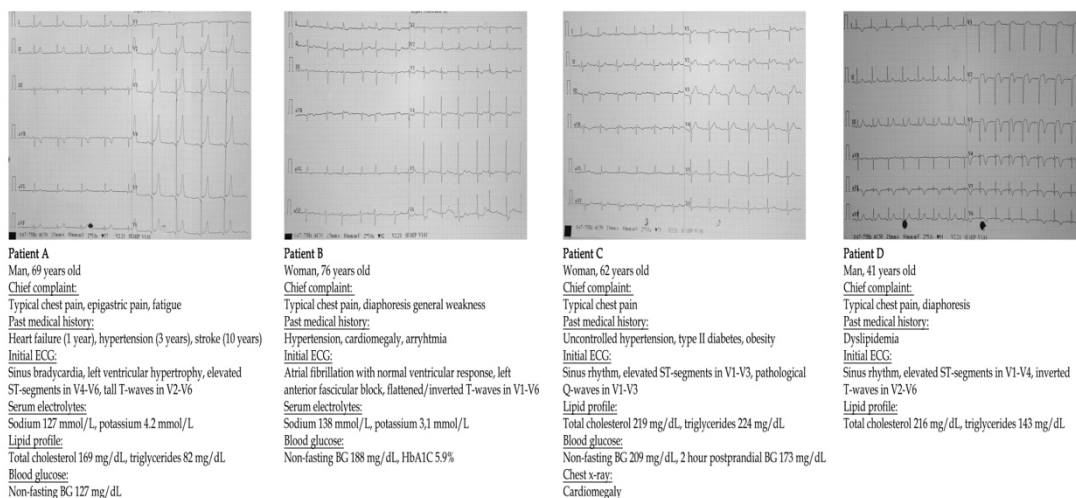



Figure 1. Clinical, electrocardiogram, and laboratory findings regarding four patients in the case series



Mitral Annulus Calcification: When It Came with Many Disturbances

D. Azhari¹, F. Yuliani², M. Yanni³

Cardiology and Vascular Medicine Residency, Andalas University, Padang, West Sumatera¹

Cardiology and Vascular Medicine Residency, Andalas University, Padang, West Sumatera.²


Cardiology and Vascular Medicine Department, M. Djamil Hospital, Padang, West Sumatera³

Background: Mitral Annulus Calcification (MAC) is a mitral valve degenerative disorder. Prevalence of MAC is between 8% and 15%, but it significantly increases with age and in patients with multiple cardiovascular risk factors. MAC is associated with increased risk of atrial fibrillation, enlargement of left atrium, increased rate of cardiovascular disease, and mortality.

Case illustration: A 71-years old male presented with shortness of breath increased 1 day before admission. The patient has a history of 2-day watery diarrhea, cough, and fever. Patient was an excessive smoker. Physical examination showed irregular pulse, increase of jugular venous pressure, opening snap and mid diastolic murmur on auscultation, and ankle oedema in both lower extremities. Electrocardiogram demonstrated atrial fibrillation with normal ventricular response. Laboratory results showed thrombocytopenia, prolonged INR, hypoalbuminemia, and electrolyte imbalance. Transthoracic echocardiography revealed decreased LV systolic function EF 39%, severe mitral stenosis, moderate mitral regurgitation ec MAC, left and right atrium dilation, and concentric left ventricular hypertrophy. The patient was assessed with community acquired pneumonia, gastroenteritis acute, hematuria, and suspected cardiac cirrhosis. Patient was treated with optimization of heart failure therapy, treatment of infection, vitamin K therapy, correction of hypoalbuminemia and electrolyte imbalance. After six days hospitalized, the patient was discharged with stable condition. Patient was planned to have mitral valve replacement but refused and choosed optimal medical therapy.

Conclusion: MAC is often clinically silent but can be symptomatic depending on severity of the mitral valve disease. Infection can lead to acute heart failure presentation on this patient. Treatment of precipitant and comorbidities will reduce days of hospitalization.

Keywords: Mitral Annulus Calcification



Two Phenotypes of Cardiac Amyloidosis Presenting in a Single Patient: A Case Report

M.R.R. Natadikarta¹, N.Y. Kusumawardhani¹, H.S. Prameswari¹

Department of Cardiology and Vascular Medicine, Faculty of Medicine, Universitas Padjadjaran, Bandung, Indonesia¹

Background

Increase of ageing population and emerging cardiovascular disease updates may impact on conditions that previously underdiagnosed are being increasingly identified. Cardiac amyloidosis is a rare, multiorgan disease characterized by deposition of insoluble amyloid fibrils throughout tissues and organs. This case of light chain (AL) amyloidosis presenting with highly clinical suspicion of amyloidosis, comprehensive evaluation on patient with high suspicion of infiltrative disease plays pivotal role for its diagnosis.


Case Illustration

A 57-years-old male admitted with shortness of breath without any chest pain. On initial physical examination, his blood pressure was 80/52 mmHg with heart rate of 84x/min. He presented with elevated jugular venous pressure, rales, gallops, cool extremities, and bilateral pitting edema. He also had several skin bruises around the trunk and extremities. ECG reveals sinus rhythm, poor R wave progression, and low voltage. Chest X-ray shows cardiomegaly, pulmonary edema with right pleural effusion. Lab findings shows high level of NT-pro BNP and creatinine. Echocardiography results was suggestive of cardiac amyloidosis with concentric LVH, reduced LVEF, LV diastolic dysfunction grade III, mild functional mitral regurgitation, mild pericardial effusion, typical LV granule myocardial sparkling pattern and apical sparing bull's eye pattern (cherry on top) on GLS. We performed further workup cardiac MRI results consistent with cardiac amyloidosis, scintigraphy shows grade 3 cardiac uptake, and serum free light chain (sFLC) test was abnormal with IgA Lambda oligoclonal gammopathy on immunofixation electrophoresis. For final diagnosis, we perform endomyocardial biopsy the result was positive on congo red staining, confirming diagnosis of amyloid monoclonal immunoglobulin light chain cardiomyopathy (AL-CM).

Conclusion

AL-CM with grade 3 scintigraphy was extremely rare. This case highlights the critical importance of ruling out AL amyloidosis in all patients with positive uptake on scintigraphy to ensure such patients are not assumed to have transthyretin (ATTR) cardiac amyloidosis.

Keywords: cardiac amyloidosis, cardiomyopathy, endomyocardial biopsy, infiltrative disease



The Outcome of Femoropopliteal and Infrapopliteal Percutaneous Transluminal Angioplasty for The Management of Chronic Limb-Threatening Ischemia

A.I. Nurudinulloh¹, A.J. Firdaus¹, N. Kurnianingsih²

Resident of Cardiology and Vascular Medicine, Faculty of Medicine, Universitas Brawijaya, Malang, Indonesia¹

Department of Cardiology and Vascular Medicine, Vascular Division, Saiful Anwar General Hospital, Malang, Indonesia²

Background

CLTI is a highly morbid disease, causing significant mortality, limb loss, pain, and diminished quality of life among those afflicted. The CLTI outcomes depends on primary and secondary care. PTA is widely used to improve blood flow and quality of life in CLTI patients.


Case Illustration

A 61 y.o man, who had CABG procedure due to CAD and left leg amputation due to irreversible ischemia, presented with resting pain and open wound on his right foot since 6 months ago. Duplex Ultrasound and CT Angiography showed diffuse significant stenosis and calcified appearance with Wifi stage II and GLASS stage II. Patient was performed PTA with DEB at femoropopliteal artery, then blood flow returned to normal and many collateral infrapopliteal arteries appeared. One day prior to treatment, open wound healed and resting pain disappeared. Second patient, A 78 y.o high-risk man was admitted to hospital with unhealing gangrenes at left foot since 2 months ago and resting pain in both legs dominant in the right. Doppler ultrasound examinations showed abnormal ABI and abnormal flow at left infrapopliteal artery. Patient who also had Wifi stage II and GLASS stage II was performed Angiography and PTA procedures at femoropopliteal and infrapopliteal arteries. Necrotic wound at left foot started healing and pulse started to be detectable. Both patients were given wound care management dan multidiscipline approach to control risk factors.

Conclusion

Revascularization is the appropriate decision for limb saving in CLTI patients to restore blood flow, reduce ischemic burden, and optimize wound healing, which ultimately improves quality of life. Either PTA femoropopliteal or infrapopliteal promises a similar wound-healing quality.

Keywords: CLTI, wound healing, PTA



Case Series Report: Ultrasound-Guided Compression Repair (UGCR) as a Non-Invasive Treatment of Pseudoaneurysms Complication of Catheterization in Dr. Saiful Anwar General Hospital Malang

N. Kurnianingsih¹, A. Christine¹
RSUD Dr. Saiful Anwar Malang¹

Background:

A pseudoaneurysm (PSA) is a locally-contained hematoma outside an artery due to damage to the vessel wall which is also recognized as a false aneurysm. Over years, PSA incidence has improved in ranges from 0.2% to 8% since the catheterization procedures are commonly used by various specialties. A significant complication in the form of femoral artery pseudoaneurysm is undergone by patients with diagnostic or therapeutic catheterization. Ultrasound is the quickest and best modality for assessment. Ultrasound can also be used for therapeutic probe compression known as Ultrasound-Guided Compression Repair (UGCR).

Case illustration:

Three patients have complained of swollen and pain around groin area after catheter removal. They were stable angina pectoris patients undergoing diagnostic and/or therapeutic catheterization. UGCR was performed to all of them. The first UGCR was successfully performed to a 66-year-old woman. The second one performed to a 76-year-old woman was not successful but the PSA resolved on its own. The last UGCR was also unsuccessful to a 75-year-old man and the PSA did not resolve but it was eventually successful after being managed by surgery. Generally, factors require the technical success consisting of the ability of patients to tolerate prolonged compression, the skill of examiners to control the hand fatigue and the PSA itself.

Conclusion:

UGCR is a treatment that highly identified as a valid alternative, safe and cost-effective for patients with catheter-related femoral pseudoaneurysms and a normal coagulation profile. It is non-invasive and easier to perform than percutaneous and surgical repair. The success rate reaches 75% to 98%. Follow-up duplex scans are usually performed three to seven days after successful treatment. Further treatment may be suggested if the pseudoaneurysm is not completely removed by UGCR treatment.

Keywords: pseudoaneurysm, ultrasound-guided compression repair

Clinical Presentation of MINOCA in Female with Thyroid Cancer Post Thyroidectomy ; A Case Report

Hanifah¹, A. Puryani¹, I.H. Siahaan²

General Practitioner, Persahabatan Central General Hospital¹

Cardiologist, Persahabatan Central General Hospital²

Background: Myocardial infarction with non-obstructive coronary arteries (MINOCA) happens in 5-10% of all myocardial infarction (MI), and one third of these patients have ST-segment elevation in ECG. Patients with MINOCA were found having cancer more frequent than MI and obstructive coronary artery disease (MI-CAD). In cancer patients, ST-segment elevation is more likely to be found in MINOCA rather than MI-CAD. Also, MINOCA predominantly happens in females and younger patients. In this report we present the distinct characteristic of MI in cancer patient.

Case illustration: A 53 year old woman with thyroid cancer post total thyroidectomy presented to emergency room due to chest pain 6 hours before admission. The patient had hypertension and no history of anti-cancer therapy. The physical examination showed high blood pressure, tachycardia, tachypnea, desaturation, and bibasilar crackles in lungs. The electrocardiograms showed ST elevations in leads V1-V6, I and aVL. Laboratory test showed elevation of troponin I Hs 1306,6, and CKMB 84,9. The echocardiography showed Regional Wall Motion Abnormality (RWMA) : hypokinetics in mid-basal anterior-anteroseptal-inferoseptal-inferior, mild aortic and moderate mitral regurgitation, and ejection fraction 42 %. The patient was initially diagnosed with extensive anterior STEMI Killip class 2 and got loading dose of dual antiplatelet, nitrat sublingual, statin, and heparinization. After underwent the primary PCI, no significant stenosis coronary lesion to be found. Patient was treated conservatively.

Conclusion: MINOCA is frequently happened in cancer patients due to either the cancer-related processes or the side effect of therapies. In comparison with MI-CAD, MINOCA patients are more likely to be younger and female. Recognition of the MI characteristic in cancer patients is essential to decide the proper treatment and prevention.

Keywords: MINOCA, Cancer, STEMI

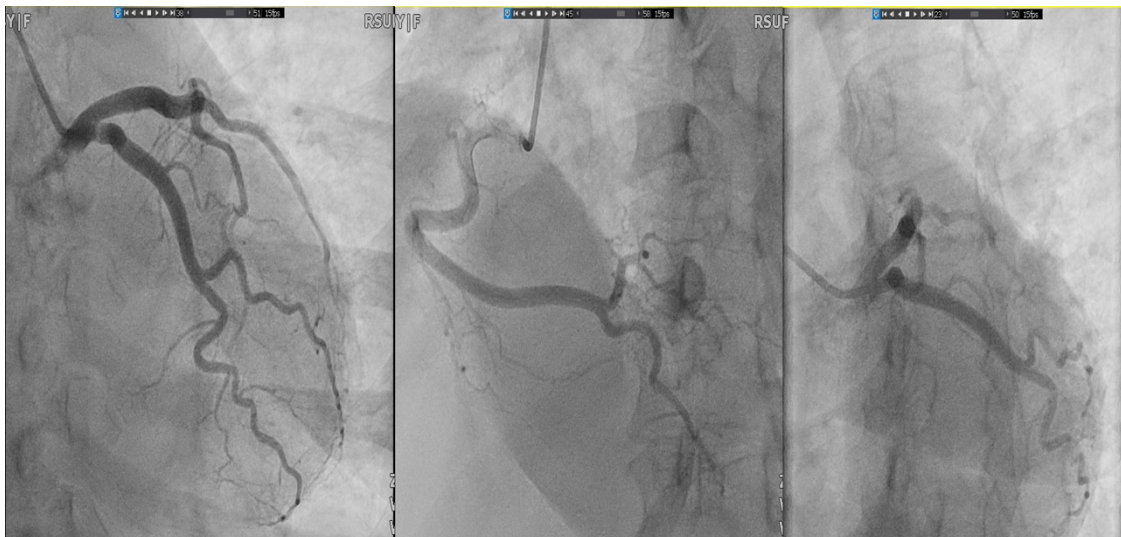

Figure 1. Coronary angiography showed normal coronary arteries

Myocardial Dysfunction in Ketoacidosis: Myocarditis or Secondary Dysfunction due to Severe Acidosis?

M.M. Sari¹, D. Arara¹
RSU Bunda Margonda¹

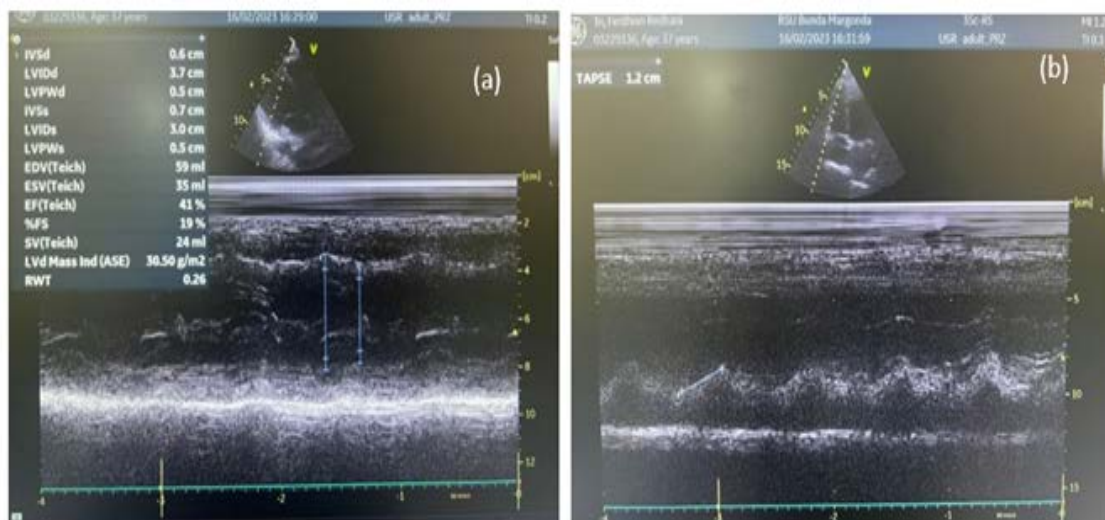
Background: Acidosis is one of the major consequences of hemodynamic instability associated with multiple organ failure and death. Most studies on the hemodynamic consequences of acidosis have been experimental, and thus far from the most common clinical situations. Myocarditis, and later myocardial dysfunction, in acidosis patients were reported in previous publication on 1996 and 2009.

Case Illustration: A 37-year-old man was admitted to Hospital with acute onset of chest pain accompanied by shortness of breath, palpitation, vomiting, sweating since 5 hours before admission. The patient had history of diabetes, dieting for two weeks and not taking his medicines regularly. From PE were found diaphoresis and tachycardia with BP 130/80, HR 150 bpm, RR 32x/m. His ECG in ER showed Sinus Tachycardia with HR about 150 bpm. The laboratory tests showed pH 6,91; pCO₂ 16.0 ;HCO₃ 3.2, with RBG 611 mg/dL and ketone urine 4+. Echocardiography showed EF was 41%, with global Hypokinetic, reduced RV contractility, and ERAP 15. The next lab exam showed increased CRP and ESD levels. Unfortunately myocardial biopsy couldn't be performed in out hospital. We suggest the patient had a myocarditis dd/ global myocardial dysfunction due to severe acidosis. Patient's consciousness was deteriorated then being intubated and admitted to ICU. Patient was administrated with ramipril, spironolactone, dapagliflozin for heart failure and then corrected the ketoacidosis condition with insulin and sodium bicarbonate. In 3 days, the echocardiography evaluation showed the increased of EF from 41% to 60%, TAPSE 1.2 to 1.7 with stable hemodynamic condition then he was extubated. Patient was discharged in the 7th day of hospitalization in stable condition.

Conclusions

The underlying pathology of Myocarditis and Myocardial dysfunction in acidosis patient remains unclear. Multiple mechanism might play a role. Acidosis can cause cardiac contractile dysfunction and cause injury on the cellular level then lead to myocardial dysfunction.

Keywords: Myocardial dysfunction, Myocarditis, Acidosis



Picture 1. (a) Echocardiography showed EF was 41%, with global Hypokinetic. (b) Echocardiography showed TAPSE was 1.2.

Acute Aortic Syndrome in Suspected Marfan Syndrome: A Neglected Case in Rural Area

K. Luthfiyah¹, M.R.M.P. Sinurat¹
Cileungsi General Hospital¹

Background.

Acute aortic syndromes are a life-threatening medical condition, including acute aortic dissection (AAD), intramural hematoma (IMH) and penetrating atherosclerotic aortic ulcer (PAU). Disruption of the media layer of the aorta is the common feature.¹ Most patients in AAD are male, aged >70 years, presents with systemic hypertension, atherosclerosis and iatrogenic causes, whereas Marfan syndrome is seen predominantly in younger patients.² In Marfan syndrome, the connective tissue disorder which caused by heterozygous mutations in FBN1, leads to progressive aortic dilatation, thus increasing the risk of acute aortic dissection, with the incidence ranges from 8.4% to 18%.³⁻⁵ It is important to recognize Marfan Syndrome early to provide appropriate treatment to prevent life-threatening complications.

Case Illustration.

A 17-year-old male presented with chest pain accompanied by shortness of breath since 3 days before admission. Physical examination showed increased arm-span to height ratio (>1.05) with arachnodactyly, positive wrist and thumb signs, pectus carinatum and ectopia lentis. The patient was afebrile, tachypneic and had wide pulse pressure. An early diastolic murmur high pitched grade 2/4 at upper right sternal border was found. Electrocardiography showed sinus tachycardia with lateral wall ischemia and Left Ventricular Hypertrophy. Chest x-ray showed cardiomegaly. Bedside echocardiography documented an intimal flap in the proximal ascending aorta and aortic root, suggestive Stanford Type A AAD. The patient was then referred to National Cardiovascular Center Harapan Kita Hospital to undergo surgical treatment.

Conclusion.

Diagnosing acute aortic syndrome in early-stage Marfan syndrome is quite difficult due to absence of typical features and lack of resources. This circumstances can lead to under-diagnosis which increase mortality rate. Surgical treatment is still the mainstay of management for Stanford Type A AAD and needed to reduce mortality rate.

Keywords: Acute Aortic Syndrome, Aortic Dissection, Marfan Syndrome, Bentall Procedure

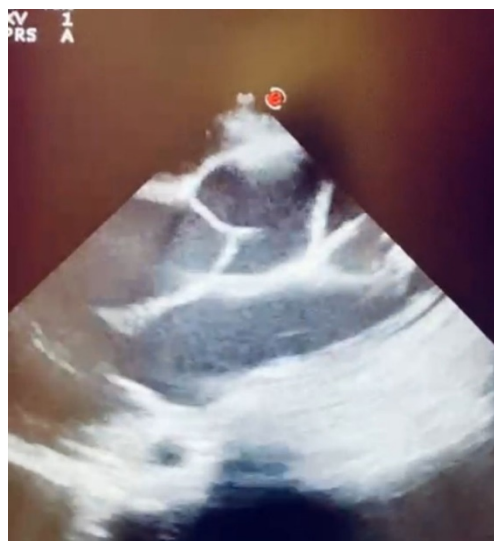

Figure 1: Echocardiography documented an intimal flap in ascending aorta

Tetralogy of Fallot With Labiopalatoschiziz : Let's Total Correction or Not?

F.H. Alkaf¹, A. Priyatno²

Faculty of Medicine, Diponegoro University, Semarang, Indonesia¹

Department Cardiology and Vascular Medicine, Kariadi Hospital, Semarang, Indonesia²

Background :

Tetralogy of Fallot is the most common cyanotic heart defect with an incidence of 5% to 10% of all CHD events. The four hallmark features of the malformation that consists of an interventricular communication, also known as a ventricular septal defect, obstruction of the right ventricular outflow tract, override of the ventricular septum by the aortic root, and right ventricular hypertrophy.

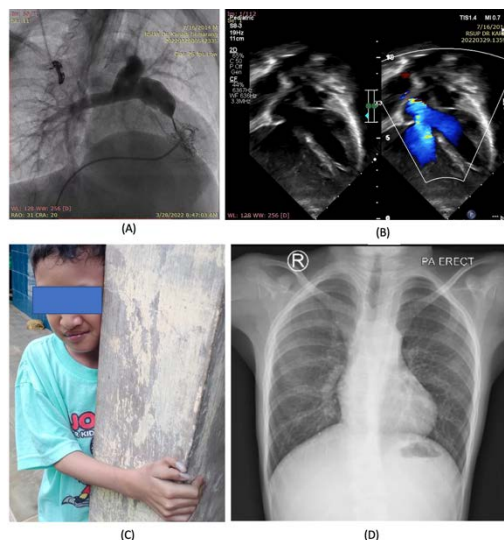
Case Illustration :

An 8-year-old boy with Tetralogy of Fallot, polydactyly, history of 3-step surgery to the correction of labiopalatoschiziz. With chief complaints of cyanotic, the body weight is difficult to gain, get tired easily, have speech disorders, and tend to squat in daily life as well. Saturation oxygen was 66%/65%/71%/74%. S1 normal, S2 weakened, systolic ejection murmur grade III/6 with punctum maximum at the left parasternal line SIC II. With nutritional status 16.5 kg, 117 cm, WAZ: -3.54, HAZ: -2.06, BMI: -3.42. Impression: Poor nutrition, very less weight. Laboratory haemoglobin 21.8 g/dL and hematocrit 68.7%. Chest x-ray CTR 48%, booth shaped, narrowed retrosternal space, RV cardiomegaly. EKG Sinus rhythm, 81x/min, RAD, RVH. Echo results: overriding aorta <50%, VSD malalignment, RV hypertrophy, severe PS with PG 75 mmHg. He was a successful total correction procedure and the condition was improved.

Conclusion :

The management of patients with TOF has its own challenges both for diagnosis and management because not all areas have adequate human resources or equipment. It is now expected that the prognosis of TOF patients will improve substantially because of the advances in surgical and medical management that have occurred over the last few decades. The decision to proceed with total correction or not depends on various factors such as the severity of the condition, the age of the patient, the presence of other health issues, and the risks and benefits of the surgical procedure.

Keywords: Tetralogy Of Fallot, Labiopalatoschiziz, Malnutrition, Total Correction



) Pulmonic Stenosis by Angiography, (B) Echocardiography with VSD malalignment, (C) Labiopalatoschiziz and Polydactyly, (D) Booth shaped by Thorax Xray

Incidental Non-Cardiac Findings of a Cardiac CT angiography : Should We Only Concentrate on the Heart?

A.P. Febrianto¹, H. Arifianto¹

Department Cardiology and Vascular Medicine, Sebelas Maret Hospital¹

Background:

Cardiac CT angiography (CTCA) examinations frequently include the calcium score, which is a highly effective predictor of coronary heart disease events. A small field of view that is focused on the heart is typically used for CTCA tests. Coronary artery calcification and aortic calcification share similar risk factors, including advanced age and hypertension, they both require screening. By acquiring a larger field of view, they can be obtained simultaneously using a CT Angiography and commonly diagnosed incidentally during imaging for other indications.

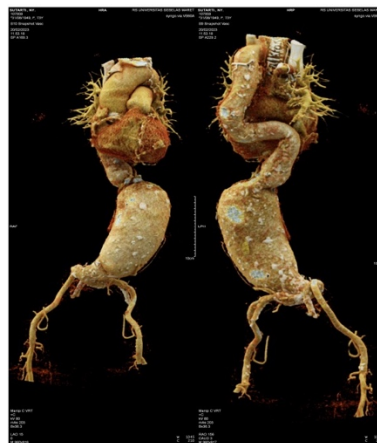Case illustration:

74-year-old woman, with intermediate likelihood of significant coronary artery disease presented with atypical chest pain was referred for CTCA. The physical examination revealed a firm, pulsatile abdominal mass. She had documented history of hypertension, dyslipidemia and no known history of aortic aneurysm. To evaluate abnormality in abdominal aortic, we decided perform larger field of view, by using run-off computed tomography angiography (CTA) with region of interest (ROI) set of images over bifurcation of abdominal aorta. Then patient undergoing CTCA, the result was CACS 2559.4 dan AAS >10.000, with moderate stenosis at shaft LM and mid LAD due to calcified plaque. Incidentally, CTA abdominal aorta demonstrated a massive, tortuous and fusiform aneurysm of the abdominal aorta measuring up ostial aneurysm diameter of 1.77 cm, distal 2.15 cm, widest diameter 7.74 cm and 18.26 cm in the transverse diameter infrarenal arteries and extending to the aortic bifurcation with extensive calcification.


Conclusions:

This case report emphasizes the usefulness of CTCA with large field of view as a screening technique for identifying incidental non-cardiac abnormalities with the same risk factor.

Keywords: Abdominal Aortic aneurysm, Cardiac CT angiography



Giant, Tortuous and fusiform aneurysm of the abdominal aorta



Left main coronary artery occlusion following diagnostic coronary angiography : A disaster in the cath lab

A. Trissatharra¹, Y.H. Oktaviono¹

1.Department of Cardiology and Vascular Medicine, Faculty of Medicine, Airlangga University / Dr. Soetomo Hospital Surabaya

Background

Left main coronary artery closure during DCA is a rare but catastrophic event with a poor prognosis. Emergency reperfusion of the LMCA with hemodynamic support should be the primary goal in this setting. We describe a patient with LMCA disease that developed acute chest pain and pulse VT and was treated with an emergency LM stenting.

Case Illustration


A 58-year-old man was admitted for an elective DCA, having reported episodes of chest pain and dyspnea on light exertion within a few months prior. His past medical history included dyslipidemia, TIA, and smoking. From the ECG, an anteroseptal OMI was observed and echocardiography showed hypokinetic anterior segment. DCA was performed through access from femoral artery with 6F Judgkin Left 4.0 catheter to LMCA. During cineangiography acquisition, patient exclaimed of a sudden chest pain, which progressed into a decrease of consciousness, and hypotension. The monitor showed an ST-elevation of aVR, followed by an onset of VT with pulse. Cardiopulmonary resuscitation was performed and the angiography showed critical stenosis of LMCA. The LMCA ostium was engaged with 6F 3.5 guide catheter, followed by guidewire penetration into the lesion. Dilatation was performed with a 2.0 x 15 mm balloon followed by insertion of a drug eluting stent Amphilius (3.00 x 20 mm) to the LMCA, the stent was successfully implanted. Due to high thrombus burden, the patient was also given Intravenous GPIIB/IIIA. Other than a short period of gross hematuria, the patient had quite an uneventful event and discharge 4 days later with 100 mg aspirin and 75 mg clopidogrel.

Conclusion

LMCA occlusion can be rapidly fatal, making a rapid assessment and action crucial in its management. Therefore, operator and personnel's alertness in signs of acute LMCA occlusion is paramount during any coronary interventional settings.

Keywords

Left main coronary artery, coronary angiography, stents



The Deadly Peripartum Cardiomyopathy: A Case Report

F. Rachmaningrum¹, D.J. Sugeng¹, G. Tryan¹, R. Ekaputra¹

¹RSU Banyumanik 2, Semarang, Indonesia

Background :

Peripartum Cardiomyopathy (PPCM) is the main cause of heart failure in pregnancy with high morbidity and mortality, marked by reduction of LVEF <45% with no other cause of heart failure. The clinical signs and symptoms are dyspnea, orthopnea, and paroxysmal nocturnal dyspnea. PPCM usually overlaps with physiological changes in pregnancy and makes it underdiagnosed.

Case illustration :

A 25-years-old primiparous woman came to the emergency room five months after giving birth, reporting dyspnea, palpitations, edematous extremities, nausea, and bloating that had lasted two months. During examination, the patient had a blood pressure of 130/82 mmHg, a pulse rate of 116 bpm, a respiratory rate of 28/minute, and oxygen saturation of 95% on room air. Auscultation of the lungs revealed rhonchi sound at the basal. Cardiovascular exam revealed regular heart sounds with murmur and JVD 5+4 H₂O. Chest x-ray examination showed cardiomegaly with pulmonary congestion. A transthoracic echocardiogram showed an LVEF of 25%, global hypokinesis, dilated all heart chambers, and thrombus at LV apex. Patient was given diuretic followed by administering ARB, beta-blocker, MRA and anticoagulant. The next day, patient had a seizure, monitor ECG showed ventricular tachycardia. The fourth day of treatment, patient had cardiac arrest, cardiopulmonary resuscitation was performed, but the patient died.

Conclusion :

Peripartum cardiomyopathy is a rare life-threatening cardiomyopathy. The prognosis for women with PPCM depends on improvement of left ventricular size and function within 6 months after delivery. Delayed recovery was associated with delayed diagnoses, higher NYHA functional class, LV thrombus, and coexisting medical illnesses. Mortality rate varies widely (7-50%). The common cause of death are progressive heart failure, arrhythmia, or thromboembolism. Due to its morbidity and mortality, careful cardiac follow up is essential for pregnant women who develop symptoms.

Keyword : Peripartum cardiomyopathy, heart failure, pregnancy, postpartum

PATENT DUCTUS ARTERIOSUS SUCCESSFULLY CLOSED WITH INTRAORAL IBUPROFEN IN PRE-TERM NEONATE : A CASE REPORT FROM RURAL

R.K. Ratri¹, C. Saputra², Sieeny³, J.A. Widodo³

General Practitioner of Mgr. Gabriel Manek, SVD Public Hospital of Atambua-East Nusa Tenggara¹
Cardiology and Vascular Medicine Department of Mgr. Gabriel Manek, SVD Public Hospital of Atambua-East Nusa Tenggara²

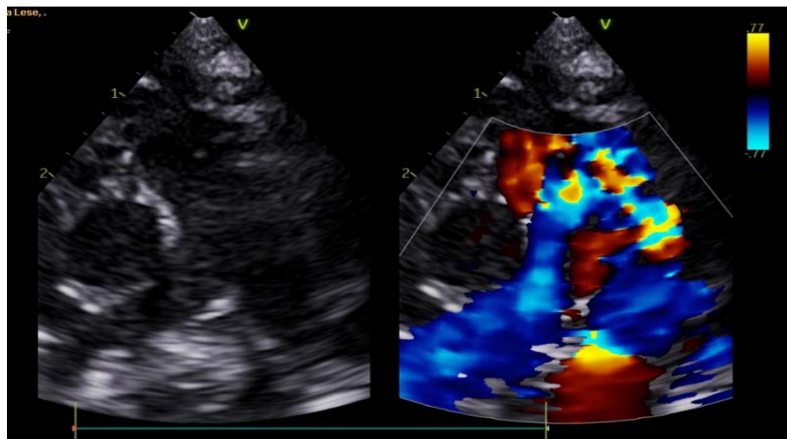
Pediatrics and Perinatal Medicine Department of Mgr. Gabriel Manek, SVD Public Hospital of Atambua-East Nusa Tenggara³

Background: Patent ductus arteriosus (PDA) is a common cardiovascular condition in pre-term neonate, defined as the failure of ductus arteriosus closure within 48 hours after birth. Symptomatic PDA provides significant hemodynamic consequences which can lead to significant respiratory distress. We chose Ibuprofen as medical treatment of choice for PDA cases in preterm.

Case Illustration: A ten days old boy was born via elective cesarean section at 35 weeks and 2 days of gestation, weight 2.250 grams, with an Apgar score of 6/9 body temperature was 36.9 °C, heart rate was 148 beats/min and regular, respiratory rate was 67 times/min, and blood oxygen saturation level was 97%. Day ten after birth a continuous heart murmur at the left upper sternal border was noted. Initial echocardiography on admission demonstrated the presence of PDA. The treatment strategy was to administer a total of three doses of intraoral ibuprofen, which an initial dose of 10 mg/kg at 0 hour followed by 20 mg/kg at 24 and 48 hour then. 24 hours after the first ibuprofen administration, no continuous murmur was heard, heart rate from 160-180 beats/min to 128 beats/min, as well as in the respiratory rate from 64-68 breaths /min to 46 breaths/min, retractive breathing also showed a reduction, and without demonstrated side effects. The patient remains in good systemic condition and was discharged from the hospital on day 18th after birth.

Conclusion: Pre-term neonate with symptomatic PDA has been successfully treated with intraoral ibuprofen. Ibuprofen administration might be a useful medical treatment option. The patient's condition has been improved and PDA was spontaneously closed with medication.

Keywords: Patent Ductus Arteriosus, Ibuprofen, Pre-term neonate



Bedside Echocardiography Exam showed PDA LR shunt

A Case Report: Acute Deep Vein Thrombosis in Suspected May-Thurner Syndrome

M.R.M.P. Sinurat¹, D.S. Kusumaningayu¹
Cileungsi Hospital, Bogor, Indonesia¹

Background

May-Thurner syndrome, also known as iliac vein compression syndrome, is a rare medical condition in which the left iliac vein is compressed by the adjacent right iliac artery. This can lead to the development of deep vein thrombosis (DVT), usually in the leg. We report a case of how we encountered a suspected May-Thurner syndrome in a rural area.

Case Illustration

A 43 years old female, presented with acute unilateral left lower limb swelling 6 hours before admission. She also experienced erythema, pain, and tenderness alongside the limb, Homans sign (+).

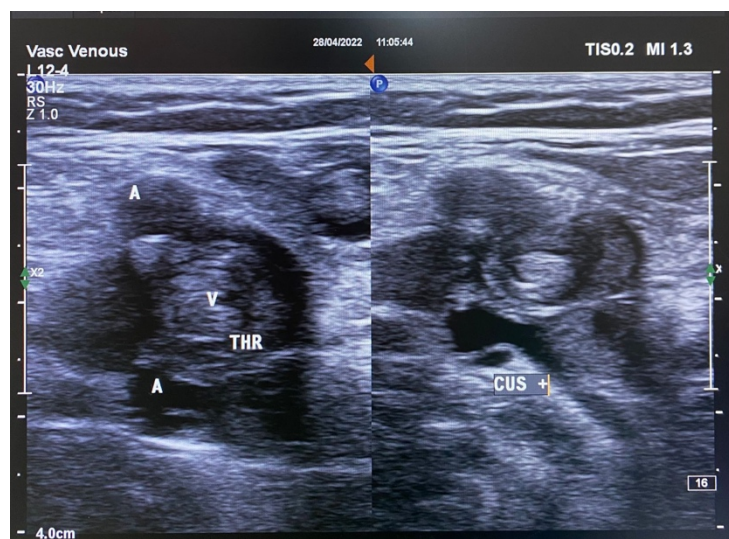
On physical examination, the vital sign is within normal limit. Peripheral pulse is difficult to assess due to swelling. The right and left ankle-brachial index (ABI) was 1.1 and 1.3, respectively. Glucose blood level was 289 mg/dL. ECG showed sinus rhythm. Doppler ultrasound showed high burden thrombus and no flow throughout the left lower limb vein system, suggestive compression of the left iliac vein.

Patient was diagnosed with acute DVT and suspected May-Thurner Syndrome. After optimal anticoagulant therapy, she was referred to a tertiary hospital to undergo further assessment and mechanical thrombectomy/angioplasty.


Conclusion

Unprovoked DVT can be triggered by May-Thurner syndrome. Early diagnosis and referral could lower long-term complications and mortality rates.

Keywords: May-Thurner Syndrome, Deep Vein Thrombosis



Doppler ultrasound showed thrombus and positive compression ultrasound (CUS)



A 36 Years Old Female with Acute Decompensated Heart Failure (ADHF) and Atrial Fibrillation (AF) Associated with Hyperthyroidism : A Case Report

K. Nisa¹, A. Ferly²

Pupuk Kaltim Hospital, Bontang, East Borneo, Indonesia¹

Department of Cardiology and Vascular Medicine, Faculty of Medicine Universitas Indonesia - National Cardiovascular Center Harapan Kita, Jakarta, Indonesia²

Background: Hyperthyroidism affects the cardiovascular system in the form of hemodynamic changes and direct effect on the myocardium, which can lead to heart failure (HF) and arrhythmias (mostly AF) if not treated properly.

Case Illustration: A 36-year-old female came to the emergency room with shortness of breath accompanied by palpitation and tremors. The patient had a history of hyperthyroid disease since she was 26 years old that wasn't treated routinely for the past 5 years. On physical examination, blood pressure was 153/118 mmHg, heart rate 140-150 bpm, respiratory rate 22-24 bpm, temperature 36.3°C. The cardiovascular examination showed the heart rate was 188 bpm with irregular rhythm. The EKG showed atrial fibrillation-rapid ventricular response (AF RVR). The result of thyroid function was hyperthyroid. Chest X-ray showed cardiomegaly, pleural effusion and pulmonary edema. Echocardiography showed dilatation of all four cardiac chambers, with EF:28% (global hypokinetic), TAPSE: 14 mm. The patient was diagnosed with ADHF and AF RVR ec Thyroid Heart Disease (THD) treated with Furosemide, Spironolactone, Ramipril, Extra Fargoxin, Simarc, Enoxrin, Tyrozol. The patient was monitored and showed improvement, and was discharged after the 4th day of treatment. Early and optimal control of thyroid levels is key in the management and prevention of THD. B-blocker group is the first choice for rate control in AF but in this case of ADHF with AF, digoxin is a better choice. Hyperthyroidism caused HF via two main pathways: (1) tachycardia-induced HF with LV dysfunction, (2) RV heart failure due to the RV volume overload. HF in hyperthyroidism has 3 phases: hyperkinetic, normokinetic, followed by hypokinetic.

Conclusion: Hyperthyroidism that's not treated properly can cause HF and AF, which increases the risk of disability and death. It is important to raise patient's awareness to take medications regularly and routinely check for hyperthyroid treatment and cardiac function.

Keywords: Thyroid Heart Disease, Hyperthyroid, Atrial Fibrillation, Acute Decompensated Heart Failure

Tricuspid Valve Obstruction Caused by Giant Intracardiac Tumor in Children : A Time Bomb

A.R. Pratama¹
RS AR Bunda Lubuk Linggau¹

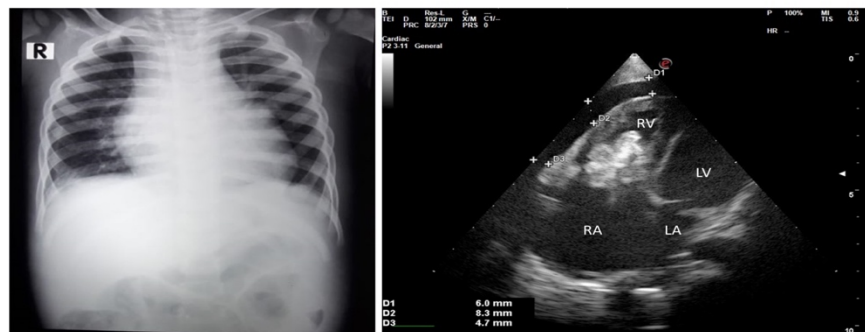
Background: Intracardiac tumor in children are rare and commonly benign, rhabdomyomas and fibromas are the most common benign cardiac tumors in children, but tumor with originate from the cardiac valve usually is papillary fibroelastomas, although are benign but can compromise cardiac function because of their potential for pulmonary artery obstruction or pulmonary embolism.

Case Illustration:

A 19-months old boy had presented with fever and shortness of breath of four days duration, previously the patient often complained of dyspneu since the age of 6 months without signs of cyanosis. At admission, he had signs and symptoms febrile, irritable, tachypnea and tachycardia. His Chest X-Ray demonstrated cardiomegaly, from laboratory result showed thrombocytopenia (24.000/uL) and hypoalbuminemia, due to found cardiomegaly patient was consulted for Echocardiography. Transthoracic echocardiography showed RA dilatation, a large tumor attached tricuspid valve with largest measured 2.17 cm x 1.88 cm, the right ventricle was severely underloaded and had dyskinetic wall motion. LV function was normal with paradoxical movement seen. Pericardial effusion is seen around the cardiac chambers. Due to the potential for life-threatening embolic events, the patient was referred to tertiary hospital for further examination and the possibility of surgical resection and analysis histopathology of tumor, but unfortunately two days before surgery, the patient passed away.

Conclusion: Intracardiac tumors are rare and mostly benign in children, they can compromise cardiac function depending on their size and location. A clinician should be aware of symptoms of heart failure such as dyspnea and signs of murmurs because the presence of a tumor can increase the risk of a life-threatening embolic event.

Keywords: Intracardiac, tumor, children, embolic, cardio-oncology



(A) Chest X ray showed cardiomegaly (B) Transthoracic echocardiography apical 4 chamber view

DIFFERENT ETIOLOGIES EMBOLISM ON ACUTE LIMB ISCHEMIA PATIENTS

A.P. Febrianto¹, A. Yasa¹, H. Sulastomo¹

Department Cardiology and Vascular Medicine, Dr. Moewardi Hospital¹

Background:

The etiology of acute limb ischemia are largely due to embolism and thrombosis. Most cases are cardiac embolism, among which atrial fibrillation accounts for the majority due to the formation of mural thrombi. Other causes include valvular diseases, thrombosis due to an occlusive atherosclerotic lesion, and paradoxical embolism. We report 2 cases of acute limb ischemia patient with different sources embolism.

Case illustration:

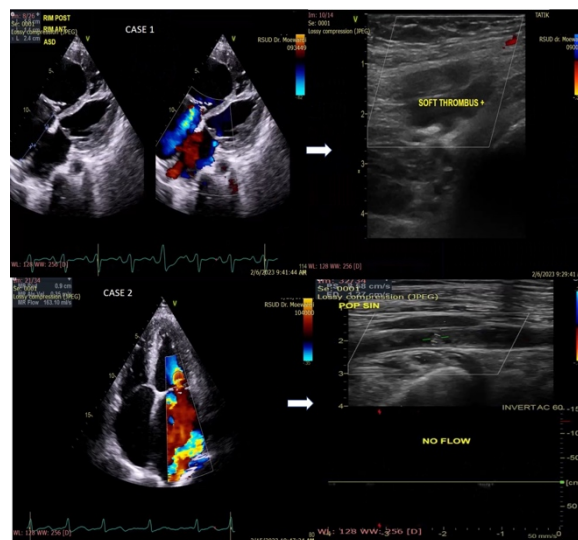
Case 1, a 41-year-old woman suffered from right lower limb pain since 6 hours. She had cold acral, low sensory, peripheral saturation right lower limb was zero, also no pulse femoral right artery. Waveform was dampened and monophasic with soft thrombus occlusion in the right femoral artery from Duplex Ultrasound . DSA was performed, total occlusion was revealed in the ostial of right common femoralis artery. Transthoracic echocardiogram revealed signs of pulmonary hypertension (PH), dilated right ventricle and atrium, also we found secundum Atrial septal secundum right-to-left shunt. We suspected source of thrombus was from paradoxical embolic event.

Case 2, a 54-year-old woman suffered from left lower limb pain and his left foot purple-turned for 15 hours. No pulse at left poplitea artery and his peripheral saturation left lower limb was zero. ECG showed Atrial Fibrillation normoventricular response. No flow waveform in left poplitea artery was found during Duplex UltraSound. Total occlusion was revealed at the ostial of right common femoralis artery from DSA. Transthoracic echocardiogram showed Mitral regurgitation severe, dilated left cardiac chambers and spontaneous echo contrast. We revealed source of thrombus was from micro thromboembolic event.

Conclusions:

This serial case emphasized the necessity to consider possible causes in ALI-cases

Keywords: Acute Limb ischemia, paradoxical embolism, Atrial Fibrillation



Different etiologies embolism on acute limb ischemia patients

Hyperkalemia induced Pseudo-infarction pattern: A Case Report

M.R.M.P Sinurat¹, N.M. Asoehan¹
Cileungsi hospital, Bogor, Indonesia¹

Background

Electrolyte imbalances can cause ECG (*Electrocardiogram*) abnormalities that are often ambiguous. We report a death case of acute untreated chronic kidney disease presenting with pseudo-infarction pattern.

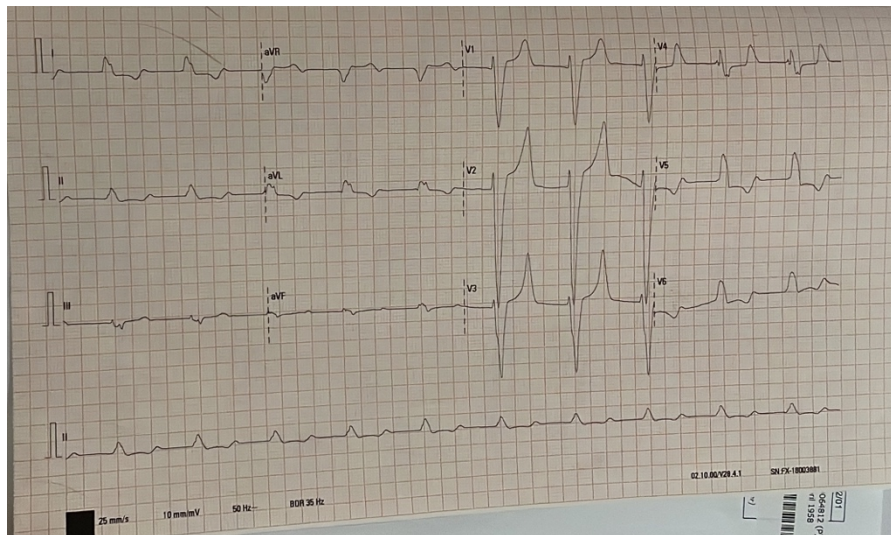
Case Illustration

A 64 years old female, experienced severe vomitus and shortness of breath since 1 day before admission. On physical examination, She was normotensive, slight bradycardia and tachypnea with severe desaturation (65% on room air). ECG showed left bundle branch pattern (Modified Sgarbossa = 0) with flattened P wave and peak and tall T in V1-3. Potassium, ureum and creatinine level 209 mg/dL and 7.3 mg/dl, respectively. Hyperkalemia may present as an ST segment elevation that lead to misinterpretation and delay definitive therapy. ECG changes in hyperkalemia include: peak of the T wave, PR interval prolongation, widening of the QRS complex, flattening of the P wave. Our patient refused to undergo urgent haemodialysis and unfortunately died due to malignant arrhythmia.


Conclusion

ST segment elevation is not always indicate a myocardial infarction. Other condition such as hyperkalemia could mimic the ECG changes, comprehensive evaluation is crucial in identifying and managing this similar but comprising an entirely distinct mechanistic cause.

Keywords: Hyperkalemia, ST Elevation, ECG



ECG showed left bundle branch pattern (Modified Sgarbossa = 0) with flattened P wave and peak and tall T in V1-3.



Challenging Permanent Pacemaker Implantation in a Patient with Total AV Block and Rare Vascular Anomaly: A Case Illustration of an 81-Year-Old Woman with Left Persistent Superior Vena Cavae

A. Kurniawan¹, A. Rizal¹

Department of Cardiology and Vascular Medicine, Faculty of Medicine Universitas Brawijaya; dr. Saiful Anwar General Hospital¹

Background:

Permanent pacemaker implantation is a crucial procedure for patients with total AV block to avoid life-threatening complications. However, anatomical abnormalities like left persistent superior vena cavae (LPSCV) can pose a challenge during implantation.


Case illustration:

An 81-year-old woman was admitted to the hospital due to a total atrioventricular block. The patient had previously been treated with temporary pacemaker placement, but it was decided to perform permanent pacemaker implantation due to the persistence of the AV-block. However, during the procedure, the lead encountered technical difficulties in reaching the right ventricle, resulting in continuous displacement toward the coronary sinus. After several maneuvers were attempted without success, a rare anatomical variant of left persistent superior vena cava (LPSCV) was suspected as the culprit. The LPSCV was confirmed by venography, and ultimately, alternative techniques were employed to successfully position the lead in the right ventricle. LPSCV is a rare anatomical variation that can pose significant challenges during permanent pacemaker implantation. In some cases, selective maneuvers may be required to position the lead in the right ventricle. Therefore, a thorough understanding of the specific handling and appropriate maneuvers is essential to overcome these challenges and ensure successful permanent pacemaker implantation in patients with LPSCV.

Conclusion:

Permanent pacemaker implantation in patients with LPSCV is challenging and requires specific handling and appropriate maneuvers. Selective maneuvers can be effective in overcoming technical difficulties during lead placement.

Keywords: Permanent pacemaker, left persistent superior vena cavae, technical difficulties



Successful Catheter Ablation of Ventricular Tachycardia in a Patient with Arrhythmogenic Right Ventricular Cardiomyopathy: A Case Report

A. Kurniawan¹, A. Rizal¹

Department of Cardiology and Vascular Medicine, Faculty of Medicine Universitas Brawijaya; dr. Saiful Anwar General Hospital¹

Background:

Arrhythmogenic right ventricular cardiomyopathy (ARVC) is an inherited cardiac disease characterized by fibrofatty infiltration and arrhythmias. The diagnosis of ARVC is based on a combination of clinical, electrocardiographic, imaging, and pathological criteria. The major criteria for the diagnosis of ARVC include regional wall motion abnormalities and/or RV dilatation or reduced ejection fraction, ventricular arrhythmias, and tissue characterization by cardiac MRI, which can reveal fibrofatty infiltration.


Case illustration:

We report the case of a 39-year-old male with a history of recurrent ventricular tachycardia (VT) who had undergone multiple hospitalizations and cardioversion. A Holter monitor showed multifocal PVCs with a dominant RVOT anterior endocardial origin. The patient was suspected to have ARVC, and a cardiac MRI revealed late enhancement in the transmural basal anterior, basal anteroseptal, mid anterior, mid anteroseptal, and apical anterior regions. The patient had a hypokinetic left ventricle with an ejection fraction (EF) of 45.2% and a reduced RV EF of 31.5%. The EKG during VT was also consistent with one of the major criteria for ARVC. The patient underwent unsuccessful catheter ablation. During follow up patient still experienced palpitations, and a repeat ablation was performed using HD Mapping ablation and selective maneuvers were employed to successfully eliminate ventricular tachycardia. The HD Mapping ablation technique has been shown to improve the success rate of ablation procedures in patients with complex arrhythmias, including ARVC.

Conclusion:

In summary, the diagnosis of ARVC is based on a combination of clinical, genetic, and imaging criteria. Recurrent arrhythmias in ARVC patients pose a significant management challenge, but the use of HD Mapping ablation techniques may improve success rates.

Keywords: Arrhythmogenic right ventricular cardiomyopathy, catheter ablation, HD mapping



Myocardial CT Perfusion Stress Test: The First Experience in Indonesia

S.D. Handari^{1,3}, Y.W. Ashari², A.F. Rahimah³, W. Karolina³, I. Kamelia²

¹Cardiovascular Imaging Division, Premier Hospital, Surabaya, Indonesia;

²Cardiology Resident at Faculty of Medicine Universitas Brawijaya-Saiful Anwar General Hospital, Malang, Indonesia;

³Cardiovascular Imaging Division, Faculty of Medicine, Universitas Brawijaya-Saiful Anwar General Hospital, Malang, Indonesia;

Background

Stress myocardial computed tomography perfusion (CTP) is a novel examination that provides both anatomic and physiological assessment of myocardial ischemia. Stress myocardial CTP outperformed single-photon emission computerized tomography (SPECT) and echocardiography, and was comparable to magnetic resonance imaging (MRI) and positron emission tomography in terms of accuracy in measuring myocardial perfusion.

We present a smoker, 45 years old male, complained about typical chest pain, undergoing first stress CTP procedure in Indonesia.

Case Illustration

A 45 years old male, with risk factor heavy smoker and premature coronary artery disease (CAD) in his family, came to the cardiac outpatient clinic with typical chest pain. There were no history of hypertension, diabetes mellitus, nor dyslipidaemia in this patient. Electrocardiography, laboratory findings, and chest radiograph showed normal result. Echocardiography evaluation and treadmill stress test were also normal. We assessed pre-test probability score in this patient, was 22%. Using GE Revolution Apex 512 slices, we performed a comprehensive cardiac computed tomographic protocol combining computed tomography angiography (CTA) and CTP to provide a simultaneous assessment of both coronary artery anatomy and ischemia. Stress-rest procedure using adenosine and iso-osmolar contrast media. Total calcium score was 22 with evidence of coronary soft plaque 20-30% at LMS-osteal LAD (CAD-RADS 2/V) with no ischemia inducible. Total radiation during procedure was 14.96 mSv.

Conclusion

Stress myocardial CTP, which might serve as a "one-stop-shopping" tool for the diagnosis and overall care of CAD patients, is currently the only non-invasive modality that providing an integrated anatomical/functional analysis. It therefore helps reducing the possible over-indication to myocardial revascularization.

Keywords: Computed tomography myocardial perfusion, Myocardial perfusion imaging, Stress perfusion, Non-invasive diagnostic, Coronary artery disease

Pulmonary Atresia with Intact Ventricular Septum: A Nightmare in Neonatal Intensive Care Unit

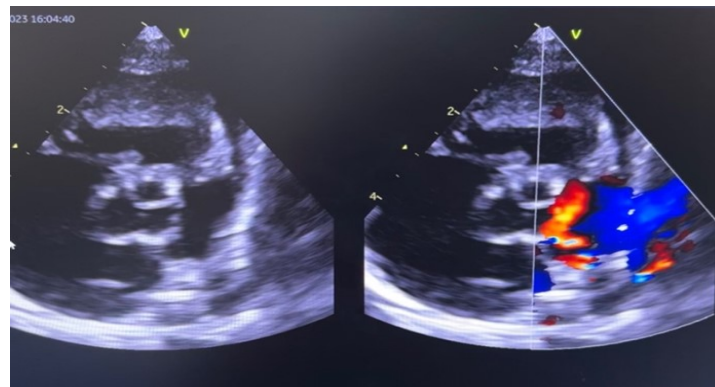
M.M. Sari¹, D. Arara¹
RSU Bunda Margonda¹

Background: Pulmonary atresia (PA) is a heart defect present at birth that's usually diagnosed soon after birth. The incidence of Pulmonary atresia was about 9.6% of all congenital heart defect. Pulmonary atresia (with Ventricular Septal Defects (VSD) or Intact Ventricular Septum (IVS)) is one of congenital heart disease that can be classified as a duct dependent pulmonary circulation. Babies with pulmonary atresia need immediate treatment which may include medications and one or more procedures or surgeries.

Case Illustration: Newborn term-baby girl was consulted by Consultant Neonatal Intensive Care to Cardiologist due to desaturation since birth. The mother had a delivery by C-section due to high-risk pregnancy (multipara and the mother was 40 years old). From the clinical examination were found continuous murmur at LUSB with pansystolic murmur grade III/VI at LLSB. Other physical findings were unremarkable. From chest x ray was found a cardiomegaly. Echocardiography showed Pulmonary atresia with intact ventricular septum, 3 mm PDA and moderate tricuspid regurgitation with right ventricular hypertrophy. We administrated the patient with drip prostaglandin E1 to keep the ductus arteriosus still open. We also took off the oxygen supplementation and the baby saturation were stable between 75-85%. We also look for referral hospital with advance cardiac pediatric care to manage this patient. In the 4th days of hospitalization, the baby finally can be referred to other hospital and she was performed balloon pulmonary valvulotomy. Unfortunately, in a 7th day of hospitalization, the baby was passed away due to multi-organ failure.

Conclusion: Recognizing the cardiac defects by physical examination, chest x ray and echocardiography are mandatory in baby with suspected congenital heart disease. Prostaglandin drip with procedures or surgery is a mandatory management in PA-IVS patient.

Keywords: Congenital Heart Disease, Pulmonary Atresia, Intact Ventricular Septum, Ductus Arteriosus, Neonates



Picture 1. (a) Echocardiography showed “no flow” from RV to PA with Ductus Arteriosus. (b) Echocardiography showed intact ventricular septum with Tricuspid Regurgitation

"Rising to Challenge: A Case Report on Managing Infective Endocarditis with Multiple Complications and Re-expansion Syndrome"

M.S. Goma¹, S.Y. Pradana¹, A.Z. Abidin¹, D.Y. Kurniawan¹, S. Sungkar¹

Department of Cardiology and Vascular Medicine, Faculty of Medicine Diponegoro University- Dr. Kariadi Central General Hospital, Semarang, Indonesia¹

Background

Infective endocarditis (IE) is a serious infection that affects the heart and can be life-threatening if not recognized and treated promptly. IE with multiple complications poses a high mortality rate. The management of IE involves a multidisciplinary approach. Treatment goals include eradication of the infectious agent, prevention of further complications, and a surgical approach.

Case Illustration

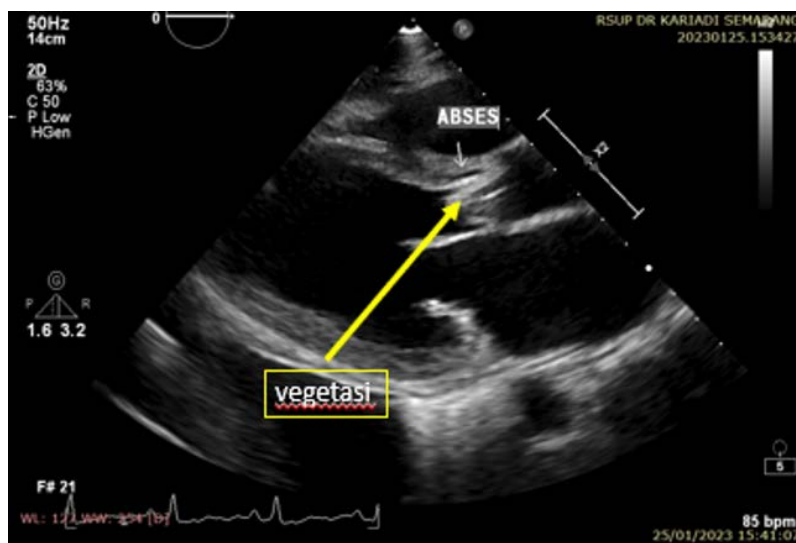
A 59-year-old woman presented with symptoms of shortness of breath, fatigue, and fever, and reported a history of chills and sweating at night. On examination, a cardiac murmur Erb's area was heard, and there was a Janeway lesion on her palmaris, her electrocardiogram showed sinus rhythm with a normal axis. Further laboratory tests revealed, elevated inflammatory marker, and elevated creatinine levels.

A Chest X-ray showed left ventricular and left atrial enlargement. Echocardiography examination showed vegetation at the aortic valve, and perivalvular abscess. The patient was diagnosed with definite IE with severe aortic regurgitation. We gave her empiric antibiotics and heart failure medication. At 5 days hospitalisation the clinical condition worsened and hemothorax was present, and patient proceeded to water-seal drainage (WSD) insertion. After 4 hours WSD insertion, the patient felt more takipneu with rales in both lungs indicating acute lung oedema, patient developed re-expansion syndrome. Due to progressive respiratory distress and hemodynamic instability, the patient was sent to the CVCU for further monitoring and management.

Conclusion

Managing infective endocarditis with multiple complications is quite tough and requires a collaborative effort from multidisciplinary specialties. Re-expansion syndrome is a rare but potentially fatal iatrogenic complication of thoracocentesis or tube thoracostomy. Vigilant monitoring and early diagnosis are crucial to prevent adverse outcomes and improve patient outcomes.

Keywords: Infective Endocarditis, Complications, Re expansion Syndrome



There was a vegetation at the aortic valve and perivalvular aortic abscess

Importance of aVR Lead in Patient with Acute Coronary Syndrome :A Case Report

G.F. Ramadhan¹, T. Rahadiyan²

RS DKT Dr Bratanata Jambi¹

RS DKT Dr Bratanata Jambi dan RSUD Raden Mattaher Jambi²

Background

Coronary Artery Disease (CAD) is still one of the cardiovascular diseases with high mortality rate, responsible for around 8.9 million deaths each year¹. Acute Coronary Syndrome (ACS) requires immediate diagnosis within 10 minutes with an electrocardiography (ECG)². Identification of ST-segment elevation is very important, including in aVR lead. However, sometimes the aVR lead is neglected lead to find ST-elevation in ACS cases³. Several studies shown that ST-elevation in the aVR lead can be associated with various conditions including Left Main disease with a high mortality rate.^{4,5}

Case illustration

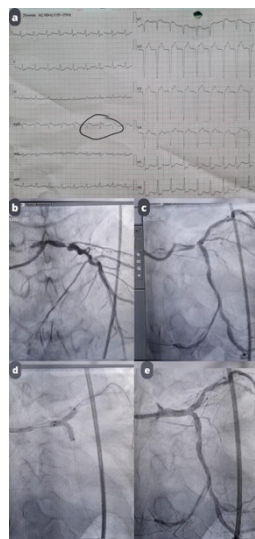
A 72-year-old man presents to emergency room complaining severe typical chest pain and shortness of breath for approximately 2 days. Physical examination revealed rhonchi at the lung bases. ECG examination found ST-segment elevation in aVR lead and ST-segment depression in I, II, aVL, aVF, V5 and V6 leads. ST-elevation in aVR lead may associate with critical Left Main Coronary Artery (LMCA) occlusion. Its not always be total occlusion that leads to rapid cardiac arrest.^{6,7}

Laboratory tests showed increased cardiac enzymes both CKMB and troponin I. Patients diagnosed with high risk NSTEMI and referred immediately to PCI on capable hospital. Prior to coronary angiography, an echocardiographic examination revealed decreased EF to 37.8% accompanied by global hypokinetic. Angiography revealed critical LMCA occlusion with some calcification and non-dominant Right Coronary Artery (RCA). Early PCI was performed by placing two-DES stent in the occluded blood vessel. After procedure, chest pain significantly relieved.


Conclusion

From this case, it shows that the importance of holistic ECG interpretation including aVR lead in ACS cases. Electrocardiography not only utilized as diagnostic tool, but also as predictor for patient outcomes. So, as practitioners we can provide adequate therapy to avoid complications.

Keywords: aVR lead, ST-elevation, electrocardiography, left main disease, acute coronary syndrome



a: ECG found ST-elevation in aVR lead and ST-depression in multiple leads; b-e: Angiography revealed significant stenosis 90-95% LMCA, 70-80% LAD and 80-90% LCx, hence 2-DES Stenting performed



Medical Management in Stanford A Aortic Dissection Complicating long Standing Severe Aortic Insufficiency in Marfan women : A Bridge too far

I.P. Farissa¹, F. Tandri¹, Y. Herry¹, R. Hidayatullah¹, S. Sungkar¹
RSUP dr Kariadi/Diponegoro University¹

Background

Marfan syndrome (MFS) is an autosomal dominant, age-related but highly penetrant condition with substantial intrafamilial and interfamilial variability. The most prominent manifestations of MFS are asymptomatic aortic root aneurysms and aortic dissections. Untreated aortic root aneurysms can progress to life-threatening acute aortic dissections. In type A dissection patients with or without Marfan syndrome, open surgery was the preferred treatment method


Case Illustration

A-31-year-old women admitted due to shortness of breath with chest discomfort. Physical examination revealed long arm span (1,078) compared to her height, high arched palate, Pulse pressure 109/53 mmHg, early diastolic murmur grade III/IV high pitched, loudest at Erbs area, pulsatile abdominal pulse periumbilical, with wrist sign and thumb sign suggesting Marfan syndrome with aortic insufficiencies (AI). Cardiomegaly, scoliosis vertebra thoracal with congestive pulmonum was noted by chest x-ray. Echocardiography revealed severe AI and moderate TR, dilatation in aorta 29 mm with intimal flap distal of sinotubular junction, decreased LV systolic function EF 26%. In MSCT Aorta revealed Intimal flap from ascending aorta and abdominal aorta at Th.12 vertebrae (\pm 3.23 cm long), suspected aortic dissection. We managed to optimized medical therapy while preparing for surgical procedure.

Conclusion

Aortic dissection and insufficiency are common complications of Marfan syndrome. Early diagnosis and prompt treatment are crucial in preventing life-threatening complications, including aortic rupture and death. Medical management of aortic dissection and insufficiency in Marfan syndrome requires a multidisciplinary approach. Although the management of aortic dissection and insufficiency in Marfan syndrome is complex, with appropriate medical care and support, patients can lead healthy and fulfilling lives.

Keywords: aortic insufficiency, marfan syndrome, aortic dissection



SGLT2 Inhibitors as a Promising Treatment Option for Myocarditis-Related Heart Failure

F.Q. Decroli¹, M. Yanni²
RSUP M DJAMIL¹

Division of Cardiology and Vascular Medicine , M. Djamil Hospital Padang²

Background : Myocarditis-related heart failure is a condition that can cause significant morbidity and mortality. Although traditional treatments for heart failure are useful in many instances, a significant number of patients continue to experience symptoms and have unfavorable results. SGLT2 inhibitors, may have added advantages for individuals with myocarditis-induced heart failure accompanied by a reduced ejection fraction (HFrEF). This case study demonstrates a myocarditis patient who received supplementary SGLT2 inhibitor therapy, resulting in improved outcomes.

Case Illustration : a 44-year-old female who exhibited symptoms of chest pain, fatigue, and shortness of breath. Physical examination was within normal limit, ECG Showed LAD with LVH, CXR showed CTR 63% and NT-Pro BNP had a level of 4001 pg/ml. Echocardiography revealed that the patient had a reduced ejection fraction of 32% and with global hypokinesia and dilation of LV, suggested as Myocarditis with reduced EF. Coronary angiography was performed, which yielded no blockages, leading to the conclusion that coronary occlusion has been ruled out.

The patient was initially treated with standard heart failure therapy, However, due to the poor response to initial therapy, an SGLT2 inhibitor was added to the treatment regimen. The patient showed significant improvement in ejection fraction after the addition of the SGLT2 inhibitor. After 10 months of treatment, the patient's symptoms improved significantly, and her ejection fraction increased to 55%. In addition, NT-proBNP levels improved from 4001 pg/mL to 107 pg/mL within 10 months of therapy. The patient's condition also progressed positively, moving from NYHA Functional Class III to NYHA Functional Class I.

Conclusion : This case highlights the potential benefits of SGLT2 inhibitors in the management of myocarditis-related HFrEF in a single patient. Further studies are needed to confirm these findings, but our experience suggests that SGLT2 inhibitors may represent a valuable addition to standard heart failure therapy.

Keywords: myocarditis, heart failure, sgl2inhibitors

A YOUNG MALE PATIENT WITH CARDIOMYOPATHY ASSOCIATED WITH HUMAN IMMUNODEFICIENCY VIRUS (HIV) INFECTION IN THE ERA OF HIGHLY ACTIVE ANTIRETROVIRAL THERAPY

A. Wicaksono¹, H. Martini², A.F. Rahimah², A. Kurniawan¹

¹Cardiology Resident, Faculty of Medicine Universitas Brawijaya- Saiful Anwar Hospital, Malang, Indonesia;

²Departement of Cardiovascular Medicine, Faculty of Medicine Universitas Brawijaya-Saiful Anwar Hospital, Malang, Indonesia

BACKGROUND

Cardiomyopathy in young people especially those associated with HIV infection has been reduced since the era of Highly Active Antiretroviral Therapy (HAART). In the era of post-HAART, manifestations of HIV-associated cardiomyopathy with impaired LV systolic function approximately about 1-3% in HIV-infected people. In this case we presenting how to diagnose and proper management in such of patient.

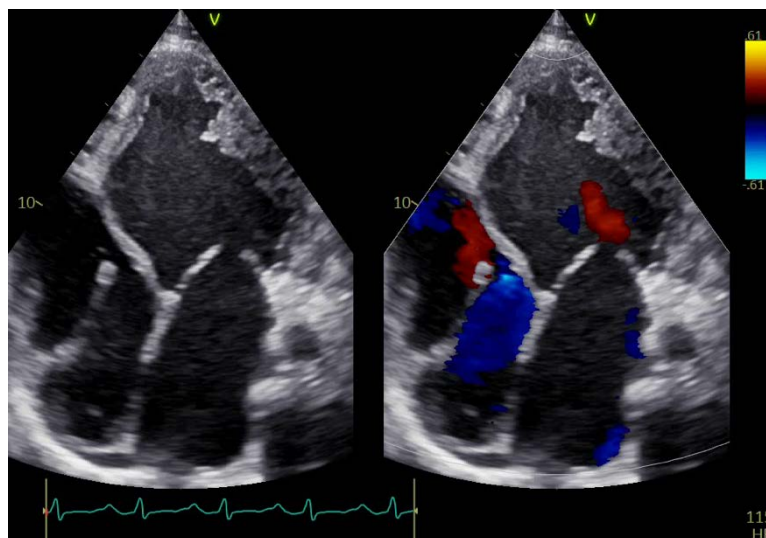
CASE ILLUSTRATION

A 27-year-old male patient who works as a health worker, came to the emergency room with complaints of shortness of breath with light activity in the last 2 weeks accompanied by orthopnea and leg edema. Other risk factors besides smoking such as family history, hypertension, diabetes mellitus, and dyslipidemia was denied. He was diagnosed with HIV on ART since 3 years ago. From echocardiography showed all chamber dilatation, global hypokinetic and significant decrease of LV systolic function (LVEF 16%). The patient was then treated by optimizing HF therapy in collaboration with internal medicine to continue HIV therapy in the patient.


CONCLUSION

In HIV patients who have fallen into heart failure, a proper diagnosed using relevant tools could be a reference for clinician to make a right decision. Prompt treatment combination of optimal HF therapy and HIV therapy are becoming the keys to the treatment.

Keywords: Cardiomyopathy, Heart Failure, HIV, Antiretroviral



Echocardiographic picture of the patient with all chamber dilatation



The Compulsory of Fluid Challenge Test in Elderly Patients Prior to Transcatheter Closure of Atrial Septal Defects

C.P. Iswandi¹, C.J. Cool¹, H.S. Prameswari¹

¹Department of Cardiology and Vascular Medicine, University of Padjadjaran, Dr. Hasan Sadikin General Hospital, Bandung, Indonesia

Background

Atrial septal defects (ASDs) are the most prevalent congenital heart defects in adults. Transcatheter device closure has become the treatment of choice for secundum ASDs with suitable anatomy. Left ventricular disease in elderly may increase the risk of pulmonary oedema following ASD closure. Fluid challenge test can be used as an invasive hemodynamic test to unmask heart failure with preserved ejection fraction (HFpEF) and to assess the risk of acute LV failure post-ASD closure in elderly patients. PCWP > 15 mmHg confirms the presence of HFpEF; increased PCWP to a value of > 20 mmHg or > 10 mmHg from the baseline after fluid challenge test is expected as high risk of acute pulmonary edema and ASD closure should be abandoned.


Case illustration

A 77-year-old man with a long-standing uncorrected secundum ASD had chief complaints of dyspnea on effort and leg edema for two years. This patient underwent echocardiography showing secundum ASD of 18 mm with favorable anatomy for percutaneous closure and likely HFpEF (Intermediate HFA-PEFF Score). Because of patient's worsening of symptoms and ASD being hemodynamically significant, transcatheter ASD closure was considered to improve symptoms. Prior to ASD closure, fluid challenge test using normal saline 0,9% 5mL/kg BW showed non-significant increased PCWP (12 -> 14 mmHg), supporting the low risk of acute LV failure post ASD closure and no diastolic dysfunction. The results emphasized that patient's symptoms were solely due to ASD without HFpEF. We decided to proceed for the ASD closure using an ASD Occluder device no.21 and the patient was discharged the next day without signs of pulmonary edema.

Conclusion

This clinical case illustrates the value of fluid challenge test before percutaneous closure of ASD in elderly patients to confirm HFpEF and assess the risk of acute LV failure post-ASD closure.

Keywords: atrial septal defect, fluid challenge test, HFpEF, device closure



Improvement Left VeNtricular Ejection Fraction in Cardiomyopathy: Is It CRT or PCI?

Y. Newary, D.L. Munawar¹
Binawaluya Hospital¹

Background

Ischaemic Cardiomyopathy (ICM) represents an important cardiovascular condition associated with substantially increased morbidity and mortality. It is well recognized that postinfarction patients with heart failure face a greater mortality risk than those with a nonischaemic pathogenesis of heart failure whereas heart failure itself is a high risk factor for sudden death. Therefore according to ESC 2021 Heart Failure patients with these indications are recommended for CRT therapy to reduce the risk of sudden death. We do know performing CRT on patient with heart failure as a primary prevention for sudden cardiac death and the research improving cardiac function still lack of. In this case report, we will present the outcome of cardiomyopathy patient undergone PCI and CRT.

Case Illustration

A 65-year-old man presented with chronic heart failure with NYHA class III/IV and comorbid type 2 DM and chronic kidney disease with electrocardiography showed second degree AV block and left bundle branch block. We performed echocardiography and the left ventricular ejection fraction (LVEF) was 18% at that time. Our patient was implanted with a cardiac resynchronization device with pacemaker. Right ventricular and left ventricular leads were also implanted. We also performed percutaneous intervention with implanted 3 stents at RCA which was total occluded. The patient did not complain any symptoms after procedure and the outcome was good. After 4 months of CRT with PCI optimization, our patient's clinical status had significantly improved with LVEF was 37% and NYHA class II of heart failure.

Conclusion

Patients with dilated cardiomyopathy who undergone PCI after CRT implantation could have significant improvement in cardiac function with improvement LVEF. Changes in LVEF were inversely associated with the risk of mortality. The extent of LVEF improvement after revascularization might be a potential factor which defines clinical outcomes.

Keywords: ischaemic cardiomyopathy, PCI, CRT

The Dramatic ECG Evolution in Suspected MI Type 2: A Case Report

I. Sabrina¹, A.A. Lukito¹
Siloam Hospital Lippo Village¹

Background

ECG is a simple and useful tools which help clinician in detecting heart diseases. Myopericarditis is one of the heart disease that could give a variety clinical presentation and represent numerous ECG results which could mimicking other diseases without certain specific pathognomonic. Therefore, clinical diagnosis is often challenging and could lead to a misdiagnosis. Here we present a case with ST-segment elevation with absence of coronary artery obstruction or coronary spasm mimicking ACS in myopericarditis.

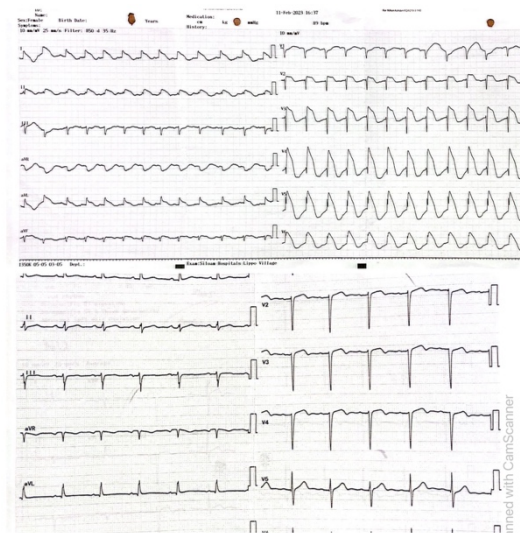
Case illustration

A 76-year-old woman presented to ER with history of typical chest pain and fever for two days. Physical examination showed BP 89/61 mmHg, HR 71 bpm, without any abnormalities. Initial ECG revealed ST-elevation in all leads except aVR (*Figure 1*). Laboratory tests were significant for CK (1690 U/L), CK-MB (109 U/L), TnT-hs (2579 pg/mL), NT-proBNP (24807 ng/L) and elevated CRP (156 mg/L). Echocardiogram showed RWMA, grade-1 diastolic dysfunction, mild mitral, pulmonary, and tricuspid insufficiency with reduced LVEF of 39%. DAPT and statin, and other symptomatically drugs were given. Catheterization was then performed and revealed non-obstructed coronary arteries. Due to these result, suspicion to myopericarditis was considered and colchicine was given additionally. Following 6-days follow-up revealed a complete resolution of the signs, symptoms in conjunction with her ECG results.

Conclusion

Diagnosing myopericarditis is quite challenging, as in this case, it was mimicking ACS with ST-elevation MI type 2. Several differential diagnosis must be considered in the case like these to prevent a misdiagnosis. Therefore, taking into account its variety signs and symptoms, thorough history taking, physical examination, and appropriate investigations such as careful analysis of ECG results are crucial to work-up the diagnosis and management of myopericarditis.

Keywords: ECG evolution, MI type 2, Myopericarditis



Initial ECG revealed ST-segment elevation in all leads except lead aVR (top). After 6 days follow-up, ECG revealed complete resolution into normal (bottom)

ASHMAN PHENOMENON IN ATRIAL FIBRILLATION, IS IT USEFUL IN CLINICAL PRACTICE? A CASE REPORT

A. Siswanto¹
RSD Balung Jember¹

Background

Ashman phenomenon is defined as the appearance of aberrant conduction, shown in ECG as wide QRS complex after long RR interval and a short RR interval, respectively. It is commonly found during atrial fibrillation. It was first found in 1947 by Dr. Gouaux and Dr. Ashman. Although this is not clinically important because there is no influence in mortality or morbidity patients, Ashman phenomenon frequently is confused with PVC or rarely ventricular tachycardia as this condition has different prognosis and treatment.

Case Illustration

A 63-year-old man was admitted to Emergency Room (ER) with main complaint of shortness of breath. This conditions got worsen in two days especially when doing daily activities. He was diagnosed with Congestive Heart Failure since some years ago. On physical examination, his heart beats was pounding irregularly and there was murmur heard at mitral valve projections. From the ECG, there was atrial fibrillation with a wide QRS which looked like a PVC, that appeared after long and short RR interval. This was known as Ashman phenomenon. Chest X-Ray's patient showed cardiomegaly with congestive pulmonum and there was also protruding left atrial appendage. This was supposedly caused by long standing atrial fibrillation. Then, the patient was treated with digoxin to control the heart rate.

Conclusion

As atrial fibrillation prevalence is high, there may be Ashman phenomenon appears often in daily clinical practice. Even though it doesn't show any important message, but clinicians understanding to this phenomenon may help them to distinguish it from premature ventricular complexes. This is mainly because PVC or rarely ventricular tachycardia has more serious complications and needs to be treated aggressively.

Keywords: atrial fibrillation, ashman phenomenon, aberrant conduction

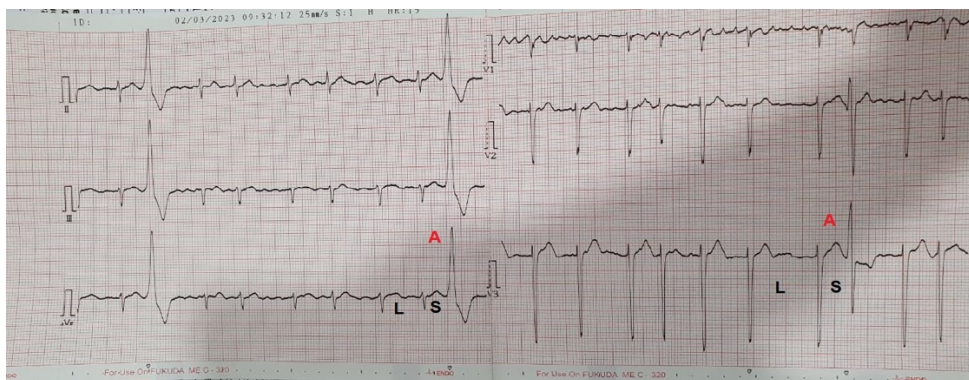


Figure 1. ECG showed long interval RR (L) and short interval RR (S) followed by aberrant QRS complex (A)

Pulmonary Embolism with Giant Right Ventricular Thrombus: What Should We do?

F.T. Ksatria¹, M.F. Ahnaf¹

¹Department of Cardiology and Vascular Medicine, Faculty of Medicine Diponegoro University, Dr. Kariadi Central General Hospital Semarang, Indonesia

Background

Right ventricular thrombus are a rare phenomenon, encountered almost exclusively in patients with suspected or proven pulmonary embolism and diagnosed by transthoracic echocardiography. Currently the optimal management of right ventricular (RV) thrombus not well established. We present a case of RV thrombus in complicated by pulmonary embolism and Hepatocellular Carcinoma.

Case Illustration

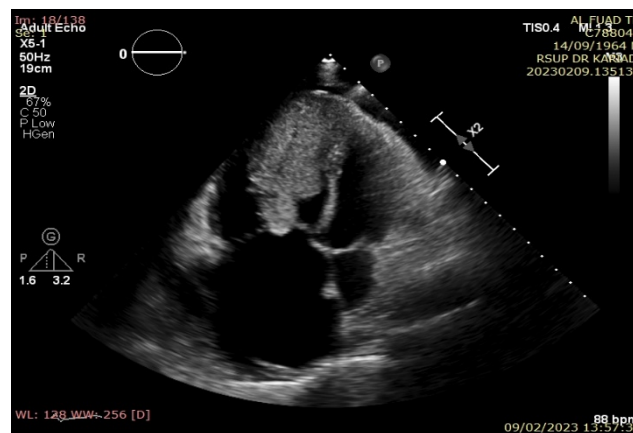
A-58-year-old man admitted to Emergency Department because shortness of breath when doing strenuous activity since 1 months and getting worse in last 1 week. Patients with history of hepatocellular carcinoma (HCC) and had done Transarterial chemoembolization (TACE). From physical examination, there was a mild leg edema and normal heart sounds, without murmur and gallop. The ECG revealed Sinus Rhythm, Right Axis Deviation and Right Ventricular hypertrophy. Cardiomegaly was noted by chest x-ray. Echocardiography revealed normal Left Ventricle function with RV Thrombus, Dilated RA, RV, Smallish LV which lead to severe tricuspid regurgitation. He was diagnosed as suspect pulmonary embolism and RV Thrombus. MSCT Angiography revealed hypodense lesion in the left pulmonary artery (length \pm 4.08 cm, thickness \pm 0.47 cm) suspected thrombus. The patient was commenced on antithrombotic with enoxaparin injection, aspirin and clopidogrel. There was improvement and then patient discharge with rivaroxaban as antithrombotic.

Three months later patient checks routinely into the outpatient department with relieved shortness of breath. Echocardiography was performed then revealed improving Left Ventricle function but RV Thrombus was bigger.


Conclusion

Right ventricular thrombus constitutes a rare yet potentially fatal situation, whose optimal management remains controversial. The described case illustrates the crucial role of transthoracic echocardiography as the election diagnostic tool in this setting, as it allows for the thrombus detection and characterization, with the inherent therapeutic strategy implications.

Keywords: Right ventricular thrombus, pulmonary embolism



Right ventricular thrombus



WAYFINDING OF AN IATROGENIC AV FISTULA FOR PCI IN A PATIENT WITH ACUTE CORONARY SYNDROME

O. Sofyan¹, A. Hafid¹
RSUP dr Wahidin Sudirohusodo¹

Background: The current international Coronary Angiography guideline recommends *transradial access* (TRA) for diagnostic and intervention percutaneous coronary because of the decreasing major side effect compared to *transfemoral access* (TFA). However, it needs to aware that coronary angiography has occurring complications, including *Arteriovenous Fistula* (AV fistula). Radial Iatrogenic AV Fistula have been reported varies from 0% to 2% and a big study reported that the incidence was 0,04%. Coronary Angiography and *percutaneous coronary intervention* (PCI) is increasingly performed in patients with Acute Coronary Syndrome and AV fistula, including *end-stage renal disease* (ESRD), however studies on vascular access are limited. Both iatrogenic and hemodialysis AV fistulae usually prevents ipsilateral transradial access (TRA) for coronary angiography.

Case Illustration :

59 years old female came to Emergency Room with chief complaint typical chest pain that occurred 12 hours before admission. She was once undergoing PCI through right radial artery 2 months before. She had hypertension and type 2 diabetes mellitus. Patient's heart rate was 75 bpm, blood pressure 130/70 mmHg. There was pulsatile, palpable mass with thrill at the post site of catheterization with bruit. The electrocardiography result was old pathologic q wave at lead III and aVF. Transthoracic echocardiography showed EF 46%, TAPSE 1.9 cm, concentric LVH, and regional wall motion abnormalities. Vascular doppler ultrasound showed a radial-cephalic arteriovenous fistula on the right superior limb. Invasive strategy was performed through the right transradial access with conventional technique combined with balloon-assisted tracking (BAT) technique to navigate through AV fistula.

Conclusions :

In conclusion, we described patient with a case of coronary angiography and percutaneous coronary intervention via left TRA with navigation through an iatrogenic AV fistula. This case report emphasize the technique that could be used to navigate invasive strategy through AV fistula, although radial access for coronary angiography may be limited in such patient.

Keywords: Iatrogenic Arteriovenous Fistula, Transradial Access, Percutaneous Coronary Intervention, Acute Coronary Syndrome

ST-Segment Depression Morphology Differences: Pearl and Pitfall for Untrained Eye

N. Sukmadi¹, M.G. Suwandi², C. Saputra³, W. Wiriadisurya⁴

FKIK Atma Jaya / RSK Marianum Halilulik¹

RSPAU dr. S. Hardjolukito²

RSUD Mgr. Gabriel Manek³

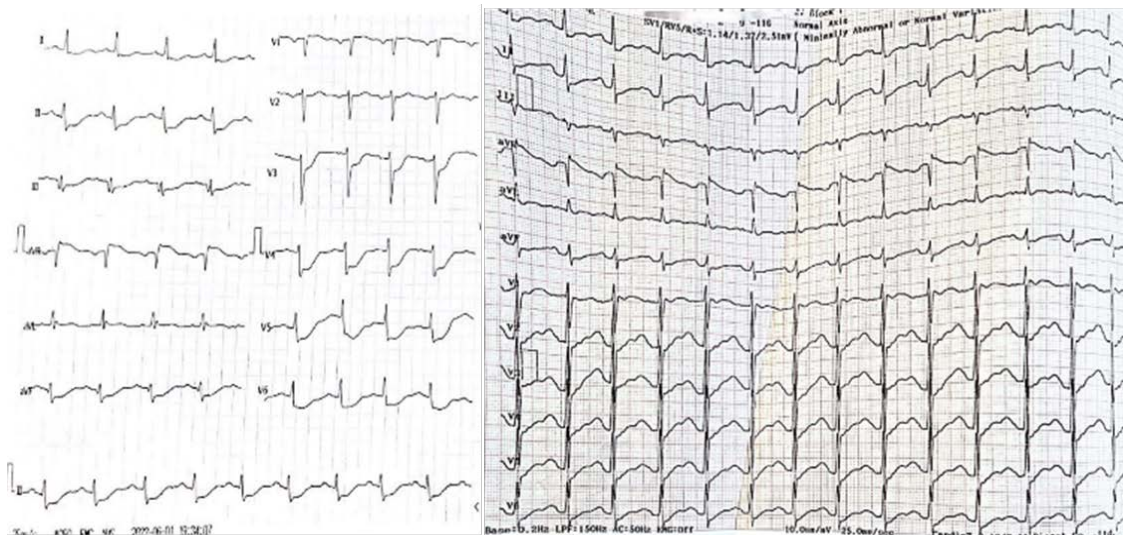
RSK Marianum / RSUD Mgr. Gabriel Manek⁴

Background: Electrocardiogram (ECG) is a powerful clinical tool to choose a proper treatment. ST-Segment depression is one of common feature of an ECG. Patient with ST-Segment depression has broad clinical spectrum, from ischemia and/or infarction to LVH, LBBB, or even electrolyte disturbance. In this report, we present a case series about 2 patients with different disease but with similar ECG features for untrained eye.

Case illustration: Our first case, 61 years old male came to emergency room (ER) with sudden typical chest pain, and shortness of breath. Patient heart rate was 126 bpm, blood pressure 192/100 mmHg, with respiratory rate of 40/minute, and oxygen saturation of 75%. The ECG results showed an oblique ST elevation in aVR with global horizontal and down-sloping ST depression (I, II, III, aVF, V2-V6). NSTEMI-ACS very high risk was diagnosed. Our second case, 31 years old women came to ER with general weakness, epigastric pain, and vomiting. Patient heart rate was 84 bpm, blood pressure was 150/102 mmHg, with respiratory rate of 20/minute, and oxygen saturation of 99%. The ECG results showed a QT prolongation with plateau ST elevation in aVR with global horizontal and up slopping ST depression (I, II, aVF, V2-V6). Severe hypokalemia was suspected, and confirmed with potassium concentration of 1.3 mmol/L.

Conclusions: ST-Segment depression could be tricky for untrained eye. Clinicians should know to assess the morphology of ST-Segment depression, which could have deleterious effect when wrong interpreted. Down slopping and horizontal ST-Segment depression suggestive an ischemia event, but up slopping suggest a non-ischemia event.

Keywords: ST-Segment Depression, Morphology





Challenges in Managing ST-Elevation Myocardial Infarction (STEMI) Anteroseptal with Diabetes Mellitus in a Rural Area Hospital: A Case Report

C. Dharwindo¹
Rumah Sakit Penyangga Perbatasan¹

Background: ST-Elevation Myocardial Infarction (STEMI) is a medical emergency that requires prompt diagnosis and treatment to prevent significant morbidity and mortality. Diabetes Mellitus (DM) is a known risk factor for cardiovascular disease and increases the risk of developing a STEMI. In rural areas, the management of STEMI can be challenging due to limited resources, inadequate healthcare infrastructure, and delayed patient presentation. This case report describes the challenges encountered in the management of a patient with STEMI Anteroseptal and DM, who presented to a rural area hospital.

Case Illustration: An 84-year-old male with a past medical history of diabetes mellitus presented to the emergency department with complaints of atypical chest pain that had been ongoing for 2 days. The patient reported that the pain was initially mild but had progressively worsened over the last few days. The patient denied any shortness of breath, dizziness, or syncope. Upon arrival, the patient's vital signs were stable, with a blood pressure of 125/85 mmHg, heart rate of 85 beats per minute, and oxygen saturation of 98% on room air. Physical examination revealed no significant findings, except for mild tenderness to palpation in the chest area. An electrocardiogram (ECG) was performed, which showed evidence of ST-segment elevation in the anterior and septal leads consistent with an acute ST-segment elevation myocardial infarction (STEMI). The patient was not a candidate for thrombolysis due to his advanced age and increased risk of bleeding. Therefore, he was managed conservatively because the family refuse transferred to a tertiary care center for further management.

Conclusion: Diabetic patients with STEMI may not experience typical chest pain. Instead, they may present with no symptoms at all. This can make it more challenging for healthcare providers to identify and treat the condition.

Keywords: STEMI, diabetes mellitus, rural area, heart failure

HOW TO IDENTIFY PERIPROCEDURAL MYOCARDIAL INFARCTION IN CALCIFIED CORONARY LESION: A CASE REPORT

T. Aryanugraha¹, M.S. Rohman¹

¹Departement of Cardiology and Vascular Medicine, Faculty of Medicine, Brawijaya University - dr.Saiful Anwar General Hospital, Malang East Java, Indonesia

Background:

Periprocedural myocardial infarction (MI) is frequent complication of percutaneous coronary intervention (PCI) associated with an increased rate of cardiovascular events. However, the detection of periprocedural MI in calcified coronary lesion is still not clear.

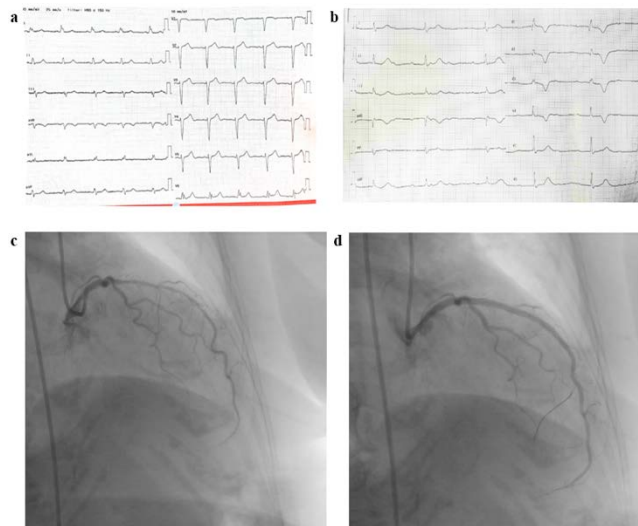
Case Illustration:

A 73 year-old female came to our hospital because of stable chest pain while doing moderate activity. Four month prior to admission, she had diagnostic coronary angiography procedure with calcified long stenosis 80-90% in proximal-mid left anterior descending (LAD) artery was reported. Clopidogrel and aspirin were routinely consumed as dual antiplatelet therapy. PCI procedure was conducted with predilatation Scorflex NC balloon 2.5 x 15 mm at proximal-distal LAD then implantation of 2 DES, Cre8 3.5 x 46 mm at ostial-distal LAD and Combo Plus 3.5 x 15 mm at distal LAD (overlapped). She felt chest pain after procedure that relieved by isosorbide dinitrat. Fifteen hours after the PCI procedure, the patient felt weakness, bradycardia with total atrioventricular block seen in the ECG monitor and increased of troponin I level (0.7 g/L □ 12.1 g/L) and the patient was diagnosed with myocardial infarction associated with PCI. We treated the patient with dual antiplatelet therapy and unfractionated heparin (UFH) bolus continued with continuous infusion until 2x24 hours. Coronary angiography evaluation showed stent under-expansion with septal branch occlusion because of shifting plaque. Temporary pace maker (TPM) was inserted for 7 days. Due to the patient still pacemaker dependent, permanent pace maker (PPM) was implanted. She also had complication of pneumonia during hospital care. No event of subsequent acute coronary syndrome was observed.

Conclusion:

The periprocedural myocardial infarction in the calcified coronary lesion could be identified from the patient's clinical symptom, physical examination and further investigations such as electrocardiogram changes, increase in cardiac enzymes, echocardiography changes, and coronary angiography findings. This patient requires thorough observation and monitoring.

Keywords: Periprocedural Myocardial Infarction, Percutaneous Coronary Intervention, Calcified Lesion, Complete Atrioventricular Block, Side Branch Occlusion



RETROGRADE TYPE A AORTIC DISSECTION WITH AN ENTRY TEAR IN DISTAL DESCENDING THORACIC AORTA: A RARE CASE REPORT

G. S. Ambara¹, B.A.P. Dwi Sutanegara¹, A.P. Suwirya¹

¹Department of Cardiology and Vascular Medicine, Faculty of Medicine Udayana University, RSUP Prof. dr. I. G. N. G. Ngoerah, Denpasar, Indonesia

Background

Retrograde type A aortic dissection (RTAAD) is defined as a dissection with the primary entry tear occurs distal to the left subclavian artery (LSA) and the dissection propagates retrogradely into the ascending aorta.

Case Illustration

Male, 47 years old, complained of back pain since 3 days ago and worsened 1 day ago. Back pain feels like being stabbed and slashed. He had a history of uncontrolled hypertension since 2 years ago and smoked 1 packed/day. Physical examination revealed irregular heart sound and without murmur. Transthoracic echocardiography revealed aortic root dilatation and seen intimal flap on the ascending aorta. CT-scan thoracoabdominal with contrast revealed fusiform aneurysm from ascending aorta until common iliac arteries accompanied by intraluminal thrombus and seen leakage contrast as high as thoracic 10, suspect intimal tear in distal descending thoracic aorta. Patient was treated in the cardiac intensive care unit and after heart team meeting, patient was planned for total aortic arch replacement with frozen elephant trunk (FET) procedure.

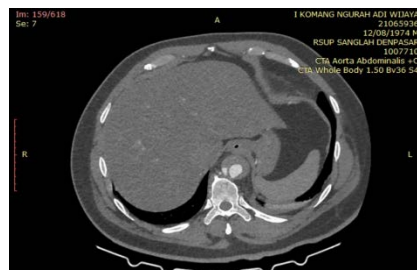Discussion


RTAAD can be spontaneous or iatrogenic, especially when the proximal aorta is already dilated over 40 mm. Management of spontaneous RTAAD is currently not standardized with reports of successful treatment with optimized medical therapy, open surgery and/or endovascular repair. Conservative medical therapy has been successful for cases with completely thrombosed false lumen in the ascending aorta, providing the aorta that it is not dilated beyond 55 mm. On the other hand, presentation with a patent false lumen in the ascending aorta, pericardial effusion, aortic regurgitation or malperfusion mandates expedited surgical treatment (i.e. total aortic arch replacement with FET procedure).

Conclusion

RTAAD has anatomical differences compared to antegrade TAAD that impact the management and prognosis. Management is yet not standardized. Aggressive treatment for RTAAD with the exclusion of the primary entry tear to prevent immediate-complications and mid-term complications.

Keywords: RTAAD, optimized medical therapy, aortic arch replacement with FET procedure





Transesophageal Echocardiography Evaluation of Patent Ductus Arteriosus Percutaneous Device Closure: a new window to the heart

A.F. Ghaznawie¹, A.T.S. Adam¹, Y. Patimang¹, A.A.U. Armyn¹, M.I. Nurkholis¹
Hasanuddin University¹

Background: Transesophageal echocardiography (TEE) is a modality that can be used to monitor ductal flow before and after patent ductus arteriosus (PDA) closure, enabling a pediatric cardiologist to discover any residual shunts and providing ultimate confirmation of PDA closure. In this case report we present a 18-year-old girl with patent ductus arteriosus scheduled for device closure. Transesophageal echocardiography was performed to assess morphologic characterization of the ductus and surrounding structures, assess of the shunt magnitude, to estimate pulmonary artery pressures as well as to evaluate the device patency post-procedure.

Case illustration: A 18-year-old girl (38 kg) diagnosed with PDA was scheduled for device closure. Pre-procedural transthoracic echocardiography (TTE) showed a PDA sized 8-9 mm with a left-to-right. The systolic pressure gradient was 87.96 mmHg and the diastolic gradient was 21.41 mmHg. Along with PDA, severe mitral regurgitation due to prolapse AML (Carpentier type II) and moderate pulmonary regurgitation was assessed. A single-plane TEE probe was inserted in the patient's esophagus after tracheal intubation and general anesthesia. Pre-closure 2D TEE color doppler flow imaging showed a PDA sized 7.8 - 8 mm with a left-to-right shunt through the PDA (systolic gradient: 60.55 mmHg, diastolic gradient: 14.27 mmHg). A further evaluation using 4D TEE imaging, a dynamic change in the PDA throughout the cardiac cycle can be observed. Transcatheter closure was then performed and a PDA sized 7.78 mm was viewed. An occluder (size 14-16) was then inserted. Post-closure TEE monitoring revealed a well-seated PDA occluder with no residual shunt on color doppler imaging. The TEE probe was then withdrawn and no complications were encountered during the procedure.

Conclusion: We reported a 18-year-old girl with PDA who underwent device closure procedure. Transesophageal echocardiography was performed to evaluate the shunt pre and post procedure. Studies report that TEE consistently outperformed TTE for PDA visualization, and when compared to the former, the latter revealed greater values for ductal dimensions. 2D and 4D TEE is a useful and efficient and precise tool for device size selection, having only small differences in measurements compared to catheterization. TEE also holds a great role in post-procedural evaluation of the device placed.

Keywords: transesophageal echocardiography, patent ductus arteriosus, percutaneous device closure

Anomalous Coronary Artery From Opposite Sinus (ACAOS) LCx Originated from RCA with Coronary Artery Minor Disease. Does It Really Benign ?

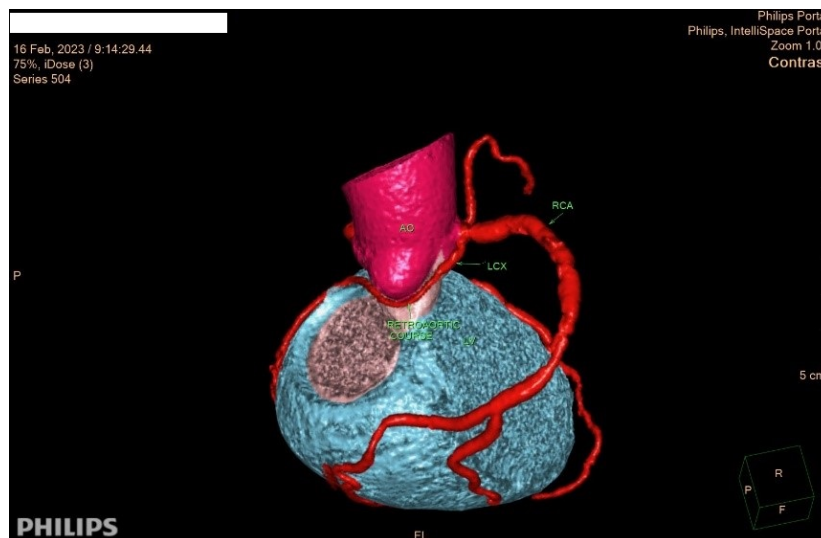
O.W. Firmansyah¹, B.S. Pikir¹
Universitas Airlangga¹

Background: Anomalous coronary artery from opposite sinus (ACAOS) is the rare condition that can affect 1% population in general. Classification varies from benign to malign related to risk of sudden cardiac death (SCD) event. In the absence of the anatomical risk, Such cardiac event related to myocardial infarction can make difficult situation for interventionist to perform.

Case Illustration: the 60 years old female come with chief complaint of chest pain that worsen at the moderate to high physical activity. CT cardiac was performed and revealed that the patient has Anomalous Coronary Artery Originated from Opposite Sinus (ACAOS), in which Left Circumflex Artery originated from Right Coronary Artery. The patient is also had Coronary Artery Disease (CAD) minor disease (CAD RADS-3). Although the anomalous condition is categorized as benign, The patient is still planned for secondary prevention such as lifestyle modification and adequate medication to stop the progression of CAD minor disease and improve the condition.

Conclusion: ACAOS LCx originated from RCA is rare but benign condition with low risk of SCD. There is no need of intervention of this patient regarding on the anomaly, but the patient definitely need the intervention in secondary prevention to prevent further progression of CAD and avoid unwanted event in future.

Keywords: Coronary Anomaly, CT Cardiac, CAD Minor Disease, Secondary prevention.



Sinus of Valsalva Aneurysm with Great Dilatation and Coarctation of Aorta in A Middle-Aged Adult Male : A Rare Case Report

R. Antonius¹, J.K.P. Phie¹, A.F. Ghaznawie¹
Department of Cardiology Hasanuddin University¹

Background : Sinus of Valsalva Aneurysm (SOVA) is an enlargement of the aortic root area between the aortic valve annulus and the sinotubular ridge. SOVA is a rare heart condition is well known for its potentially fatal complications when rupture occurred. The prevalence of congenital SOVA is estimated to be 0.09% of the general population.

Case Illustration : We report a 47 years old male, admitted to the hospital with shortness of breath during exercise, at night and on lying down. History of hypertension for 10 years. Physical examination showed irregular pulse, distended jugular vein, pulsus Corrigan and diastolic murmur at upper right sternal border. Electrocardiogram presented an atrial fibrillation. Laboratory findings within normal limit. Screening for syphilis showed negative results. Echocardiography showed great dilatation of aortic annulus and aortic root mainly sinus of Valsalva RCC portion (7,1 cm), dilatation of brachiocephalic trunk and pulmonary arteries, suggestive coarctation of aorta, severe aortic regurgitation due to uncoaptation of cusps. The echocardiography findings was confirmed by Cardiac CT scan and Aortography. The patient was diagnosed with sinus of valsalva aneurysm, coarctation of aortae and aortopulmonary shunt, severe aortic regurgitation, congestive heart failure and atrial fibrillation. The patient was treated with diuretic, mineralocorticoid antagonist, vitamin-K antagonist, ACE-inhibitor, followed by beta-blocker. Bentall procedure surgery was further suggested for the defect structure correction.

Conclusion : SOVA with intracardiac abnormalities is recommended in guidelines for further surgical intervention to repair the aortic root aneurysm. According to the 2010 American Guidelines on Thoracic Aortic Disease, surgical repair should be considered in those with aneurysms >5.5cm. Correcting the aortic valve and aortic root, alongside coarctation of aortae repair could be done with Bentall procedure by cardiothoracic surgeon.

Keywords: Sinus of Valsalva Aneurysm, Coarctation of Aorta, Severe Aortic Regurgitation

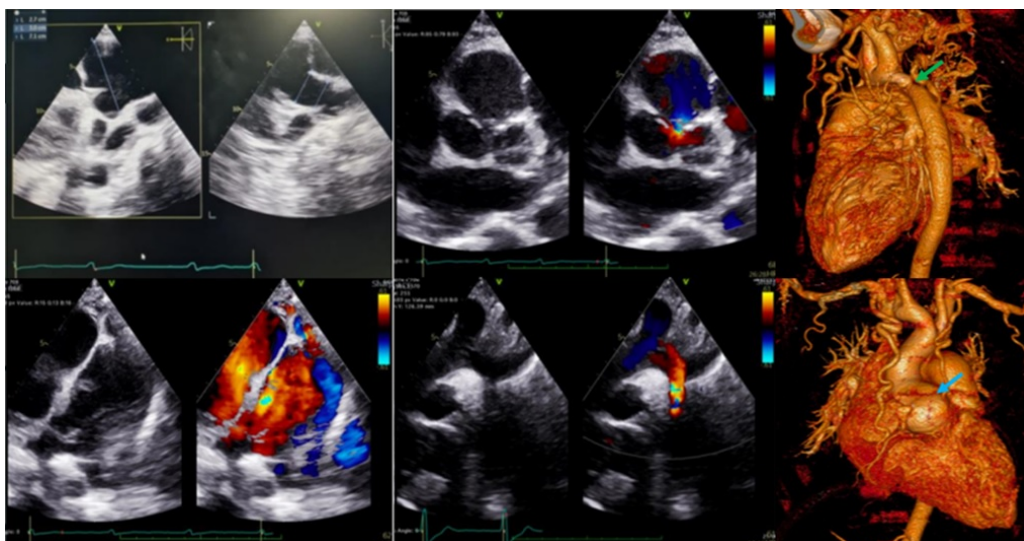


Figure 1. TransThoracal Echocardiography and MSCT Cardiac Aortography

Heparin Treatment in Patients Deep Vein Thrombosis with End-Stage Renal Disease: A Case Report

A.A. Budiarto¹, Ahadi²

Medical Intern, Dr. R. Sosodoro Djatikoesoemo General Hospital, Bojonegoro, Indonesia.¹

Cardiologist, Dr. R. Sosodoro Djatikoesoemo General Hospital, Bojonegoro, Indonesia.²

Background

Patient end-stage renal disease (ESRD) is associated with a 2.3-fold increased risk of deep vein thrombosis (DVT) compared with the general population. DVT is a potentially life-threatening condition that comes under the category of venous thromboembolism (VTE). ESRD with VTE was associated with increases in the risk of death, VTE recurrence, and major bleeding. This case describes and highlights the importance of the treatment of DVT in patients with ESRD.

Case illustration

A 50-year-old female patient, with a medical history of hypertension for the past 10 years without routine treatment and chronic kidney disease stage V for the past 7 months, was on maintenance hemodialysis two times a week. She had a problem with an arteriovenous shunt so the hemodialysis was performed via dialysis catheters in the femoral site. However, she had a complaint of swelling in her right leg after the removal of dialysis catheters. The swelling felt to getting more significant in a month and she was taken to our hospital. On physical examination show swollen tender right leg. The US investigation demonstrated non-compressible femoral veins. A diagnosis of acute deep vein thrombosis lower right extremities were made. Unfractionated heparin (UFH) is preferred in the clinical setting to LMWH or Fondaparinux and is given intravenously in the hospital with laboratory monitoring. UFH in a therapeutic dose was initiated with bolus 5,000 U followed by maintenance 24,000 U/24 hours. The right femoral vein thrombosis resolved after 2 weeks with twice dose adjustments. A haematological workup did not reveal the presence of any hypercoagulable disorder. During the administration of heparin therapy did not find any complications.

Conclusion

The results of our case suggest that the treatment of DVT of the limbs with heparin in patients with ESRD is an effective and safe therapy.

Keywords: heparin, deep vein thrombosis, chronic kidney disease

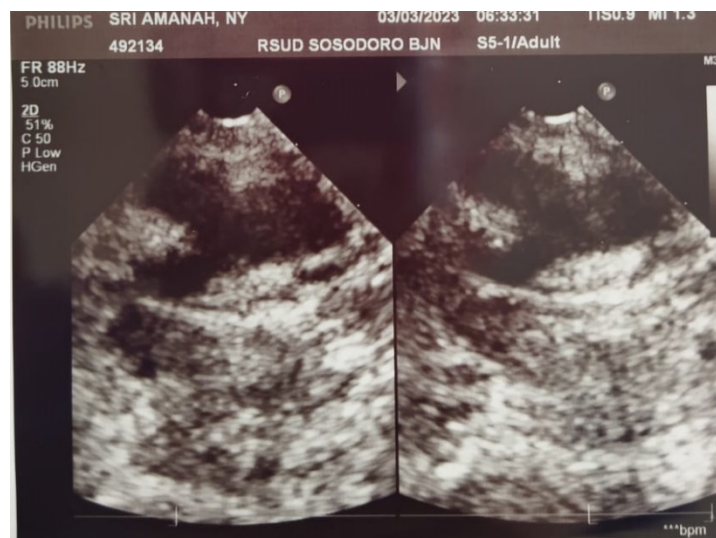

Fig 1. The US investigation demonstrated non-compressible femoral veins

UNSTABLE ATRIAL FIBRILLATION WITH RAPID VENTRICULAR RESPONSE (RVR) IN HYPOGLYCEMIA PATIENT, A POSSIBLE AND RARE CAUSE : A CASE REPORT

A. Siswanto¹
RSD Balung Jember¹

Background

Atrial Fibrillation (AF) is defined as tachyarrhythmia originated from supraventricular, firing wildly electrical activation thus making atrium contracts inadequately. It has three distinct characteristics from Electrocardiogram (ECG), such as irregularly irregular R-R intervals, no p wave, and irregular atrial activations. It can be caused by endocrine disorders, one of them is Diabetes Mellitus (DM). Studies have shown that this life threatening arrhythmia may be related to hypoglycemia condition which can be induced by DM treatments.

Case Illustration

A 50-year-old woman was referred to our Emergency Room (ER) for feeling dyspneic and palpitations. Her family told that she had cardiac problem before, but did not know about her medications, including the possibility of having history of DM. Her vital signs showed tachycardia (197 beats/min) and oxygen saturation 88% despite using Non-Rebreather Mask 15 lpm. On physical examination, her jugular vein pressure was increased and her ictus cordis shifted laterally. This was confirmed by her Chest X-Ray that showed cardiomegaly. The cardiac monitor showed AFib then the patient was treated with synchronized cardioversion 125 J. The rhythm was converted to sinus rhythm with rate 159 beats/min. From the laboratory studies, serum glucose was 14mg/dL then d40% was given intravenously. After that, the monitor showed SVT with rate 300 beats/min so the patient was treated with synchronized cardioversion 50 J again. The rhythm was converted to sinus with PACs with rate 160 beats/min.

Conclusion

Atrial Fibrillation is one of dangerous cardiac arrhythmia for it can form thrombus and causing stroke. Diabetic and hypoglycemia condition is now emerging as major risk factor for developing AFib. Therefore, patients with DM needs appropriate control of serum glucose and cardiac monitoring every once in a while.

Keywords: atrial fibrillation, diabetes mellitus, hypoglycemia




Figure 1. Monitor showed AF first (A), then SVT (B) after glucose administration intravenously



BRASH Syndrome as an under-recognized life-threatening complication: A Case Report

A.O. Aslani¹, G. Octania², A.U. Dewi¹, R.H. Wibowo¹, T.A. Sabrawi¹
RSUD Kabupaten Sumedang¹
Universitas Padjadjaran²

Background

Bradycardia, renal failure, atrioventricular (AV) node blockade, shock, and hyperkalemia (BRASH) syndrome occurs in patients consuming AV-blocking medication. Clinicians often missed diagnosing BRASH syndrome due to the under-recognition of this syndrome. Here we report a case of a patient with chronic heart failure (CHF) and atrial fibrillation (AF) who takes medications regularly that presented life-threatening conditions.


Case Illustration

A 72-year-old female patient presented with a chief complaint of gradually worsening dyspnea. The previous history of heart disease was confirmed. The patient was taking bisoprolol 2.5 mg once daily, sacubitril-valsartan (Uperio™) 100 mg twice daily, furosemide 40 mg PRN, spironolactone 50 mg once daily, and warfarin 3 mg every night. Physical examination revealed bradycardia, cold and cyanosis of the distal extremities with CRT (capillary refill time) longer than 2 seconds. Laboratory findings showed uremia and severe hyperkalemia. Findings from electrocardiogram (ECG) include junctional bradycardia with tall T wave. She was treated with lansoprazole, atropine sulfate, dopamine, and calcium gluconate infusion. All regular medications were stopped, except for warfarin, and the patient underwent emergency hemodialysis. After 6 days of hospitalization, the patient responded well and was discharged home.

Conclusion

BRASH syndrome should always be considered in patients presenting with shock accompanied by bradycardia, uremia, hyperkalemia, and routine consumption of AV-nodal-blocking medications. We highlight the importance of recognizing BRASH syndrome, especially in emergency settings, to be able to administer rapid and appropriate management to the patients. Therefore, we can improve the patients' prognosis.

Keywords: BRASH, bradycardia, renal failure, hyperkalemia, shock



Ischaemic Stroke and Subarachnoid Haemorrhage as the Complication of Infective Endocarditis in Young Male: A Case Report

A.O. Aslani¹, Z. Haryawan², A.U. Dewi¹, R.H. Wibowo¹, T.A. Sabrawi¹
RSUD Kabupaten Sumedang¹
RSUD Ciamis²

Background

Infective endocarditis (IE) is an uncommon but potentially fatal infectious disease. One of the common complications of IE is the embolization of endocardial vegetations with subsequent intracerebral artery obstruction that causes an acute ischaemic stroke. Here we present a case report of a patient presented with a neurological manifestation that turned out to be the complication of IE.

Case Illustration

We present a patient with a chief complaint of left hemiplegia. Bloodwork showed signs of infection. Head CT scan showed extensive infarction on the right lobe and subarachnoid hemorrhage. Echocardiography showed vegetation on the aortic valve suggesting the diagnosis of IE as the source of the embolization. The patient was then treated with supportive stroke therapy, high-dose ampicillin and gentamicin, and physical rehabilitation.

Conclusion

IE can be considered as one of the causes of acute ischaemic or haemorrhagic stroke. Ruling out other common causes of stroke and noticing signs of infection and vascular phenomenon should help defining the diagnosis. Echocardiography could help identifying valvular vegetation. Treatment consists of high-dose penicillins and supportive therapy for stroke.

Keywords: Infective endocarditis, stroke, young age

Ventricular Septal Defect Complicated with Acute Pulmonary Embolism: How it can be Happened?

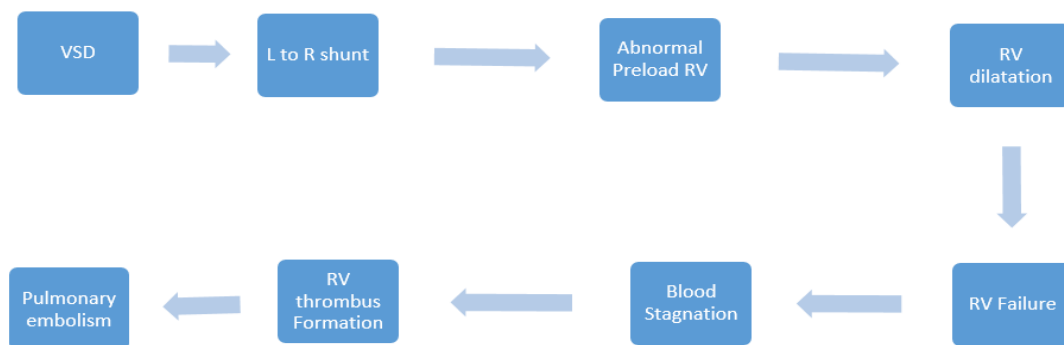
Andrianto¹, T. Santoso¹, E. Rosmillah¹, R.A. Nugraha¹, B.P. Dharma¹
General Hospital dr. Soetomo¹

Background: Acute pulmonary embolism is one of cardiovascular emergency that occurs due to pulmonary artery occlusion. However, pulmonary embolism in this case is caused by right ventricle (RV) failure with congenital heart disease, which is VSD. The RV failure results in blood stagnation because of RV wall contraction impairment that accordance with Virchow's triad as venous stasis, then induce thrombus formation. This case is rare because only 4% of all pulmonary embolism accompanied by RV thrombus, in addition it is also accompanied by VSD. This case begins with VSD and become RV failure. The stagnation of blood, accompanied by RV failure promotes RV thrombus. this thrombus can break off and result in an acute pulmonary embolism. Virchow's triad in which one of the predisposing factors is static flow.

Case Illustration: A 79-year-old woman came to ED of main referral hospital presence worsening dyspnea. The physical examination showed hemodynamically unstable increasing JVP, continuous murmur in intercostal 2 right parasternal. The ECG displayed T inversion and Q wave in lead III, S in lead I. The CXR displayed dilated central PA. TTE displayed dilatated RA and RV, thrombus (1,4 x2,2 cm) in apex RV, Mc Conell sign, and decreasing RV systolic function, and IVS defect (0.9 cm diameter), and mPAP 47,5 mmHg. The patient was diagnosed obstructive shock e.c. acute pulmonary embolism (WELLS score 6 (moderate risk) RIETE score 2 (moderate), PESI 229 (very high risk)) with RV failure and VSD perimembran. the patient was sent to intensive care unit, follow by anticoagulation and thrombolytic. during the stabilization, the patient was gone.

Conclusion: The case about VSD manifest pulmonary embolism through RV failure is rare. The mechanism is VSD leads to RV failure, which occurs blood stagnation, then promotes RV thrombus formation, and manifest acute pulmonary embolism.

Keywords: Congenital Heart diseases; Pulmonary Embolism; Ventricular Septal Defect; Acute Cardiac Care.



Pathophysiology

Sudden Total Atrioventricular Block, Is Pacemaker The Only Treatment? : A Case Report

P.E.D. Putri¹, A.P. Suwirya²

Faculty of Medicine, Universitas Hang Tuah, East Java, Indonesia¹

Department of Cardiology and Vascular Medicine, Faculty of Medicine, Universitas Udayana, Prof. I.G.N.G. Ngoerah General Hospital, Bali, Indonesia²

Background

Total Atrioventricular Block (TAVB) is a rare disorder of the cardiac conduction system. Some electrolyte imbalances are thought to affect the heart conduction system, but TAVB is one of the uncommon presentations. This presentation aims to brief the management of conduction abnormalities caused by electrolyte imbalance.

Case illustration

A previously healthy 28-year-old male complained of epigastric pain, a burning sensation, nausea, and vomiting one day before admission. The patient was alert with blood pressure (BP) of 120/70mmHg; heart rate (HR) of 75 bpm; respiratory rate (RR) of 22 x/min; and normal oxygen saturation. Laboratory studies revealed elevated White Blood Cells $19.33 \times 10^3/\mu\text{L}$ with predominantly neutrophil 84,5 %. Four hours after admission, his complaints of palpitation, nausea, and vomiting worsened. He had vomited more than ten times. His BP was 120/70 mmHg and his electrocardiography showed a Total Atrioventricular Block with a ventricular rate of 28 bpm. He received sulfa-atropin 0,5mg and dopamine 325 mcg drip. Further laboratory studies revealed a high C-Reactive protein (CRP) of 116.30 mg/dl, Erythrocyte sedimentation rate (ESR) of 60 mm/hours, and electrolyte imbalance, with potassium serum 5.18 mmol/L and calcium serum 8.1 mg/dL. His troponin I and CKMB was normal. Echocardiography demonstrated a Left Ventricle Concentric remodeling without other anatomical and functional abnormalities. Based on those data, the patient was diagnosed with TAVB caused by electrolyte imbalance, then received calcium gluconate 1 gram/10mL three times a day and potassium polystyrene sulfonate 5 grams three times a day. After a week of hospitalization, he got fully recovered.

Conclusion

The treatment of emergency TAVB consists of medication and pacemaker implantation. Finding the etiology of TAVB is mandatory, which can be seen from the patient's clinical condition, laboratory findings, and comorbidities.

Keywords: hyperkalemia, Hypocalcemia, High degree atrioventricular block, Electrolyte Imbalance

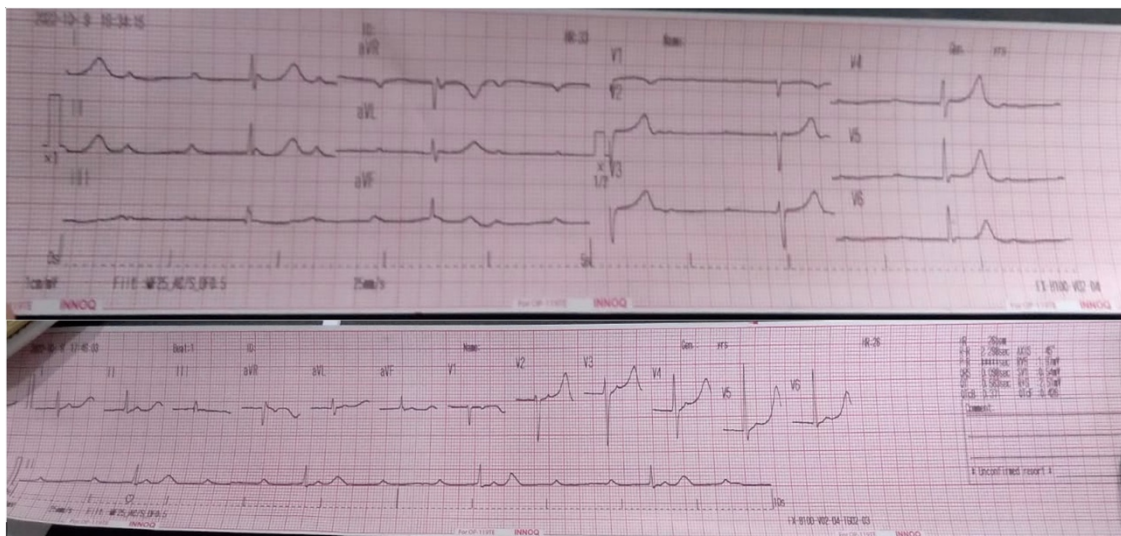


Figure 1. ECG shows Total Atrioventricular Block

Constrictive Pericarditis: A Forgotten Cause of Right Heart Failure

P.D.P. Lestari¹, M.A.W. Sari¹, M.W. Asih²

¹Department of Cardiology and Vascular Medicine, Prof. dr. I.G.N.G. Ngoerah Hospital Bali, Faculty of Medicine Udayana University¹

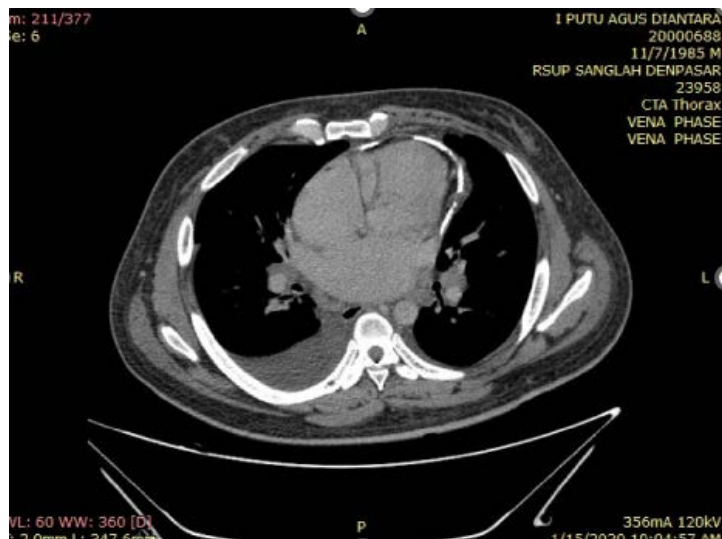
²Department of Radiology, Prof. dr. I.G.N.G. Ngoerah Hospital Bali, Faculty of Medicine Udayana University²

Background: Constrictive pericarditis is a well-known but rare and commonly forgotten cause of right heart failure. Early diagnosis of constrictive pericarditis is difficult due to absence of typical cardiopulmonary signs and multiple vague symptoms and its insidious course.

Case illustration: A 34-year-old man presented with shortness of breath since 4 days ago accompanied with ascites and pitting edema. He had a history of heart failure due to coronary artery disease, but already done coronary angiography with no significant stenosis. Physical examination found signs of congestion with predominantly ascites and edema on both legs with dominant on the right leg. Echocardiography found biatrial enlargement and right ventricle dilatation, decreased right and left systolic function with uncoordinated septal wall motion, decreased left ventricle diastolic function grade II, mild tricuspid regurgitation with high probability of PH, and echo dense structure compress base of left ventricle, half of left atrium suspect extracardiac mass. Doppler ultrasound was consistent with deep vein thrombosis right lower extremity. CT Scan Thorax with contrast found heterogeneous density suspect benign pericardium mass dd/ pericardium thickening due to chronic inflammation, constrictive pericarditis. During hospitalization, there was decreasing renal function, so we planned hemodialysis. We planned to do an excision biopsy, but the patient refused. Constrictive pericarditis may have sign of systemic congestion like right heart failure. The right heart failure caused by several etiology with different pathophysiology that effect the management and prognosis, but constrictive pericarditis is a rare condition that may cause right heart failure.

Conclusion: We described a patient with constrictive pericarditis, acute kidney injury, DVT. Right heart failure may be the first clinical symptom in constrictive pericarditis. Thorough examination is needed to diagnose constrictive pericarditis.

Keywords: Ascites, echocardiography, constrictive pericarditis, right heart failure.



CASE SERIES OF SURVEILLANCE AFTER FONTAN PROCEDURE: THE ROLE OF MRI IN EVALUATING SINGLE VENTRICLE PHYSIOLOGY

C. Abdillah¹, O. Lilyasari¹
Faculty of Medicine Universitas Indonesia¹

Background: Fontan circulation is one of the most common procedure to treat complex congenital heart disease. Echocardiography had limitation due to poor acoustic window in older patients. Cardiac Magnetic Resonance Imaging (MRI) have been validated as an important modality to evaluate major complication of the Fontan circulation. The objective was to present serial cases of patient with history of Fontan and explain the role of MRI as an advanced imaging technique to evaluate long-term complications.

Case Illustration: Case 1 illustrate a 15 years old female with history of Fontan fenestrated procedure came to ER with dyspnea on effort. Echocardiographic examination showed suspicion of intraconduit thrombus formation, which was confirmed with MRI examination. The patient underwent heparinization in intermediate ward and was given oral thrombolytic therapy.

Case 2 illustrate a 13 years old female came to outpatient clinic with history of swelling in face and legs. She had already treated with Fontan fenestration procedure in June 2011. The echocardiographic study revealed the anastomoses was unclear with suspicion of Fontan conduit obstruction. MRI revealed stenosis in Fontan conduit at the level of diaphragm. She therefore may continue her previous medication while she was scheduled for cardiac catheterization in order to stent the stenotic area.


Case 3 illustrate a 22 years old female with history of Fontan procedure in 2006. She didn't have any major complain. The MRI examination was done as surveillance strategy to evaluate Fontan pathways. Stenosis at pulmonary artery bifurcation and origin of pulmonary artery branches was noted, and she may continue her medication with plans for reexamination in the following year.

Conclusion: Advanced imaging modalities, particularly cardiac MRI, are of importance in recognition of failing hemodynamic of Fontan which is essential for long-term survival. Appropriate imaging protocol and surveillance strategy are needed to assess the anatomy, prognosis and complication in univentricular heart.

Keywords: Fontan procedure, MRI, Single Ventricle, Surveillance

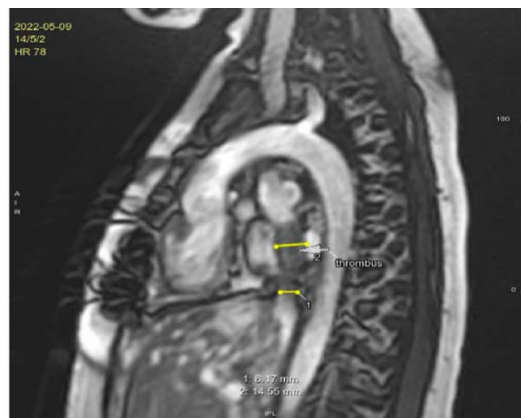

Figure 1. Thrombus detected in MRI evaluation



Multiple and mixed valvular heart disease in a young woman with joint pains

F. Resi¹, C.K. Krevani²

- ¹. Cardiology and Vascular Medicine Residency, Andalas University, Padang, West Sumatera.
- ². Cardiology and Vascular Medicine Department, M. Djamil Hospital, Padang, West Sumatera.

Background

Multiple valve heart disease (VHD) is most often acquired. In the Euro Heart Survey, rheumatic fever was the predominant pathogenesis (51%). Mitral valve disease and joint pains are commonly caused by rheumatic heart disease (RHD). Other causes of mitral valve disease and polyarthritis should be considered in the differential diagnoses. We report a rare case multiple and mixed valvular heart disease in a young woman with joint pains.

Case Illustration

A 22 year old lady presented with polyarthritis and morning stiffness involving bilateral knees, ankles, elbows, wrists, metacarpophayngeal and proximal interphalyngeal joints for one month. Patient had history of polyarthritis from 9 years before with inappropriate treatment because she did not go to a health care facility. Rheumatoid factor has raised. She came to us for evaluation of a mid-diastolic murmur heard loudest over the apex and a soft diastolic murmur heard loudest at 3rd – 4th intercostal space at the left sternal edge. Echocardiogram showed mitral stenosis (MVA 1.6 cm²), mitral regurgitation, tricuspid stenosis, tricuspid regurgitation and mild aortic stenosis, with EF 66% and good right ventricular function. After multidisciplinary evaluation, she has gotten mitral valve replacement, aortic valve replacement and tricuspid valve repair.

Conclusion

Multiple and mixed VHD are highly prevalent conditions. Mixed mitral VHD in young women mainly results from rheumatic processes. RHD is the most common cause of mitral valve disease and joint pains in developing world but other rare causes including rheumatoid arthritis should be considered in differential diagnosis. This case highlights the importance of characteristics of rheumatic and non-rheumatic origin of valvular heart disease.

Keywords: Multiple and mixed valvular heart disease, rheumatic heart disease, mitral valve disease, joint pains

A Spontaneous Resolution of Acute Inferior MI Concomitant Complete AV Block in Rural Primary Health Care : A Case Report

M. Aulia¹, A.I. Pratiwi¹, S.H. Aulia², I.M. Sufiyah³
Public Health Center of Patani¹

Student of Medical Faculty of Airlangga University, Surabaya - Indonesia²

General hospital Dr. Soetomo, Department of Cardiology and Vascular Medicine, Medical Faculty of Airlangga, Surabaya³

Background: In acute inferior MI, where the RCA is often the culprit, high-grade AV block has been described in up to 17% of cases. Complete AV block is known to be reversible in some cases of acute inferior MI. Spontaneous reperfusion in the setting of ST-elevation ACS is reported in up to 30% of patients.

Case Illustration: A 56-year-old man was admitted with left chest pain 1 hour before he was taken to the ER of PHC. Chest pain felt tight and heavy, radiating to the left arm, accompanied by nausea and weakness. Thirty minutes earlier, he had fainted during the activity. He had uncontrolled hypertension and 30-year smoking history. He was fully conscious and revealed cold, clammy and pale skin. His BP 80/palpation mmHg, HR 32bpm, RR 18bpm and SaO₂ 97%. The ECG showed ST elevation in leads II, III, aVF and complete AV block. He was diagnosed with acute inferior MI, complete AV block, and cardiogenic shock. He received fluid loading RL 1000 cc within 30 minutes, maintenance fluid therapy 1500cc/24 hours, and Aspirin loading 320mg. The final BP 110/70mmHg and HR 68bpm. He was referred to the nearest hospital (a 5-hour drive) for further examination and treatment. Blood tests and CXR showed normal findings. The ECG showed that the STEMI and TAVB spontaneously resolved.

Conclusion: This case highlights the importance of early prehospital care in the rural PHC to treat life-threatening conditions and improve outcomes in acute inferior MI and concomitant complete AV block. Prompt initial treatment is crucial to prevent from failing in hemodynamic instability and reduce mortality. Extreme geographic, distance and socio-economy were challenging for the doctors to be more concerned about the patient's clinical condition and vital signs while referring the patient to the hospital.

Keywords: Acute Inferior MI, Complete AV Block, Spontaneous Resolution

Figure 1a. ECG taken during the hemodynamic instability at the PHC.

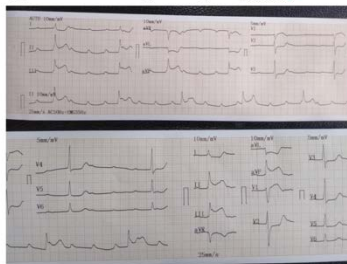
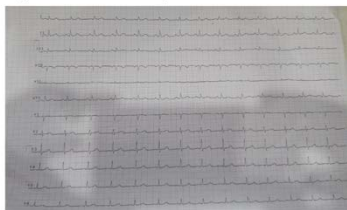



Figure 1b. ECG taken at the hospital.



SEVERE RHEUMATIC MITRAL REGURGITATION WITH SIGNIFICANT PERICARDIAL EFFUSION IN A CHILD: A CHALLENGE IN RURAL AREA

Y. Natanael¹, A. Almira², Hendrianus³
Ruteng Public Hospital¹

Brawijaya Women and Children Hospital Antasari²



Cardiology and Vascular Medicine Resident, Faculty of Medicine Universitas Indonesia, National
Cardiovascular Center Harapan Kita³

Background: Mitral valve regurgitation (MR) is one of the most common valvular abnormality at the early rheumatic heart disease (RHD) stages, whereas pericardial effusion can be present although rarely large enough to present with tamponade physiology. These conditions may result in early heart failure manifestations at young age, which causes disability and premature death in many countries.

Case Illustration: An 11 years old girl was referred from a rural public hospital with worsening dyspnea since the last one month. She commented on one month history of palpitation before admission and migrating arthralgia since 2018. Upon arrival, she was fully alert with the following vital sign: blood pressure 85/55 mmHg, radial pulse of 116 bpm, respiratory rate of 24 breaths/min, body temperature of 36.7°C and oxygen saturation of 99% on room air. Her height and weight were 137 cm and 28 kg respectively. Physical examination revealed a fast regular rhythm with III/VI pansystolic murmur at mitral area. A 12-lead electrocardiogram evaluation showed a sinus rhythm with ST segment depression at V5-V6 and the chest X-ray demonstrated cardiomegaly with a third mogul sign. Transthoracic echocardiography revealed a severe MR with moderate pericardial effusion, mild aortic regurgitation, left ventricle dilatation with ejection fraction of 63% and left atrial dilatation. The patient was hospitalized for 13 days with intravenous furosemide, bisoprolol, ramipril, spironolactone, oral methylprednisolone, and secondary rheumatic prophylaxis with erythromycin. Her condition gradually improved and the pericardial effusion significantly subsided. She then was prepared for referral to a tertiary cardiac center for surgical management.

Conclusion: This case highlights the challenge of RHD with pericardial effusion management and the urgency to improve awareness of RHD in a limited access to pediatric cardiac services, thus reducing the complication and improving the patient's quality of life.

Keywords: rheumatic heart disease, mitral regurgitation, pericardial effusion, heart failure

HYPERTENSION URGENCY IN SEVERE ABDOMINAL PAIN ET CAUSA HEPATIC HYDATID CYST: THE ETIOLOGY HAS BEEN REVEALED

R.K. Ratri¹, C. Saputra², Y.S. Sugi³, R.S. Sihombing³, W. Wiriadisurya³, J.R.L. Sulle⁴

General Practitioner of Mgr. Gabriel Manek, SVD Public Hospital of Atambua-East Nusa Tenggara¹
Cardiology and Vascular Medicine Department of Mgr. Gabriel Manek, SVD Public Hospital of Atambua-East
Nusa Tenggara²

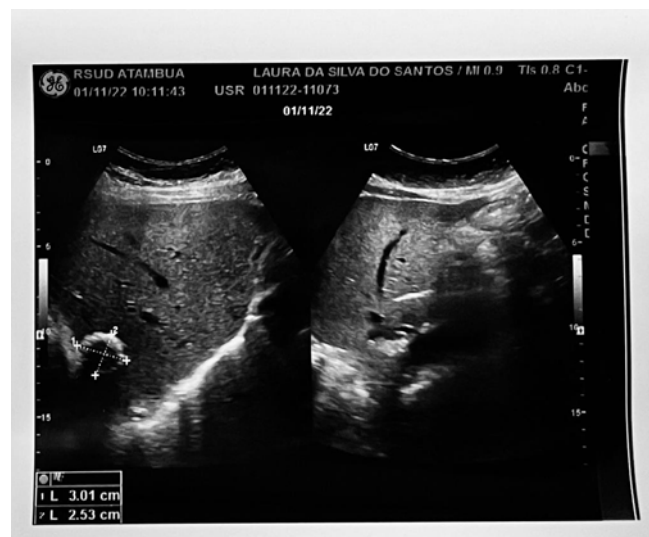Internal Medicine Department of Mgr. Gabriel Manek, SVD Public Hospital of Atambua-East Nusa Tenggara³
Radiology Department of Mgr. Gabriel Manek, SVD Public Hospital of Atambua-East Nusa Tenggara⁴

Background: Hepatic hydatid cyst is a cystic disease of the liver caused by the larva stage parasitic tapeworm of *Echinococcus granulosus* and *Echinococcus multilocularis*. The most common mode of transmission to humans is by accidental food that has been contaminated. Hydatid cyst can also cause hypertension due to external compression of renovascular. For the pharmacological treatment, Albendazole is a chosen drug for Hydatid cysts.

Case Illustration: A 54 years old female, was referred to the Emergency Department of the Public hospital of Atambua with experienced abdominal pain in the epigastric region. The patient also complained of pain all over the body, headache, and fever. The patient had a history of hypertension. In the physical examination, blood pressure 189/110 mmHg, axillary temperature was 37.9 Celsius degree, there is epigastric tenderness. Laboratory examination showed results of a normal neutrophil segment and an increased eosinophil segment, in the abdomen sonography found a Rim Calcification 3x2,5 cm in the right upper lobes hepar (hydatid cyst) (Figure). The patient was treated with low doses anti-hypertension and albendazole 800 mg twice a day the duration of treatment is 28 days for 3 cycles, with a break of 14 days without taking medication between cycles. The patient has shown immediate improvement. The patient was discharged after 3 days of hospitalization, hemodynamically stable, and with no complaints of abdominal pain.

Conclusion: In hypertension patients, we must search for etiology that may reverse progression of disease. In this patient, there is external compression of renovascular because of hepatic hydatid cyst.

Keywords: Hydatid cyst, Albendazole, Hypertension



Rim Calcification in hepar (hydatid cyst)

ACUTE RHEUMATIC FEVER INDUCED THYROID STORM IN PATIENT WITH RHEUMATIC HEART DISEASE: A RARE CASE FROM RI-RDTL CROSSBORDER

R.K. Ratri¹, C. Saputra², Y.S. Sugi³, R.S. Sihombing³, W. Wiriadisurya³, J.R.L. Sulle⁴

General Practitioner of Mgr. Gabriel Manek, SVD Public Hospital of Atambua-East Nusa Tenggara¹
Cardiology and Vascular Medicine Department of Mgr. Gabriel Manek, SVD Public Hospital of Atambua-East Nusa Tenggara²

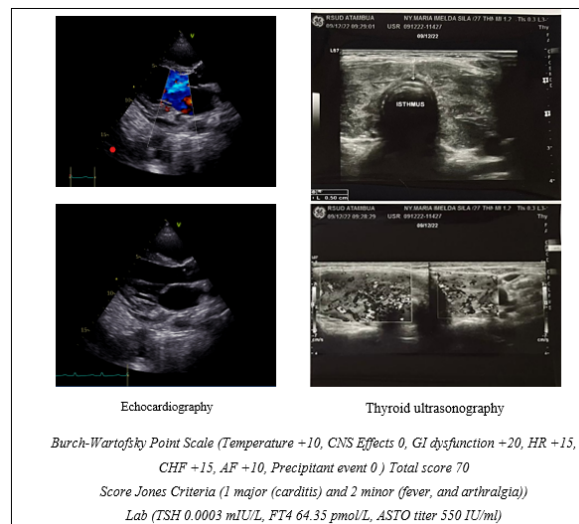
Internal Medicine Department of Mgr. Gabriel Manek, SVD Public Hospital of Atambua-East Nusa Tenggara³
Radiology Department of Mgr. Gabriel Manek, SVD Public Hospital of Atambua-East Nusa Tenggara⁴

Background: Thyroid storm is a life-threatening medical condition. This condition occurs in thyrotoxic patients and is manifested by the decompensation of multiple organs such as congestive heart failure and respiratory failure. In this case, thyroid storm induced by a recent streptococcal infection (acute rheumatic fever).

Case Illustration: A 27 years old female, was referred to the Emergency Department of the Public hospital of Atambua with experienced fever, palpitation, and multiple joint pains. In the physical examination heart rate 128 times/min, respiratory rate 32 times/min, axillary temperature was 38 Celsius degree increased of JVP (5+4 mmHg), a heart murmur at the apex cordis, rales at the base of both lungs, and bilateral lower extremity edema. 12 lead ECG showed irregular narrow complex QRS indicating AF RVR and chest x-ray showed cardiomegaly with early sign of pulmonary edema. Patient was treated with optimal HF medication. For further diagnosis, on the second-day echocardiography result found mitral and aortic regurgitation with normal LV and RV systolic function. Thyroid ultrasonography study showed grave's disease appearance, laboratory examination ASTO titer 550 IU/ml, and Hyperthyroid condition with Burch-Wartofsky point scale of 70. From this working diagnosed become acute rheumatic fever induced thyroid storm. The patient has been treated with Thyroid storm protocol along with acute rheumatic fever therapy. The patient has shown improvement, hemodynamically stable, convert into NSR, relieved symptom and discharged after 8 days of hospitalization.

Conclusion: Early recognition of thyroid storm and acute rheumatic fever with clinical diagnosis criteria may lead into proper diagnosis and management.

Keywords: Acute Rheumatic Fever, Thyroid Storm



Clinical Diagnosis and Sonography Exam

A Case Report of Premature Ventricular Complex in Long-Standing Hypertension Patient At Limited Primary Health Care : High or Low Level of Risk Feature ?

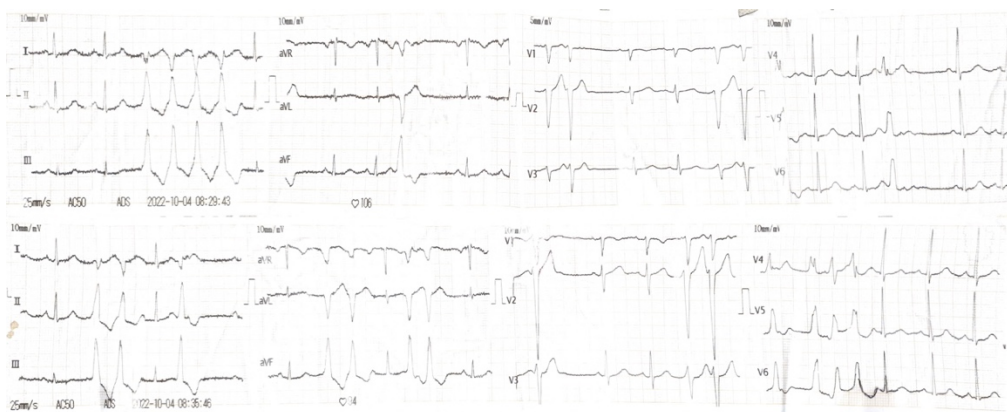
S.D.T. Sitanggang¹, C.J. Purba²
RSUD Pakuhaji, Tangerang¹
Puri Hijau Hospital, Medan²

Background : Premature ventricular complex (PVC) is a premature beat that occur spontaneously arising from the ventricle region. PVCs are common in general population with the prevalence between 1 – 4 % and are precipitated by many factors, including hypertension. PVCs could induce weakening of heart muscle if it is oftenly occur and untreated. This case report aims to present deeper insight about risk feature of PVC in patient with long-standing hypertension at limited primary health care.

Case Illustration : A 52 years old female came to primary health care (PHC) with a chief complain of palpitation especially at rest accompanied by shortness of breath (SOB) and headache since 2 days ago. 11 months earlier, she had came to PHC with similar symptoms and was suspected with hypertensive heart disease. Amlodipine was prescribed but she didn't take it routinely. No chest pain or syncope were reported. She had no family history of sudden cardiac death or other heart diseases. Blood pressure was 149/73 mmHg with 110 bpm heart rate. No gallop (S3), murmur, peripheral edema or rales were found. Electrocardiography (ECG) shows normo-axis sinus rhythm with multiple PVCs as shown in figure 1. She was considered to have high risk feature of PVCs that may potentially cause cardiomyopathy then she was given captopril, bisoprolol and referred to cardiologist.

Conclusion : Chronic hypertension in our patient may causes structural heart disease, particularly left ventricular hypertrophy, and induces PVCs. PVCs that arise due to structural heart disease have high risk feature/malignant if following features occurs in ECG such as polymorphic form or multifocal origin, consecutive run/salvoes, short coupling interval (< 300 ms), >5 PVCs/bpm and most importantly, symptomatic to the patient. While PVCs are common, it is vital to recognize its high-risk features and should warrant further cardiac evaluation if encountered.

Keywords: premature ventricular complex, hypertension, arrhythmia, risk level, electrocardiogram



premature ventricular complex, hypertension, arrhythmia, risk level, electrocardiogram



A Case Report Post Peripartum Cardiomyopathy: Interrelation Marriage, Pivotal Factor for PPCM

A.M.A. Kastiran¹
RS wahidin sudirohusodo¹

Background: Peripartum cardiomyopathy (PPCM) is a dilated cardiomyopathy defined as systolic cardiac heart failure in the last month of pregnancy or within five months of delivery. PPCM, which affects thousands of women each year in the US, was first described in the 1800s, but its etiology is still unclear. PPCM has many risk factors. One of them happened in this case, interrelation Marriage. Its diagnosis is often delayed because its symptoms closely resemble those within the normal spectrum of pregnancy and the postpartum period. When PPCM is misdiagnosed or its diagnosis is delayed, the consequences for patients are deadly: The disorder carries a high mortality rate

Case Illustration: A 23 - year old woman came to the emergency unit with dyspneu. There is a history of giving birth about 3 months ago. Physical examination shows a regular heart rhythm accompanied by rhonchi sounds in the basal aspect of the lung. The M - mode analysis of ECG showed left ventricular systolic ejection function is decreased (26 %) while the right ventricle is normal. In the hospital, the patient got treated with diuretics, aldosterone antagonists, angiotensin II receptor blockers, and fluid management. The patient gave a good response to the therapy regimen.

Conclusion: The early clinical manifestations of PPCM are difficult to recognize. In the majority of patients, 78% of symptoms are found at 4 months after delivery, and only 9% of patients show symptoms in the last month of pregnancy. Clinical symptoms include signs of pulmonary edema, orthopnea, atypical chest pain, abdominal discomfort, and paroxysmal nocturnal dyspnea. In general, PPCM-related mortality ranges from less than 2% to 50%. This case teaches us about the unfavourable effects of Interrelation Marriage as a risk factor for PPCM.

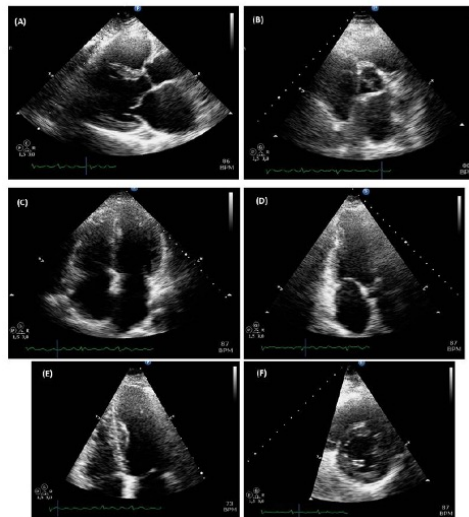
Keywords: Dyspneu, Delivery, Interrelation Marriage, Peripartum cardiomyopathy

A Heart of Stone: Extensive Myocardial Calcification in End-Stage Renal Disease (ESRD)

I. Pratiwi¹, R. Ariani¹
University of Indonesia¹

Background: Dysregulation of mineral metabolism with a high calcium load resulting poor calcium phosphorus balance in ESRD. Majority, cardiac conduction block presented as complication in ESRD **Case Illustration:** A 52-year-old woman came to emergency department with worsening fatigue and frequent syncope episode since last two weeks. She had end-stage renal disease (ESRD) and undergone routine hemodialysis for more than 4 years. On physical examination, the patient looked moderately ill with hypertension (194/70 mmHg), bradycardia (50 bpm). Rales were heard in lower third of pulmonary bases, Ascites with liver enlargement 2 cm below arcus costa. Electrocardiography showed total atrioventricular (AV) block. Chest X-ray showed cardiac enlargement, prominent aortic segment, normal pulmonary segment, flatten cardiac waist, downward apex, and pulmonary infiltrates in both lungs. Anemia and impaired renal function were detected through blood test. Echocardiography on parasternal long axis (PLAX) showed patchy calcification at septal right ventricle (RV) and left atrium (LA) wall (Fig. 1A). Parasternal short axis (PSAX) view shown heavily calcified of aortic cusps from basal annulus, moderate mitral stenosis (MS), moderate aortic stenosis (AS) with good left ventricle (LV) systolic function with left ventricle ejection fraction (LVEF) of 59% (Fig. 1B). Four chambers (Fig. 1C), three chambers (Fig. 1D), and two chambers (Fig. 1E) views had not detected other cardiac structural anomalies. Right ventricle (RV) contractility was good (TAPSE 17 mm). Apical parasternal short axis (PSAX) view showed diffuse mitral annular calcification (Fig. 1F). Echocardiography results were strongly suggestive of metastatic myocardial calcification. Temporary pacemaker (TPM) implantation for total AV block was successful then given angiotensin receptor blocker (ARB), and diuretics. Patient was successfully discharged after clinical improvement. **Conclusion:** Echocardiography is the first-line method that permit rapid and non-invasive detection of unrecognized or even unsuspected rare case of extensive myocardial calcification in ESRD.

Keywords: End-Stage Renal Disease, Myocardial Calcification



How Do We Overcome ISR: Role of Intravascular Imaging

M.R. Priatama¹, D. Firman²

Universitas Indonesia, National Cardiovascular Center Harapan Kita¹

Division of Invasive Diagnostic and Interventional Cardiology, National Cardiovascular Center Harapan Kita²

Background:

Percutaneous coronary intervention (PCI) with drug-eluting stents (DES) is a treatment for patients with poor prognosis CAD because of the extensive myocardium. Bare-metal stent (BMS) and drug eluting stents (DES) are the two types of widely used stents for PCI. DES demonstrated superiority to BMS, it has a lower rate (4-8%) of restenosis than BMS implantation (20-30%). However, the prevalence of in-stent restenosis (ISR) remains relatively unchanged, encompassing about 10% of percutaneous coronary interventions despite of its evolution and iteration. In contrast to BMS, DES have a lower risk of early restenosis, but require a prolonged dual antiplatelet therapy, potentially leading to thrombus formation in case of early discontinuation.

Case Illustration:

A male, 66 years went to NCCHK with chest discomfort, burning sensation, fatigue, and dyspnea on exertion. The patient has a slight limitation of physical activity, and these symptoms were amplified on moderate physical activity. In past medical history, he experienced anterior STEMI on May 2022 and was diagnosed with CAD ISR after CAG from Pasar Rebo general hospital. However, because the ISR and the first stent wasn't available and too small, therefore he was referred to NCCHK. He underwent PCI twice on 2017. Due to history of ISR LAD (60-70% at mid-proximal LAD) and multiple stents, therefore the patient underwent POBA with DEB-OCT.

Conclusion :

In-stent restenosis can be characterized by a significant reduction in the luminal diameter in the stent segment after successful PCI. The incidence of ISR has been reduced with the newer DES technology compared to the era of BMS and only 5-10% PCI procedures performed in clinical practice. The use of intravascular imaging can guide the management of ISR through several stages. It can help optimize the stent placement procedure by predicting and avoiding ISR.

Keywords: PCI, DES, OCT, ISR, DCB

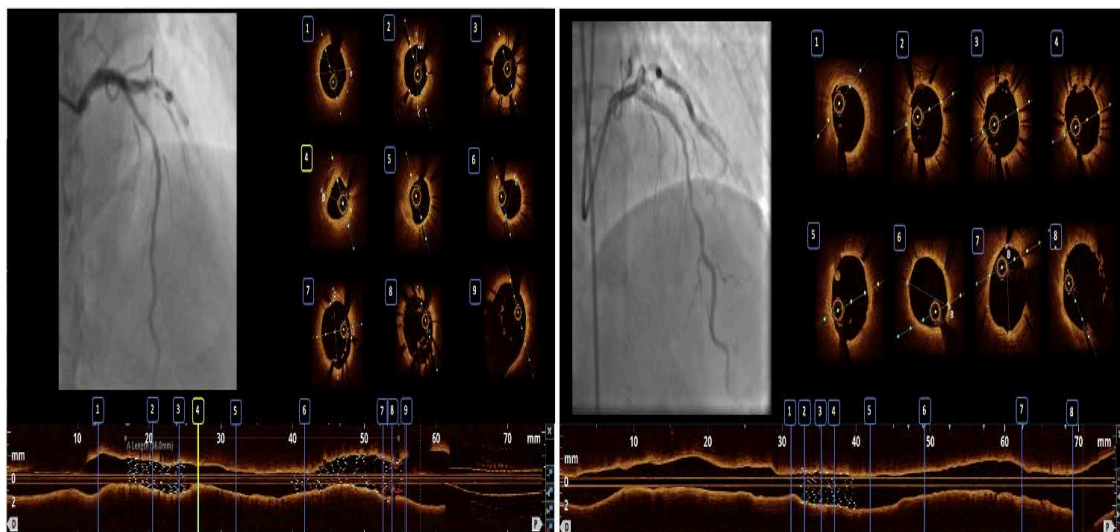



Figure 1. Pre Intervention OCT (Left Side) and Post POBA Intervention OCT (Right Side)



A Case Report of Leukostasis Presenting as ST-Elevation Myocardial Infarct: Proceed Reperfusion or Not?

K. Saleh¹, W.E. Putri¹, A.I. Taim¹
Cardiology and Vascular Medicine, FK UNHAS¹

Background: Leukostasis is a medical emergency caused by compromise of tissue perfusion secondary to hyperleukocytosis in acute myeloid leukemia. Typically it affects lungs and brain, with cardiac involvement being exceedingly rare. Acute myocardial infarction and acute myeloid leukemia are rarely reported as concomitant conditions. The management of ST-elevation myocardial infarction in patients who have AML is challenging due to the increased risk of bleeding.

Case illustration: A 66-year-old man with suspected acute myeloid leukemia presented with typical anginal chest pain. ECG revealed ST elevation in lead V2-V6. Troponin I peaked at 3548.4 ng/L. Echocardiogram showed mildly abnormal LV systolic function with ejection fraction of 45% (TEICH) due to segmental akinesia and hypokinesia. Blood work was notable for white blood cell count of $242.700 \times 10^3/\mu\text{L}$ and Hemoglobin of 8.7 gr/dl. Peripheral blood analysis result was suspected acute myeloid leukemia.

Conclusion: The management of ST-elevation myocardial infarction in patients who have acute myeloid leukemia is challenging: the leukemia-related thrombocytopenia, platelet dysfunction, and systemic coagulopathy increase the risk of bleeding, and the administration of thrombolytic agents can be fatal. It is important to note that prognosis for patients with concomitant conditions of acute myeloid leukemia and acute myocardial infarction is worse than that of either condition. There is no management guideline regarding these conditions and invasive reperfusion strategy could be done when there is no absolute contraindication.

Keywords: leukostasis, hyperleukocytosis, acute myeloid leukemia, ST-elevation myocardial infarct

Ablation of Idiopathic Trigeminy Premature Ventricle Complex using Zero-Fluoroscopy Approach: A Case Report

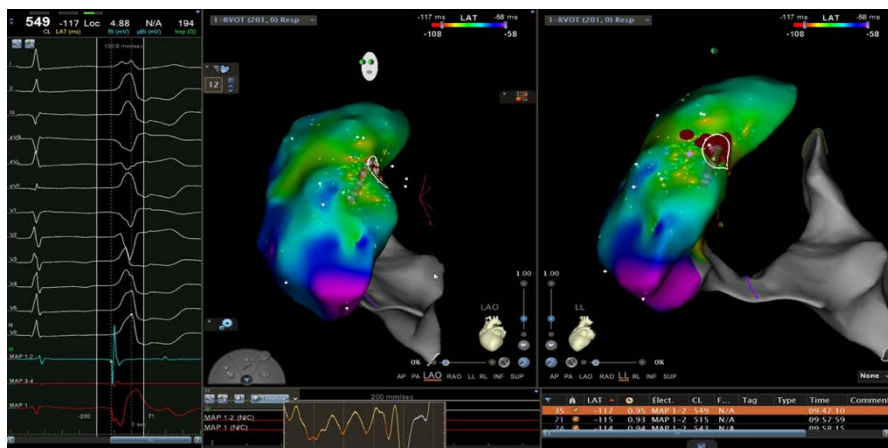
A.F. Chandranegara¹, M.R. P. Adri¹
General Regional Hospital of Pasar Rebo¹

Background: In the last few decades, awareness of the risks associated with radiation to patients and medical staff has increased significantly. It is also a topic of discussion in the cardiology world because fluoroscopy, which also used radiation, is widely used to orient the position of catheters in the heart during Radiofrequency Catheter Ablation. The existence of a 3-dimensional navigation system make the management of arrhythmias less complicated. 3D Electroanatomical Mapping (EAM) can minimize (near-zero fluoroscopy) or eliminate radiation dose (zero-fluoroscopy). Here we present our first zero-fluoroscopy case in a breast tumor patient with trigeminy PVC.


Case Illustration: 52 years old woman was consulted by the surgical department for a planned operation for a breast tumor but found trigeminy PVC on electrocardiogram (ECG). In recent years, patients often complain of palpitations. There are no remarkable results in physical examination, laboratory investigation, and echocardiography. The patient was planned for ablation using 3D EAM. A breast tumor suspected of cancer provoked the electrophysiologist to adopt a zero-fluoroscopy approach. The 3D EAM system will create geometric contours from the IVC until Right Ventricle Outflow Tract (RVOT). Surface ECG showed bigeminy PVC with positive morphology in I and aVL, positive in II, III, aVF, and LBBB pattern QRS notch in V3-V4. The earliest activation was found in the posteroseptal region with -117ms LAT and -37ms EA. Multiple RFA for 60-120 seconds was done at that location. After 30 minutes of observation, no PVCs were found.

Conclusion: Three-Dimensional PVC ablation with zero-fluoroscopy was successfully performed. RFCA with zero-fluoroscopy approach is becoming the treatment of choice in patients with malignancy.

Keywords: Ablation, Premature Ventricular Complex, Zero-Fluoroscopy, 3D-Electroanatomical Mapping



3D EAM showed the earliest activation in posteroseptal with LAT -117 ms and EA -37ms



CARDIOGENIC SHOCK AS A RESULT OF RARE ANTIPSYCHOTICS-INDUCED DILATED CARDIOMYOPATHY IN YOUNG PATIENT

S. Nurfitri¹, H. Isnaniyah¹, T. Rahayu¹
Pasar Rebo Regional General Hospital, Jakarta, Indonesia¹

Background: Schizophrenia patients often take antipsychotics for considerably long periods to prevent psychotic episodes and maintain stabilized condition. Albeit drug-induced cardiomyopathy is a rare side effect of antipsychotics, particularly Clozapine and Quetiapine, it is a life-threatening event that is usually overlooked and underestimated. Given its insidious nature, patients tend to come in a peril state with obscure presentation, making it harder to draw correlation between cardiac episode and antipsychotic consumption, hence correct diagnosis and treatment will be challenging.

Case Illustration: A 17-year-old male presented with dyspnea and cough since 4 days before admission. He had been taking Clozapine, Risperidone, Quetiapine, THP, and Lithium Carbonate for a year as schizophrenia treatment. No history of diabetes, lung, and cardiac disease is known. Physical examination revealed hypotension, RR = 28x/min, SpO₂ = 99%, rhonchi on auscultation, cold extremities, and CRT >2 seconds. ECG showed sinus tachycardia without signs of new ischemic changes or pericardial pathologies. USCOM examination revealed that CI (1.8 l/min/m²) and SVI (15 ml/m²) are low, while SVRI (3419 d·s·cm⁻⁵/m²) is high. CXR showed marked cardiomegaly. Echocardiogram revealed dilatation of all heart chambers, reduced EF (17%), mild tricuspid, and moderate mitral regurgitations. Patient underwent fluid resuscitation. He was treated with dobutamine then transferred to PICU where he received HF medications consisting of furosemide, spironolactone, captopril, and digoxin. After consultation with a psychiatrist, the antipsychotics were stopped and the patient achieved hemodynamic stability with better clinical outcome. Given the absence of other clear etiologies, antipsychotic consumption is the leading cause of cardiomyopathy which progressed into cardiogenic shock.

Conclusion: Drug-induced cardiomyopathy is a rare yet dangerous side effect of antipsychotics. Early recognition should be considered in patients who take antipsychotics to prevent deterioration and provide correct treatment.

Keywords: cardiogenic shock, antipsychotics-induced cardiomyopathy, schizophrenia

Bradycardia-Induced VT in Degenerative Sinus Node dysfunction: High Risk Feature of Life Threatening VT in Bradycardia

R. Hendiperdana¹, R.Y.I. Putri¹, S. Laksono²

Department of Cardiology and Vascular Medicine, Faculty of Medicine, Universitas Indonesia, National Cardiovascular Center Harapan Kita¹

Department of Cardiology and Vascular Medicine, Diagram Heart Hospital²

Background

Bradycardia has been linked with inverse relationship with QT duration and repolarization time, since it can induce polymorphic VT in severe bradyarrhythmia. The potentially life threatening arrhythmia explained by the possibility of the rhythm to degenerate into ventricular fibrillation.

Case Illustration

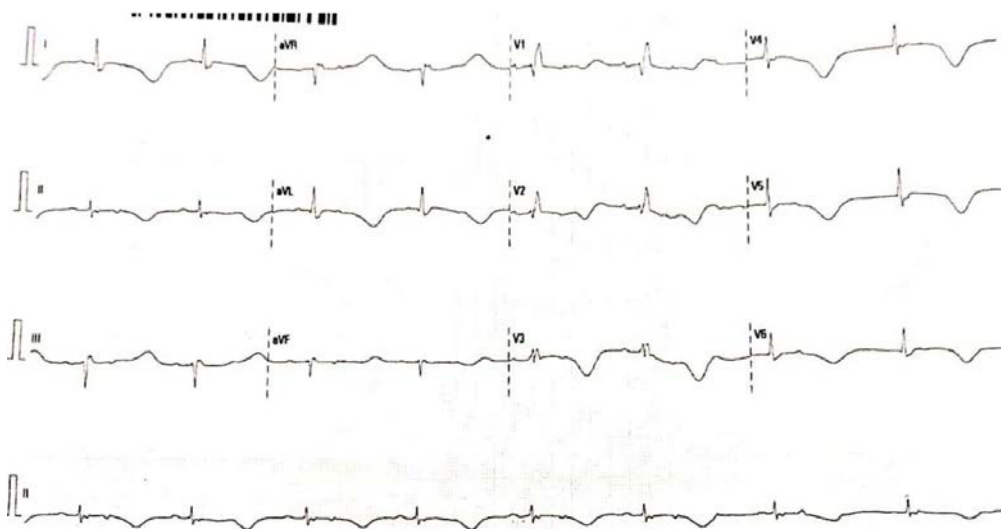
A 76-year-old woman was admitted with recurrent fainting and post cardiac arrest resuscitation. She was somnolence with bradycardia (40 bpm) and recurrent non-sustained VT on electrocardiograph (ECG) monitor. Her blood pressure was 140/90 mmHg with 99 % peripheral oxygen saturation.


Her initial ECG record showed sinus bradycardia with intermittent junctional rhythm with a rate of 48 bpm, deep T wave inversion at precordial lead with prolonged QT interval (QT 720 ms, QTc 670 ms, Tpeak-Tend (Tpe) 200 ms, Tpe/QT ratio 0.27. Her blood chemistry was normal. Bedside echocardiogram showed no structural heart disease. While being monitored, she developed recurrent unstable sustained polymorphic VT episode which required DC cardioversion for termination. Dopamine infusion starting on 5 micron/kg/min was given and initiation of transcutaneous pacing (TCP) for stabilization. The patient was very dependent to TCP, when the paddle was removed, the bradycardia ensue and VT was inevitable induced. Temporary transvenous cardiac pacemaker (TPM) was finally implanted in this patient for stabilization.

Conclusion

Severe bradycardia can lead to QT prolongation and subsequent life threatening polymorphic VT. Several clinical predictors such as older age and female have higher risk of TdP occurrence. Profile of QT interval and T wave morphology like QT interval, QTc interval, Tpeak-Tend duration, and complex T wave morphology could predict high occurrence of polymorphic VT as seen in our patient's ECG presentation. Pacing at higher rate in emergency setting could become a lifesaving since it can stabilize the repolarization from perturbation.

Keywords: bradycardia, Ventricular tachycardia, Long-QT





Kounis Syndrome Secondary To Drug-Induced Hypersensitivity: Report Of A Devastating Case From Referral Hospital In Central Borneo

A.R. Sudirman¹, Y. Galenta¹
RSUD dr. Doris Sylvanus Provinsi Kalimantan Tengah¹

BACKGROUND

The concurrence of ACS and hypersensitivity reactions is defined as Kounis syndrome. It is often misdiagnosed and lead to inappropriate treatment with high subsequent mortality rate. The mechanism behind is related with excessive catecholamine production alongside with inflammatory-cytokine-released triggered by allergic reaction. Hereby we present the case of drug-hypersensitivity induced Kounis syndrome in our hospital.

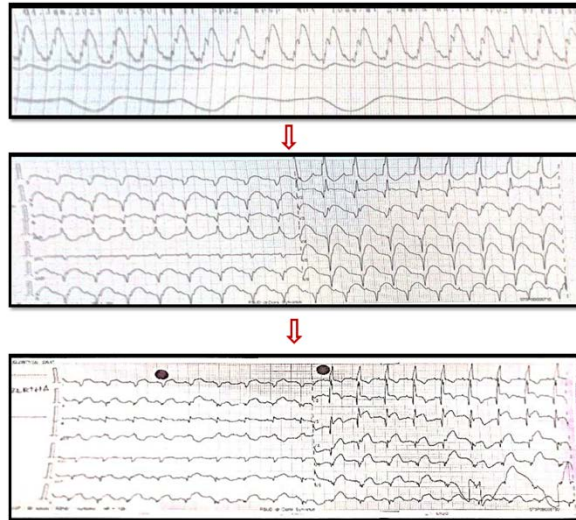
CASE ILLUSTRATION

A 65-year-old woman presented with shortness-of-breath and chest tightness. Her past medical history was remarkable for asthma with multiple readmission and drugs hypersensitivity. There is no cardiac-related history. Upon arrival, her saturation-92%, respiratory rate-35x/min and unable to speak. She was in respiratory distress with expiratory-wheezing on both lungs. Laboratory studies was unremarkable and ECG showing OMI. The patient was suggestive for acute severe asthma exacerbation. Methylprednisolone and ventolin nebulizer were administered. Suddenly, her respiratory distress worsen, with loss of consciousness, RR-50x/min, saturation-60%-on-NRM, and BP-70/40. She was developed into anaphylactic shock. IM-epinephrine was administered. Her consciousness improved with saturation-98% and RR-30x/min. Unfortunately, she was developed into ventricular tachycardia and her BP-exceeds-220/110. This condition returned spontaneously without any drug administration. Later on, she developed typical chest pain similar with myocardial ischemia symptom. Her ECG evaluation showing ST elevation in anterior segment with RBBB. Her troponin level slightly increased from <0.01 to 0.6. The patient was suggestive for ACS in the settings of mast-cell and platelet activation from anaphylactic reaction. Dual-antiplatelet and anticoagulant were administered. We cannot perform primary-PCI because refusal of any further medical-intervention. Her condition worsen following days. Her echocardiography-evaluation demonstrated global hypokinetic with-EF-40%. On the-seventh-day, she was passed away due to heart failure and cardiac arrest.

CONCLUSION

Kounis syndrome should be suspected whenever patient presents with features of ACS and allergic symptoms simultaneously. The challenges lies in the fact that each treatment of associated entities may worsen the other injury.

Keywords: Kounis syndrome, Acute coronary syndrome, Drug Hypersensitivity



ECG Changes after anaphylactic reaction and ventricular tachycardia. The changes demonstrated ST elevation in anterior segment with RBBB.

Acute Coronary Syndrome In Severe Aortic Stenosis and Aortic Regurgitation Patient: A Case Report

G.F. Mantong¹, Y. Iskandar¹
Elim Rantepao Hospital, North Toraja¹

Background: Angina pectoris is one of common symptoms in patient with aortic stenosis (AS) and aortic regurgitation (AR). To diagnose acute coronary syndrome (ACS) in patient with severe AS and AR is challenging especially in peripheral hospital. In this case will discuss ACS in patient with severe AS and AR, focus on diagnosis.

Case illustration: A 69 y.o women came with shortness of breath felt since 4 hours ago when she rested. She also felt chest pain that more severe and intens than before, radiated to neck and accompanied with diaphoresis. Patient had history of severe degenerative AS and AR, sometimes she felt chest pain and shortness of breath during activity but relieve with rest. We found to-and-fro murmur and was best heard at right upper sternal border. Electrocardiography showed left bundle branch block (LBBB) pattern. Based on brief examination in emergency room, patient was diagnosed as ACS with troponin level was known markedly elevated later on. Vital signs were unstable during the first day but later controlled during the rest six days of hospitalization.

Conclusion:

ACS diagnosis in severe AS and AR group is challenging because it is often presenting with similar symptom likes angina pectoris. Proper history taking and physical examination is the main point for the diagnosis of ACS especially in peripheral hospital.

Keywords: Acute Coronary Syndrome, Angina Pectoris, Aortic Stenosis, Aortic Regurgitation

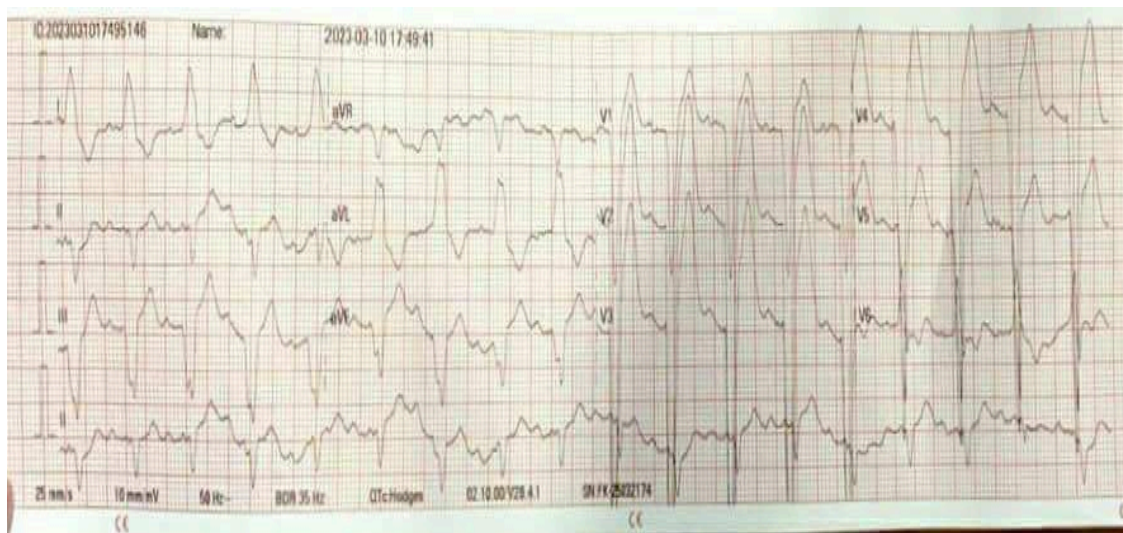



Figure 1. ECG



Successful Balloon Transcatheter Pulmonary Valvotomy in Children with Severe Valvular Pulmonary Stenosis : A Case Series

D.G. Nugroho¹, W. Mubarak¹, A. Priyatno²

Cardiovascular Department, Faculty of Medicine Diponegoro University, Dr Kariadi Hospital, Semarang¹
Pediatric Department, Faculty of Medicine Diponegoro University, Dr Kariadi Hospital, Semarang²

Background: Pulmonary stenosis (PS) is typically benign yet progressive in pediatric patients. Severe PS may result in outflow obstruction that progresses over a period of years despite body growth. An excellent prognosis can be achieved by appropriate intervention. Balloon Transcatheter Pulmonary Valvotomy (BTPV) has replaced surgery and become preferred mode of treatment.

Case Illustration: Patients of age 2, 5, and 11 years old showed aggressive progression of PS with variety of symptoms with similar malnourished state. The auscultation of 4/6 ejection systolic murmur, best heard in second and third left intercostal space were found in all three patients. The electrocardiography showed right axis deviation and right ventricular hypertrophy. They had dome-shaped valves morphology with pressure gradient (PG) between 78-136 mmHg by echocardiography. Patent foramen ovale were found during catheterization. BTPVs were performed using THYSAK mini and Nucleus with size of 1,4 times larger than their pulmonary annulus diameter. The insertion of balloon were quite challenging. It had to be precisely placed in order to fully dilate the stenotic valve. The 50% PG reduction of RV-PA were found in all cases with periprocedural transient bradycardia. Seven days evaluation showed improved symptoms, better food intake with PG as low as 30 mmHg.

Conclusion : Our successful cases suggest that BTPV is a promising and safe intervention for children with severe valvular PS. Reversal shunt of interatrial defect can be prevented by reducing the right chamber pressures.

Keywords: Balloon Transcatheter Pulmonary Valvotomy, Valvular Pulmonal Stenosis, Patent Foramen Ovale

Does His Bundle Pacing Have a Good Outcome? A Case of 66 Years Old Man, Presenting With Recurrent Syncope

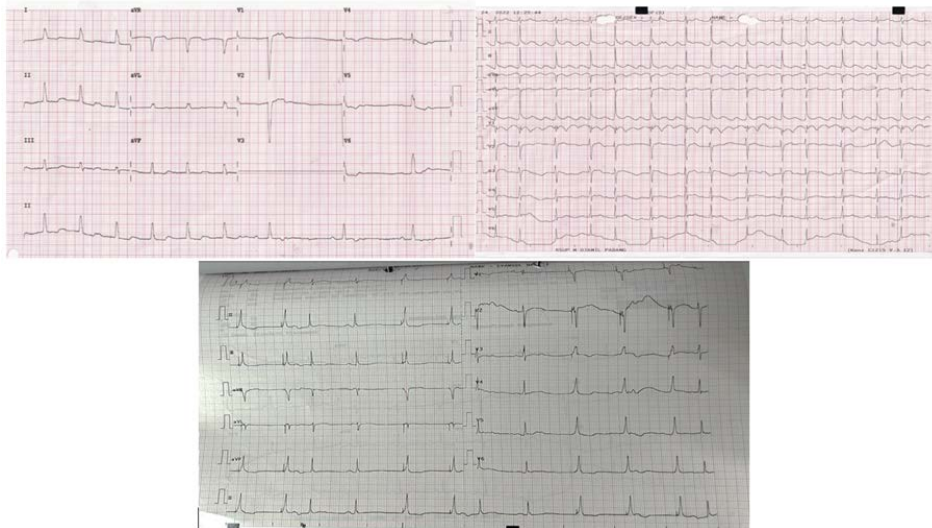
D. Surya¹, F. Yuliani¹, H.E. Rasyid¹, C.K. Krevani¹
Dr. M. Djamil General Hospital¹

Background: Syncope is a state of losing consciousness because of cerebral hypoperfusion that usually happens in rapid onset, short duration, and is followed by spontaneous recovery. Approximately 3-5% of emergency cases were presented as syncope. One of the causes was sinus node dysfunction (SND) which mostly needs to be treated with permanent pacing. His bundle pacing (HBP) starts to be widely used as a modality pacing in patients with SND because it was expected to have fewer clinical complications. We present a case of a 66-year-old man with sinus node dysfunction who was successfully treated with permanent HBP.

Case Illustration: A 66-year-old male presented with dizziness to the emergency room. The patient had a blackout and collapsed for 3 seconds but was still aware of the surrounding. The patient also reported having blackouts, dizziness, and syncope about 10 times in the last 2 years. The patient was admitted to the hospital 1 month ago because of having a syncope for 2 seconds. Electrocardiography showed a period of sinus paused and we noticed sinus node dysfunction (SND) with atrial flutter. The patient was put on Holter monitor for a couple of days and we used HBP as the permanent pacemaker for the patient.

Conclusion: Sinus node dysfunction (SND) with bradyarrhythmia was one of the indications for placing a pacemaker in this patient. We chose HBP as it was suggested to be able to prevent cardiomyopathy and reduced the length of stay in the hospital if compared to other pacing.

Keywords: his bundle pacing (HBP), recurrent syncope, sinus node dysfunction (SND), atrial flutter



ECG from the first day of admission (above) and ECG after His Bundle Pacing placement (below)

A RARE CASE OF PAINLESS TYPE A AORTIC DISSECTION PRESENTING AS ACUTE ISCHEMIC STROKE

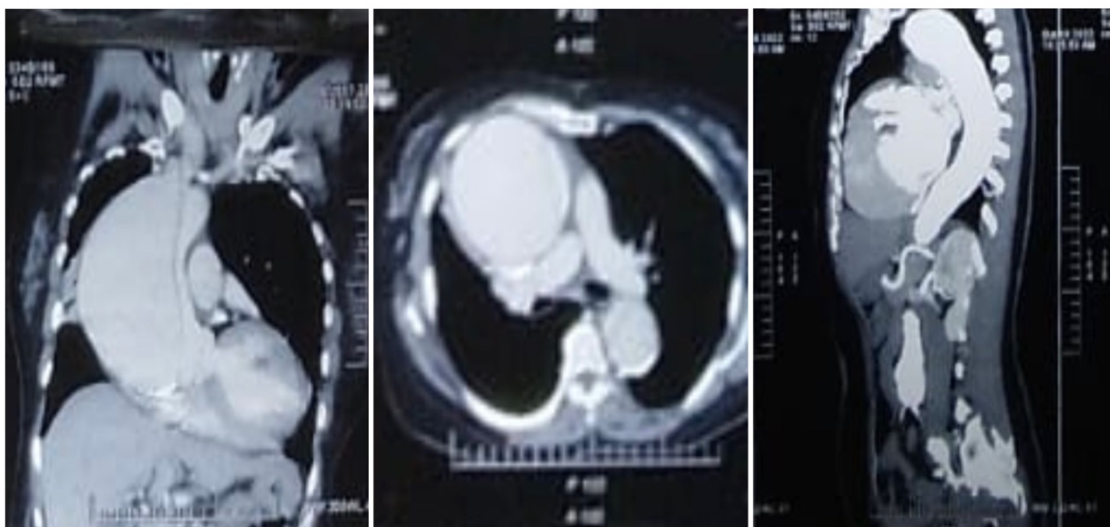
M.I. Muzakky¹, S.G.V. Hayon¹, M.B.S. Ilham², A.A. Kesumaningputri³, D. Hudiana⁴
General Practitioner, Dr. Sitanala Central Hospital, Tangerang, Indonesia¹
Internship Doctor, Bhayangkara Hospital, Denpasar, Indonesia²
Department of Cardiology, Dr. Sitanala Central Hospital, Tangerang, Indonesia³
Department of Neurology, Dr. Sitanala Central Hospital, Tangerang, Indonesia⁴

Background: Stanford type A aortic dissection (AD) with ischemic stroke is a rare condition, accounting for approximately 1.7% of all acute stroke cases. Painless AD is typically identified through incidental findings on a chest x-ray or the presence of related symptoms and complications. Diagnosing painless AD in patients presenting as stroke can be challenging and potentially misdiagnosed.

Case Illustration: A 68-year-old woman presented with a sudden onset of left-sided weakness without chest or back pain. Her past medical history revealed hypertension for five years with no history of acute stroke. On arrival, her blood pressure was 101/65 mmHg, heart rate was 55 beats per minute, respiration rate was 26 times per minute, and oxygen saturation was 90%. The patient was admitted to the hospital 2 hours after onset and was immediately triaged to the code stroke response protocol. Neurological examination disclosed left hemiparesis (left motor strength 1/5) with a positive Babinski reflex. The National Institutes of Health Stroke Scale (NIHSS) score was 14. A diastolic murmur was heard on the third intercostal space along the left sternal border. A non-contrast head computed tomography (CT) showed no evidence of hemorrhagic stroke, while the chest X-ray indicated mediastinal enlargement and cardiomegaly. Further evaluation by thoracic and abdominal CT angiograms showed a tear in the ascending part of the aorta. The patient was diagnosed with stroke infarction, type A aortic dissection, and severe aortic regurgitation. However, the patient refused to undergo a surgical procedure and was admitted to the intensive care unit for conservative management integrated with neurology, which included regulation of blood pressure and heart rate.

Conclusion: AD with atypical symptoms requires timely recognition and immediate surgical repair. However, conservative management is associated with a high incidence of early mortality.

Keywords: type A aortic dissection, stroke infarction



Computed tomography angio of coronal and axial view-showing dissection in ascending aorta.

Rare Incidental Finding of Anomalous Left Circumflex Artery Arising from Right Sinus Valsalva in Acute Coronary Syndrome Patient

F.A. Nurullah¹, N.R. Utantyo¹
Embung Fatimah Regional Public Hospital¹

Background

Anomalous left circumflex coronary artery (ALCx), as part of coronary artery anomalies (CAA), is a rare phenomenon. We present an unusual case of an anomalous aortic origin of LCx in a middle-aged patient who presented with acute coronary syndrome (ACS).

Case Illustration

A 44-year-old male patient, without any history of cardiovascular disease, was referred to our hospital due to anterior wall STEMI Killip IV – cardiogenic shock 28 hours of onset after failed fibrinolytic. He remained chest pain on admission and was hemodynamically unstable. Rescue PCI was performed, on angiography we found acute total occlusion in mid LAD after D1 with high thrombus burden, LCX was not visualized on LCA angiography. RCA was dominant without stenosis or thrombus, LCX was seen originating from common ostia with RCA in RSV (type II), retro-aortic in course, traversing between the aortic root and left atrium, to its distribution territory. Based on ECG and clinical appearance, LAD had a culprit lesion which we decided to stent. Angiography evaluation revealed TIMI 2-3 flow with residual thrombus. During the operation, patient had an episode of pulseless VT/VF but ROSC achieved after CPR. He was intubated and mechanically ventilated. Optimal medical therapy including heparinization continued. On the next day the patient had worsening of symptoms and was diagnosed to have uncompensated respiratory alkalosis. We optimized critical care management and his hemodynamic status gradually improved on the 5th day of hospitalization. He was discharged home with stable condition after 12 days hospitalization and came to routine check-up without significant symptoms.

Conclusion

Although type II ALCx was reported as benign variant, under several circumstances it posed to malignant risks. In the setting of ACS patient, recognizing this anomaly is crucial since failure to angiographically describe CAA can cause inappropriate clinical decisions and complications during invasive procedure.

Keywords: Anomalous left circumflex coronary artery (ALCx), Percutaneous Coronary Intervention, ST segment elevation myocardial infarction (STEMI), Coronary artery anomalies (CAA), Congenital Heart Defect

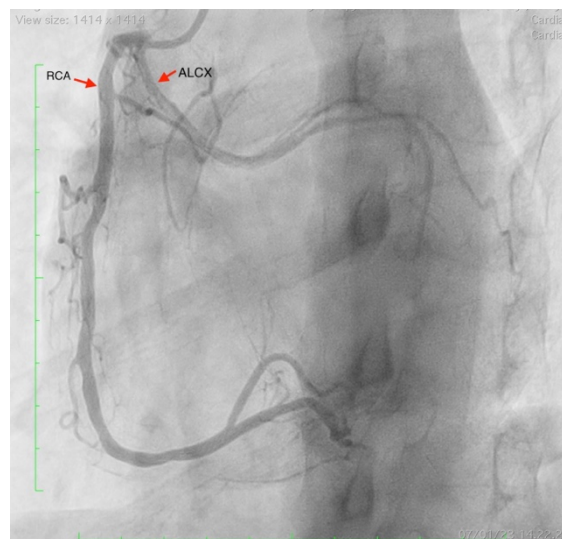


Figure 1: RCA angiography showed LCX was seen originating from common ostia with RCA in RSV (type II)

Failure of Electrical Cardioversion to Convert Hemodynamic Unstable Supraventricular Tachycardia in 1st Trimester Pregnancy, What Should We Do? : a Case Report

A. Leisyah¹, B. Setiawan¹
RSUD Sayang Kabupaten Cianjur¹

Background

Compared to the non-pregnant population, cardiac arrhythmias are rare in pregnancy, with an incidence of about 1.2 per 1000. Supraventricular Tachycardia (SVT) is the most common form of arrhythmia during pregnancy, although often benign in nature, can be concerning. The management of SVT in pregnancy, varies slightly based on the trimester of pregnancy.

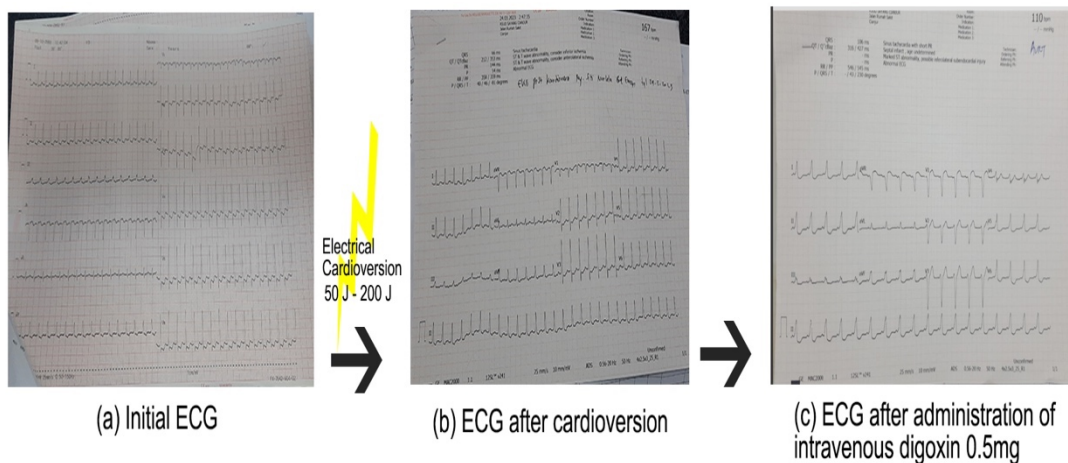
Case Illustration


A 29 years-old G4P3 female at approximately 12 weeks gestational age presented after feeling palpitations and shortness of breath, several hours before admitted to emergency department. She denied chest pain and syncope. She denied any past medical history and taking any medications. Initial heart rate was 198bpm and blood pressure was 80/50 mmHg. Chest X ray showed normal cardiac size. ECG showed SVT with short RP (>90ms). Laboratory examination showed mild hypokalemia (3.03mEq/L) and mild hypocalcemia (1.05mEq/L). Electrical cardioversion was done from 50 joule to 200 joule but there was no effect. In our hospital, adenosine, intravenous beta blocker, intravenous verapamil were unavailable, also inability to do cardiac ablation. So the only choice was intravenous digoxin 0,5mg. After 2 dose digoxin given, heart rate started to slowing down (110bpm) and converted to sinus rhythm with delta wave (WPW pattern). After 2 days observation at ICU, heart rate was stable at 70-90bpm. This patient was discharged because of financial problem and planned for echocardiography examination at outward clinic.

Conclusion

Lack of choice (availability and safety) of anti arrhythmia drug and failure of electrical cardioversion was quite challenging for this case. All antiarrhythmic drugs cross the placenta, but when necessary, medical treatment should be used. Electrical cardioversion is safe during pregnancy, and catheter ablation can be performed in selected patients, preferably with zero-fluoroscopy technique. A multidisciplinary approach is crucial to balance maternal cardiac, obstetric and fetal considerations.

Keywords: SVT, Pregnancy, WPW, Arrhythmia





Paroxysmal Atrial Fibrillation in a COVID-19 Patient : A Case Report from Rural Area

R. Ainunnahqi¹, A.N. Famila²

¹General Practitioner at Islamic Hospital Purwokerto, Indonesia

²Department of Cardiology and Vascular Medicine, Banyumas Regional Hospital, Indonesia

Background

Coronavirus Disease 2019 (COVID-19) has been infecting people around the world caused by Severe Acute Respiratory Syndrome Coronavirus 2 (SARS-CoV-2). COVID-19 generally presents with symptoms of fever, cough, and shortness of breath. Cardiovascular problems have been reported in some COVID-19 patients, including arrhythmia. Atrial fibrillation is one type of it.

Case Illustration

A 44-year-old woman came to the Emergency Department (ED) complaining of palpitation. She denied any shortness of breath, cough, or fever on the day of admission and had no history of cardiovascular disease. The patient's condition is *compos mentis*, with a pulse rate of 144 bpm. The physical examination revealed an irregular heart rhythm without a murmur. An electrocardiogram (ECG) examination in the ED showed atrial fibrillation. The patient's thorax X-ray showed bronchitis. COVID-19 rapid antigen test showed a positive result, so the patient was planned for COVID-19 PCR swab in the isolation room. Three days later, the PCR swab showed a positive result. Laboratory examination showed a total leukocyte count of 7030/ μ L, neutrophil-lymphocyte ratio (NLR) of 0.73, and elevated D-dimer of 2200 ng/ml. The patient was treated with ceftriaxone, bisoprolol, azithromycin, n-acetylcysteine, favipiravir, and fondaparinux. ECG examination was done every two days. The patient underwent a PCR swab evaluation on the seventh day with negative results. Thorax X-ray evaluation showed no bronchitis compared to the previous. ECG showed a sinus rhythm with a frequency of 66 bpm. Other workups were not carried out due to limited facilities. The patient had no complaints and was discharged from the hospital without any complications.

Conclusion

Atrial fibrillation can occur in COVID-19 patients. Several factors, including tissue injury, hypoxia, age, and systemic infection, probably contribute. However, clear pathomechanism of this condition needs further exploration.

Keywords: Atrial Fibrillation, COVID-19, Rural Area

High Risk Percutaneous Coronary Intervention and Comprehensive Management in Life-Threatening Latecomer ST-Elevation Myocardial Infarction Complicated by Cardiogenic Shock in Remote Area

F.A. Nurullah¹, N.R. Utantyo¹
Embung Fatimah Regional Public Hospital¹

BACKGROUND

Delayed presentation or latecomer of ST-elevation myocardial infarction (STEMI) and complicated by cardiogenic shock (CS-STEMI) is a challenging scenario that commonly encountered in developing countries which one in three patients does not survive. We present a successful comprehensive management in latecomer CS-STEMI patient in the setting of remote area.

CASE ILLUSTRATION

A 42 year-old woman with a typical chest pain since 4 days prior admission was referred to our hospital after being hospitalized in two hospitals. From first hospital, she was discharged with undiagnosed ACS. In second hospitalization, she was treated as ACS patient by a non-cardiologist then was referred to our hospital. At our ED, she was diagnosed as late onset extensive anterior STEMI KILLIP IV-cardiogenic shock, type-2 diabetes mellitus with severe uncompensated metabolic acidosis, chronic kidney disease and secondary hepatic injury. Echocardiography showed reduced LV contractility (LVEF of 37%) and hypokinetic anterior wall. Her condition quickly deteriorated as she had episodes of pulseless VT/VF terminated by successful CPR and DC shock. She was intubated, mechanically ventilated and transferred to other PCI-capable hospital due to administration issue. Although as a late onset STEMI with unstable hemodynamic status, high risk primary PCI was performed. Coronary angiography showed acute total occlusion of proximal LAD. Successful PPCI to LAD was performed with TIMI 3 flow result, hemodynamic status improved. She also underwent haemodialysis as her kidney function worsened due to hypoperfusion state and contrast induced nephropathy. Patient was discharged in stable condition after 22 days hospitalization.

CONCLUSION

“Time is muscle”, chances of recovery decrease with every passing minute, but timely reperfusion is challenging in remote area due to resource constraints, delayed patient presentation and system delays which associated with more complicated case, high-cost management and poorer outcome. Major integrated improvement is crucial to reduce mortality and morbidity in STEMI patients.

Keywords: Acute coronary Syndrome, ST-Elevation Myocardial Infarction, Cardiogenic Shock, Percutaneous Coronary Intervention, Hemodialysis

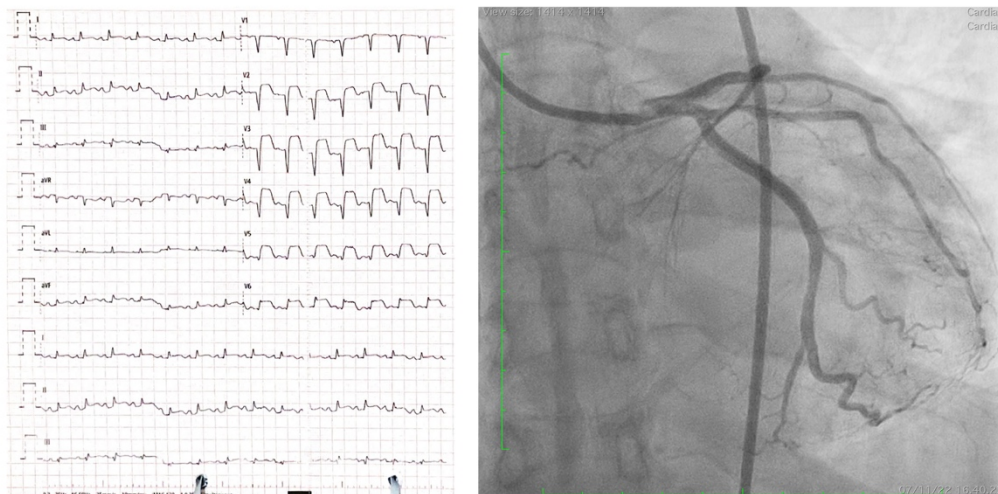


Figure 1: ECG showed ST elevation in lead II, III, aVF, V2-V6 and coronary angiography showed acute total occlusion of proximal left coronary artery (LAD)

Total Atrioventricular Block in Postpartum

A.S. Maulana¹, A. Candra², D. Ariyanti¹, K.W. Putri³
RSD Dr Soebandi Jember¹
Faculty of Medicine Universitas Jember²
Faculty of Medicine Airlangga University³

Background: Total atrioventricular block (TAVB) in postpartum is a rare case. Cases are few and management is not yet standardized. The aim of this study was to investigate the risk factors for TAVB in postpartum.

Case illustration: A 23-year-old P2A1 of 37 weeks gestation presented with frequent fainting since 5 months ago. She had never any medical examination before. At presentation, her heart rate was 44 x/minute, and her blood pressure was 147/76 mmHg. A 12-lead electrocardiogram (ECG) revealed a total AV block. The serum potassium level was 2.6 mmol/L, and the chloride level was 113 mmol/L. Chest X-ray showed cardiomegaly. A temporary pacemaker (TPM) was implanted. A transthoracic echocardiogram (TTE) was performed, which showed a suspicion atrial septal defect (ASD). After 5 days of TPM, her intrinsic heart rate was still below 50 bpm and was not returned to a normal sinus rhythm. A reversible cause, such as hypokalemia, has been resolved. Transesophageal Echocardiography (TEE) is performed to confirm the size and location of the ASD. However, TEE revealed interatrial septum was intact. A permanent implant pacemaker (PPM) was recommended.

Conclusion

Early detection of risk factors and treatment of reversible causes of total AV block in postpartum women are needed to treat total AV block successfully.

Keywords: Total atrioventricular block, pacemaker, postpartum

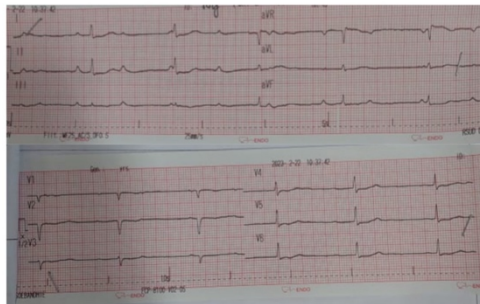


Figure 1. ECG showed a total atrioventricular block

When Learning ECG Turns Into A Nightmare: A Rare Case Report Study of PVCs

J. Budiono¹, P.P.D. Yamin², Haikal², V. Pratama², M.I.A. Nugraha³

Faculty of Medicine and Health Science, Atma Jaya Catholic University, Jakarta, Indonesia.¹

Department of Cardiology, Gatot Soebroto Central Army Hospital, Jakarta, Indonesia.²

Faculty of Medicine, Universitas Pembangunan Nasional Veteran Jakarta, Indonesia.³

Background: Premature ventricular contractions (PVCs) are triggered from ventricular myocardium in variety of circumstances and have been identified in broad-spectrum populations in which the vast majority of these patients may experience no symptoms. Frequent PVCs are associated with reversible cardiomyopathy and sudden cardiac death. However, research regarding post covid-19 infection and PVCs as a complication is still limited.

Case illustration: A 22-year-old man, a medical student, accidentally found PVCs during his ECG course in cardiology clinical rotation. He was asymptomatic, had no personal history of syncope, did not take any medication, and had no family history of sudden cardiac death. Results of his physical examination were normal, and this was the first time he underwent ECG in which PVCs have been recognized (figure 1). History of covid-19 infection with mild symptoms, 3 months before, was considered may be related to this condition. The patient was suggested to undergo some laboratory tests, transthoracic echocardiogram, 24-h ECG Holter, and cardiac MRI. All laboratory tests were within normal limits, but his echocardiogram and MRI showed reduced left ventricle contractility function. His Holter revealed many couplets, triplets PVCs, and some run ventricular tachycardias. Initial empirically guided medication with beta-blocker and other foundational therapy for LV dysfunction have been given. Radiofrequency ablation of the PVCs could be an excellent therapeutic option if there is no improvement in the patient's follow-up ECG with medication only.

Conclusion: This unique case report should prompt the performance of multicenter studies exploring the prevalence of PVCs in subjects with apparently asymptomatic and normal hearts, especially those with history of covid-19 infection.

Keywords: Premature Ventricular Contractions, Post covid-19 infection, Electrocardiogram

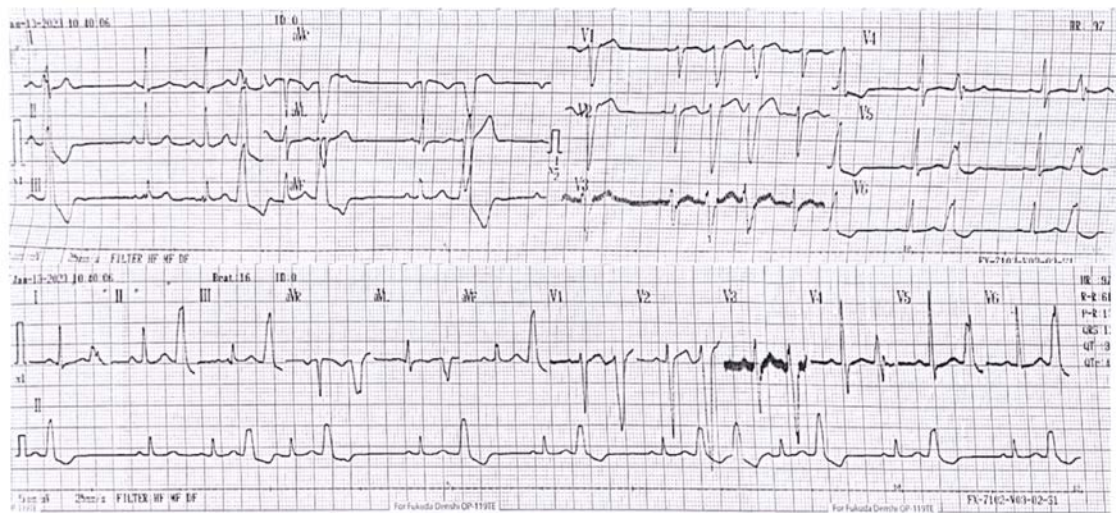


Figure 1. Patient's ECG shows couplets PVCs and trigeminy PVCs

Early Surgery In Complicated Infective Endocarditis: To Accelerate Is To Be Appropriate

A.M. Pardede¹, T.M. Haykal¹
RS Jantung Jakarta¹

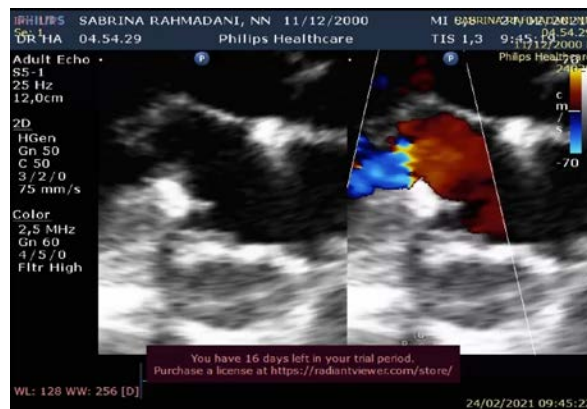Background :

Infective endocarditis (IE) is associated with a high risk of mortality and morbidity.^{1,2} Surgery has been the treatment of choice for IE because of severe complications. The optimal timing of the surgery has been unclear.^{3,4} In particular conditions early surgery brings certain benefits, so to avoid further deterioration yet performing surgery during the active phase of IE carries significant risk.⁴ Identification, risk stratification and early consultation with cardiac surgeon is capital to determine the best therapeutic approach.³

Case Illustration: A 20-years-old female was admitted to emergency room with complaints of breathlessness, tachypnea, palpitation, heaviness in chest at night, and dyspnoea on exertion, had undergone an appendectomy in other hospital with one month history of prolonged fever. Physical examination revealed a regular heart rate with systolic murmur sound heard on the apex. An electrocardiography (ECG) was sinus rhythm, heart rate 115x/minutes, bigeminy premature ventricular contraction (PVC). A blood examination revealed anaemia, leucocytosis, thrombocytosis, electrolyte imbalance. A transthoracic echocardiography (TTE) dilatation of left atrial and ventricle, an eccentric hypertrophic left ventricle, severe mitral regurgitation with possible vegetation on anterior and posterior mitral leaflet. Patient was diagnosed with Infective Endocarditis (IE), severe Mitral Regurgitation accompanied with acute heart failure, treated to IE protocol for 2 weeks with good response. The patient was decided to get early surgery to mitral valve repair. The result was remarkable, with subsided symptoms of heart failure and mild residual MR.

Conclusion: Infective Endocarditis along with complications need appropriate treatment plan, The decision to perform early surgery to this patient resulting favorable end, opening possibility to do it in regards of capitalizing improvement of patient's condition, shortening length of stay and cutting costs over scalable risk that present in this patient.

Keywords: INFECTIVE ENDOCARDITIS, EARLY SURGERY



Pict 1. Echocardiography After Surgery



**Acute Recurrent Purulent Pericarditis with Impending Cardiac Tamponade during Pandemic Situation.
A role of Intrapericardial Fibrinolysis Therapy: A Case Report**

B.B. Dharmadjati¹, M.D. Pratama¹, M.R. Amadis¹, A.F.D. Raharja¹, M. Ramadhan¹, D.R. Firmanda¹, M.S.
Tiyantara¹


Department of Cardiology and Vascular Medicine, Airlangga University, Surabaya, Indonesia.¹

Background: Purulent pericarditis (PP) is a localized pericardial space infection characterized by gross pus in the pericardium or microscopic purulence. PP is relatively uncommon but a potentially life-threatening disease. Fibrin formation in the first week is the key to the progression of PP to constrictive pericarditis and also cardiac tamponade with increased mortality and morbidity. Intrapericardial fibrinolysis is a promising therapy that can reduce the mortality risk and complications of PP.

Case Illustration: A 36-year-old man was referred for the second time to our emergency department. The patient complained of dyspnea and chest palpitations for a week which had worsened in the last two days. Physical examination reveals hypotension, tachycardia, pulsus paradoxus, and elevated jugular venous pressure (JVP) as signs of cardiac tamponade. The electrocardiogram shows low voltage in the limb leads and alternating electricity. Chest X-ray shows Erlenmeyer's sign. Echocardiography showed massive pericardial effusion on the right and left laterals, apex, and base with right atrial collapse. Covid-19 rapid antigen swab was positive, but with negative PCR swab. Urgent pericardiocentesis was performed. Staphylococcus aureus was found as the causative etiology. NSAID, colchicine, and intravenous antibiotic was given, and we administered 500,000 units of Streptokinase, diluted in 20-50 mL normal saline through the catheter into the pericardial cavity via pigtail. This regimen was performed 3 times at 8 hours intervals with good response and improved clinical status, the catheter was removed when when the drain was <25 to 50 ml/24 hours, and echocardiography showed minimal or no effusion. The patient was discharged after 14 days.

Conclusion: PP is a potentially life-threatening disease with high mortality and may cause serious complications. In this case, we performed comprehensive management of PP with the addition intrapericardial fibrinolysis that leads to good outcomes for the patient.

Keywords: Purulent pericarditis, intrapericardial fibrinolysis, cardiac tamponade



Dilated Cardiomyopathy with decreased eGFR as cause of cerebrovascular accident

M.R.A. Putra¹, D.N. Oetomo², M. Maulydia³

*Faculty of Medicine, Airlangga University, Surabaya, East Java, Indonesia*¹


Dr. Soetomo General Academic Hospital, Surabaya, East Java, Indonesia^{2,3}

Background : Dilated Cardiomyopathy (DCM) is characterized with left ventricle (LV) enlarged and poorly contractile with ischemic cardiomyopathy being the most common type. Usually it will lead to a heart failure or abnormal heart rhythm, but sometimes it could lead to cerebrovascular accident (CVA) such as cerebral infarction and cerebral haemorrhage. Decreased eGFR in patient with DCM, increase the risk of CVA to happen.

Case Illustration : A 40 years old woman was referred to our emergency room with sudden loss of consciousness after 2 weeks of hospitalization from another hospital. The patient presented with foot and hand edema, shortness of breath, desaturation, and fatigue, with history of type II diabetes and controlled hypertension. ECG shows no sign of LVH but found anterolateral ischemia (Inverted T in V1-V4), and CXR shows sign of cardiomegaly with CTR around 60% with pneumonia aspiration. POCUS echo were done to assess the heart. The result showed declined of LV systolic function with ejection fraction 36%, LV remodelling (LVDMi 79.7, RWT 0.500), and minimum mitral regurgitation. CT scan showed cerebral infarction and minimum haemorrhage. Laboratory findings showed elevated serum creatinine and elevated ureum with eGFR 9ml/min/1.73m². We also found elevated infection marker, hypoalbuminemia and hyperglycemia. Patient with DCM were susceptible to thrombosis due to blood clots (caused by systolic dysfunction and low eGFR) was associated with intracranial arterial stenosis that lead to CVA. Management and treatment of DCM are in concordance with the guideline of heart failure with treating any identifiable and reversible underlying causes. ACE-I and diuretic were already given to the patient, but due to worsening desaturation, the patient went into the intensive care unit. After couple days of treatment, the patient passed away because septic shock.

Conclusion : DCM could lead to CVA besides heart failure or abnormal heart rhythm, especially patient with decreased eGFR.

Keywords: Dilated Cardiomyopathy (DCM), Cerebrovascular Accident (CVA), Heart Failure, decreased eGFR, cerebral infarction



Zero Contrast Transcatheter VSD Closure using Double Disk Device: A Case Series from East Java Network Hospital

I.M. Suprayoga¹, H. Martini¹, V.P. Yogibuana¹

Department of Cardiology and Vascular Medicine Faculty of Medicine Universitas Brawijaya¹

Background:

Ventricular Septal Defect (VSD) is the most common of congenital heart malformation, accounting for 20-30% of all congenital heart defect. This non cyanotic defect is marked by a ventricular shunt and affects blood flow to the lung. Almost all types of VSD can be corrected. Surgery was once the first choice for VSD repair, but nowadays, catheterization closure is preferred because it is less invasive. In recent years, transcatheter device closure for ventricular VSD guided by transesophageal echocardiography (TEE) and fluoroscopy without contrast has been used in our center. These report aims to describe the effectiveness of zero contrast transcatheter VSD closure using double disk device in network hospital.


Case Illustration:

There were 7 cases of perimembranous VSD performed zero contrast transcatheter closure using double disk device in Dr Saiful Anwar General Hospital Malang during October 2022 till March 2023. Zero contrast transcatheter procedure was performed with Lifetech Konar-MF Occluder using double disk device with retrograde transarterial approach under TEE and fluoroscopy guided. The patient's mean age was 19.7 ± 9.7 years old (3-34 years old), and mean body weight was 49.5 ± 18.4 kg (13-70kg). The median VSD size from TEE was 6.1 mm (4-9 mm), and the mean size of the occlusion device was 8.1 ± 2.3 mm (5-12 mm). The mean fluoroscopy times was 28.8 ± 18.4 minutes (2-53 minutes). Using double disk device in variant size range 7/5 in 1 patient, 9/7 in 2 patients, 10/8 in 2 patients, 12/10 in 1 patient and 14/12 in 1 patient. Device displacement, pericardial effusions, arrhythmia, residual shunt or new valve regurgitation were not observed during and after procedure. The patients showed significant clinical improvement after the procedure.

Conclusion:

This serial cases has shown that zero contrast transcatheter VSD closure using double disk device is feasible, safe and effective to be done in network hospital with good result.

Keywords: VSD, transcatheter closure, zero contrast, outcome



A Case of Arrhythmogenic cardiomyopathy (ACM): the role of Cardiac MRI

A.B. Maharjito*

*Cardiology resident of The Department of Cardiology And Vascular Medicine
Faculty of Medicine Universitas Indonesia

ABSTRACT

Background :

Arrhythmogenic cardiomyopathy (ACM) affects the right ventricle (RV), the left ventricle (LV), or both, whose hallmark pathologic feature is the fibrofatty myocardial replacement that underlies the impairment of systolic ventricular function and predisposes to potentially lethal ventricular arrhythmias, regardless of the severity of pump failure. Recently, the interpretation of structural, functional, and tissue characterization by contrast-enhanced cardiac Magnetic Resonance Imaging (MRI) has become a crucial imaging tool for the diagnosis of ACM as a result of technological advancements and improved experience in this field. The objective of this case study is to demonstrate the role of cardiac MRI in the diagnosis phenotype of ACM

Case illustration :

A 66 year-old-woman experienced dyspnea on effort for 3 years. Despite normal coroangiography, the patient has a reduced left ventricular ejection fraction and multivocal PVC with non-sustained VT from holter examination. The patient underwent cardiac MRI that depict a reduced both RV and LV systolic function with dyskinesia in apical RV and hypokinesia basal-apicoseptal LV, no myocardial edema, microinflammation and fat infiltration at apex LV and RV. Padua criteria are criteria for diagnosis of the entire spectrum of phenotypic variants of ACM, which not only included RV morpho-functional abnormality but LV as well. Our present case here met the criteria. Our case also showed that there was a fat infiltration at apex RV and LV, although this finding was not the part of criteria for ACM.

Conclusion

Cardiac MRI is a crucial imaging tool for the diagnosis of ACM, especially in terms of ACM phenotype.

Keywords: arrhythmogenic cardiomyopathy Padua criteria, cardiac MRI

A Case report of ST Elevation Myocardial Infarction (STEMI) in Young Woman: Shifting the Paradigm

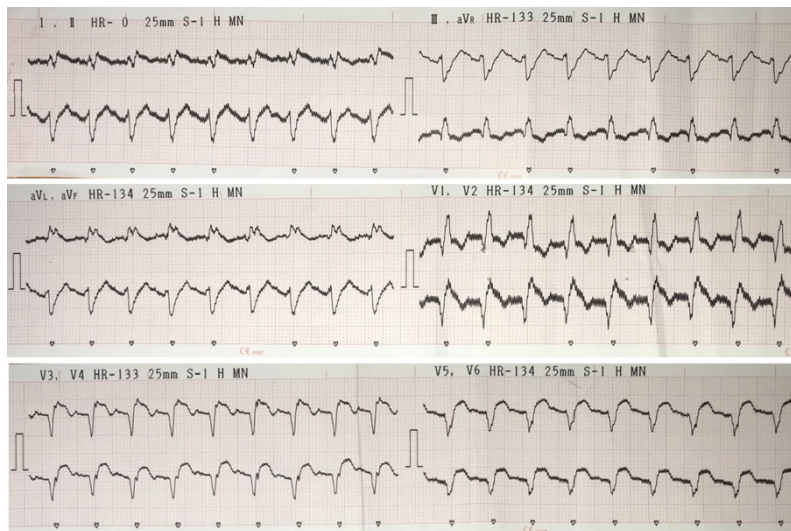
A. Agustyana¹, B.I. Maula², Z. Muin², M. Furqon¹
Abdul Wahab Sjahranie General Hospital¹
Abdul Rivai General Hospital²

Background: Although STEMI is more commonly associated with older adults and men, it can occur in younger women as well. Young patients presenting with STEMI are an important and challenging subset, especially in women. Cardiovascular disease in women tend to be missed diagnosed and untreated, causing greater mortality in addition to more comorbidities.

Case Illustration: A 29-years old woman with obesity (body mass index 48.4) presented in the emergency room with recurrent isolated epigastric pain for the past 3 days accompanied with dyspnea and atypical chest pain. No prior history of any life-threatening event such as cardiovascular event or syncope. An Electrocardiogram (ECG) showed an extensive anterior STEMI (elevation in V1-6, I and aVL leads). Laboratory examination showed an increase in troponins T, glucose level and LDL cholesterols in blood. There was a family history of type 2 diabetes mellitus and hypercholesterolemia. Echocardiogram demonstrated anteroseptal and anterolateral walls hypokinetic with decreased ejection fractions. After given initial treatment, patient was transferred to PCI-capable hospital to performed cardiac catheterization and total occlusion of proximal LAD was revealed. It was successfully treated with a balloon stent.

Conclusion: The suspicion for myocardial infarct (MI) in younger age should be increased especially for women with risk factors and careful examination should be performed to prevent misdiagnosis. Diabetes mellitus and obesity are common risk factors in women with young age. The necessity to improve of focused management and primary prevention in younger patients are much needed, especially women, was important due to worse outcome.

Keywords: STEMI, Young Age, Women, Total Occlusion



ECG examination during chest pain demonstrating elevation in extensive anterior/anterolateral

Transient Symptomatic Total Atrioventricular Block Complicating Acute Anterior Reinfarction

R. Hendiperdana¹, I. Firdaus¹

Department of Cardiology and Vascular Medicine, Faculty of Medicine, Universitas Indonesia, National Cardiovascular Center Harapan Kita¹

BACKGROUND

Total atrioventricular block (TAVB) is frequently become the conductive disturbance complication of acute reinfarction. Inferior MI has low long-term mortality and greater reversibility than anterior MI which has higher in-hospital and long-term mortality.

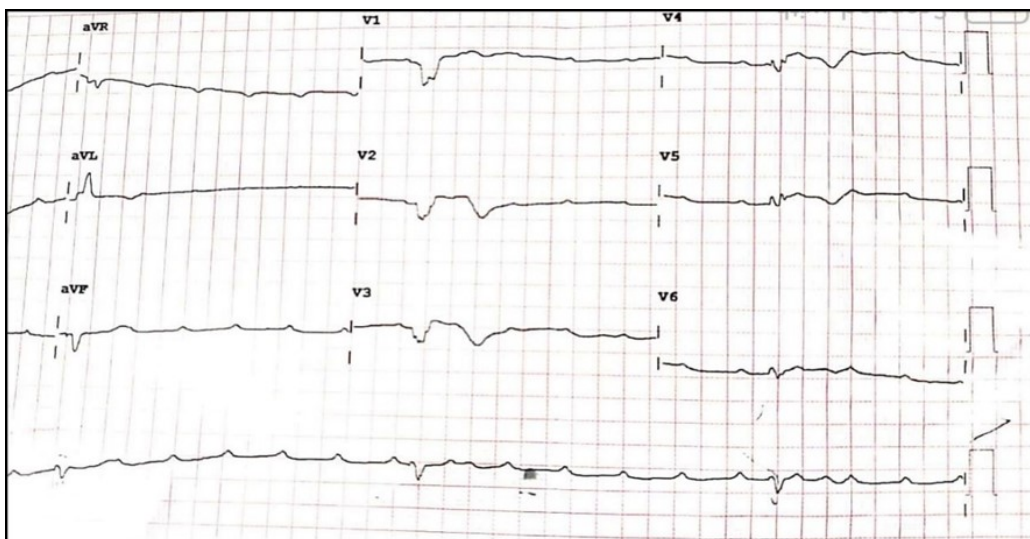
CASE ILLUSTRATION

44 old years man underwent PPCI stenting at proximal LAD of his acute anterior MI 2 days before presentation at the previous hospital. Patient had acute stent thrombosis then underwent urgent PCI and developed TAVB with idioventricular escape. In emergency department Cardiovascular Centre Harapan Kita, patient develop loss of consciousness with blood pressure 57/30 mmHg, heart rate 20 -30 bpm and TAVB rhythm. Laboratory showed increased serum lactate level 5.2. Patient was diagnosed with Total AV block caused by anterior MI. Patient was planned for emergency temporary pacemaker (TPM) implantation. After 24 hours close monitoring, the patient intrinsic rhythm resolved with spontaneous recovery. Patient was hemodynamically stable until discharge. Stent thrombosis of proximal stent of LAD will cause TAVB because of the source of the distal portion of the AV node is originating from septal branch of LAD. Cardiogenic shock could be a manifestation of TAVB with idioventricular escape. It is caused by extensive necrosis with higher in-hospital and long-term mortality, often culminated in permanent pacemaker. However, spontaneous recovery of TAVB into sinus rhythm take place. This could be caused by transient reversible ischemia of infra nodal region of AV node which supplied by septal perforator branch in anterior infarction.


CONCLUSION

This case reporting a TAVB case during the course of acute anterior reinfarction and developed spontaneous resolution to sinus rhythm. Mechanisms of spontaneous resolution of TAVB in the setting of acute MI is associated transient ischemia after occlusion of proximal LAD.

Keywords: total AV block, Bradycardia, Stent Thrombosis



ECG Presentation in Emergency Ward National Cardiovascular Centre Harapan Kita. The ECG showed Total AV Block with Wide Complex Escape Rhythm



Optimal Timing of Renal Replacement Therapy for favorable Outcome in Patients with Acute Kidney Injury (AKI) Following a Coronary Artery Bypass (CABG) Surgery: The Sooner, The Better?

B. Dewanggi¹, N.R. Muttaqin¹, N.A. Tafriend², D. Bima³

¹General Practitioner of Intensive Care Unit, Gatot Subroto Presidential Hospital, Jakarta, Indonesia

²Cardiologist, Gatot Subroto Presidential Hospital, Jakarta, Indonesia

³Anesthesiologist-Consultant of Intensive Care, Gatot Subroto Presidential Hospital, Jakarta, Indonesia

Background: Acute kidney injury (AKI), defined as a rapid deterioration of kidney function, is a major complication associated with cardiac surgery. Its incidence ranges from 8.9 to 42.5% and was related to poorer outcomes, ICU length of stay, and mortality, especially in severe AKI when renal replacement therapy was needed (RRT-AKI). Some scores such as Cleveland Score and AKICS score were developed to predict CSA-AKI (post-cardiac surgery AKI) and RRT-AKI so that early recognition and treatment can be done. Here we present a case of a post-CABG CSA-AKI patient which getting better after early initiation of continuous renal replacement therapy (CRRT).

Case illustration: a 44-year-old man with Coronary Arterial Disease following three vessels (CAD 3 VD), a history of CHF, COPD, LVEF 29%, and Diabetes Mellitus, underwent CABG with a total CPB time of 2 hours and 50 minutes. According to the AKICS Score (score=14~21.8% risk of AKI) and Cleveland Score (score=6~7.8 to 9.5% risk of dialysis), he was at risk of post-cardiac surgery AKI and RRT. So that, when twelve hours later, the creatinine level was increased 1.7-fold from baseline and he was oliguria which is unresponsive to the furosemide infusion, we decide to perform CRRT. The patient's condition improved and the diuresis was increased to 1.6 ml/kg/hour. On the 3rd-day post operations, he was stable enough to discharge from the intensive care unit.

Conclusion: Using scores to predict the patients who are at risk of CSA-AKI and RRT-AKI may improve prognosis and also help clinicians to decide the appropriate timing for initiating therapy to achieve a favourable outcome.

Keywords: acute kidney injury, Coronary artery bypass graft, continues renal replacement therapy

Pathophysiology of Mitral Annular Disjunction: A Case Report

I.W.P. Wisuda¹, N.M.A.W. Sari²

¹Cardiology Specialist Study Program, Faculty of Medicine Udayana University/Prof. Ngoerah Hospital, Denpasar, Indonesia

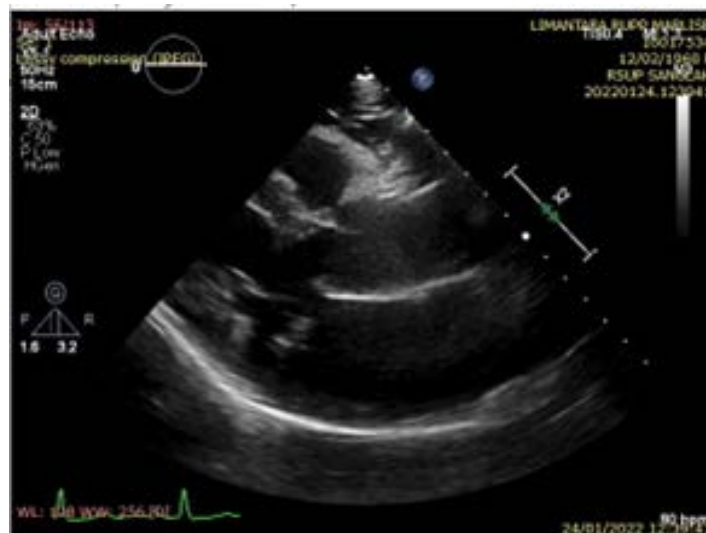²Department of Cardiology and Vascular Medicine, Prof. Ngoerah Hospital, Denpasar, Indonesia


Background: Mitral Annular Disjunction (MAD) is a structural abnormality defined as the separation of the junction of the mitral valve annulus-wall of the left atrium with the basal aspect of the posterolateral left ventricle. The incidence of MAD is estimated to be 51% in patients with myxomatous mitral valve, 32.6% in the context of MVP, and 25.9% in severe mitral valve regurgitation.

Case Illustration: A 61-year-old woman came to the cardiology clinic at Prof. Ngoerah Hospital with a referral from oncology clinic with a diagnosis of right and left breast cancer post right Modified Radical Mastectomy pro chemotherapy AC-T (Adriamycin Cyclophosphamide-Taxol). Physical examination, laboratory, and chest X-ray were within normal limits. Echocardiographic examination found dilated left atrium, LV eccentric hypertrophy, EF Biplane 63.4%, LV diastolic function intermediate, TAPSE 24 mm, global normokinetic, mild MR with mitral annular displacement in PLAX view, eRAP 8 mmHg. The patient was then diagnosed with mild MR with mitral annular displacement with a Cardiotoxicity Risk Score of 5 (high) with therapy ramipril 1x2.5 mg, carvedilol 2x3.125 mg and simvastatin 1x20 mg with echocardiographic evaluation in 3-6 months. Mitral annular contractility contributes significantly to mitral valve function. Shortening of the annular diameter during systole facilitates coaptation of the mitral valve leaflets. The presence of MAD impairs valve coaptation. MAD has implications for ventricular arrhythmias and sudden cardiac death. Mitral valve repair in severe mitral regurgitation through surgery in the form of sewing a ring to attach the leaflet to the ventricular myocardium. In this case, mild MR was obtained, so medical management was carried out.

Conclusion: The presence of MAD impairs valve coaptation, resulting in MR. Severe MR should be corrected by surgery, however milder cases can be managed conservatively.

Keywords: mitral annular disjunction, mitral valve prolapse, MAD management





A MALE 56 YEAR OLD WITH ACUTE STENT THROMBOSIS WHEN PERCUTANEOUS CORONARY INTERVENTION, WHAT ARE THE PREDICTORS?

M.S. Rohman¹, H.I. Millisani¹
RSUD dr. Saiful Anwar¹

Background

Stent thrombosis is the complete occlusion of a coronary arteries of previously implanted stent which unusual complication that occur in percutaneous coronary intervention (PCI), development of myocardial ischemia and poor prognosis for the patient. The etiology of acute stent thrombosis were multifactorials and early detection can reduce mortality rate.

Case Illustration

A male, 56 yo came to Rumah Sakit Saiful Anwar Malang with stable angina pectoris (Class III symptoms with medical therapy) planned for elective cardiac catheterization with routine medical treatment. During PCI, he complain the chest pain and from cineangiography evaluation showed no flow at the diagonal branch because of the acute thrombosis. Then got thrombosuction and got white thrombus. After PCI procedure he got fibrinolytic with streptokinase 1.5 million unit for 60 minutes. He transfered to CVCU to observation and discharge after 5 days.

Discussion

Stent thrombosis based on ARC criteria include based on gradation (definite, probable, and possible stent thrombosis), based on onset (early, late, and very late). Anticoagulant therapy during PCI procedure has been focus of several clinical trial related to occur complication during or after PCI, for example stent thrombosis. Based on previous study showed a similar degree of evidence of thrombolytic treatment compared with percutaneous angioplasty in the management of stent thrombosis from symptom onset to reperfusion was less than 2 hours

Conclusion

Stent thrombosis is a feared complication during and after primary PCI because it is associated with high mortality. The mechanisms by which ST arises are complex and multifactorial and must be early detection.

Keywords: Acute stent thrombosis, Percutaneous coronary intervention

Percutaneous Transluminal Angioplasty Utilizing Carbon Dioxide Contrast in Chronic Limb Threatening Ischemia patient with Renal Failure

S.M.A. Sabara¹, S. Adiarto¹

Department of Cardiology and Vascular Medicine, Faculty of Medicine Universitas Indonesia¹

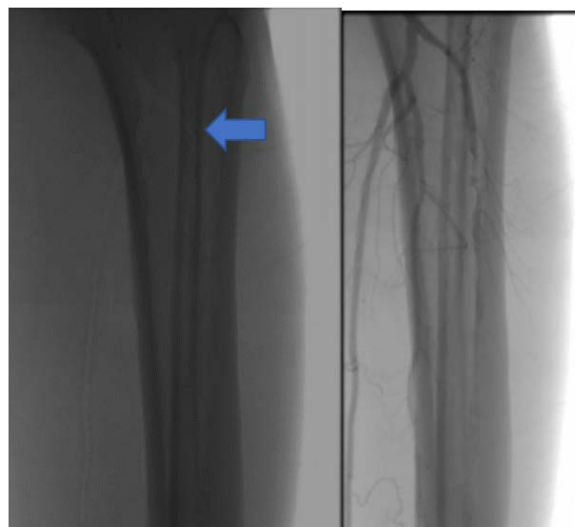Background: At the present times, more than 202 million patients suffered from peripheral arterial disease (PAD) worldwide. Chronic limb-threatening ischemia (CLTI) often need lower extremity amputation, and the aftermath could be worse. For the patient with CLTI and chronic renal disease (CKD) who need endovascular therapy, iodinated contrast could enhance the risk of contrast-induced nephropathy (CIN). In high-risk patients who were allergic to iodinated contrast material and for those with renal insufficiency Hawkins in the 1970s pioneered the intra-arterial application of carbon dioxide (CO₂) gas angiography to reduce the volume use of iodinated contrast.

Objective: This report is aimed to emphasize the usage of CO₂ contrast agent in PTA for the patients with renal dysfunction in order to prevent further loss of renal function


Case Illustration: An 80-years old man referred to National Cardiovascular Center Harapan Kita with the chief complaint of independent rest pain and non healing wound in his left forefinger, in accordance with the criteria CLTI. The duplex ultrasound showed total occlusion at left anterior tibialis artery. The patient then undergone percutaneous transluminal angioplasty (PTA) procedure using Carbon Dioxide (CO₂) contrast agent and using Plain Old Balloon Angioplasty (POBA) technique for revascularization. The flow to the distal of left anterior tibialis artery returned using only 30 ml of Iodinated contrast. The follow up of this patient showed no increase of serum creatinine level and eGFR

Conclusion: Endovascular therapy in patient with CLTI with high risk of operation is feasible to be performed in patient with CKD utilizing the carbon dioxide contrast agent in order to minimize the usage of iodinated contrast avoiding further loss of renal function. In this case report, the procedure has performed successfully without increase in serum creatinine and decrease of GFR.

Keywords: carbon dioxide contrast, limb ischemia, percutaneous transluminal angioplasty



Percutaneous Transluminal Angioplasty Procedures on this patient shows occlusion in anterior tibialis artery with Carbon Dioxide contrast (left) and Iodized contrast (right)



Improvement of Renal Function after Abdominal Decompression in Heart Failure Caused by Mitral Stenosis : The Renal Tamponade Hypothesis

D.Y. Kurniawan¹, I.P. Farissa¹, F. Tandri¹, M.F. Ahnaf¹, Y. Herry¹

Department of Cardiology and Vascular Medicine, Kariadi General Hospital, Semarang, Indonesia¹

Background

Renal dysfunction in heart failure has been linked to both reduced perfusion and increased congestion (central venous pressure). Renal tamponade hypothesis said that compression of renal structures caused by the limited space for expansion (increase interstitial space) contributes to worsening renal function in heart failure.

Case Illustration

A 20-year-old-man complained of shortness of breath, abdominal distention, and decrease urine output for 5 days before admission. His previous medical history was severe mitral stenosis (MVA by planimetri 0.6cm, Wilkins score 9) with preserved LV ejection fraction (63%) with reduced RV function (TAPSE 11 mm). Right sided pleural effusion, pulmonary edema, and cardiomegaly were noted by chest x-ray. Abdominal ultrasound showed normal sized kidney, massive ascites, and hepatomegaly accompanied with distention of hepatic vein. Reduced kidney function was noted (Ur 96 Cr 1,59 UO: 600-700 cc/day).

We managed him with optimal continuous infusion dose of furosemide and dobutamine in combination with spironolactone within first week yet failed to improve symptoms, congestion, and urine output (650-750 cc/day) significantly. Further, pleurocentesis was performed, resulting 600cc plural fluid drained. Nevertheless remained unchanged the symptoms. Eventually, we decided to perform abdominocentesis with result of 2500 cc of fluid drained which decreased abdominal circumference from 121 to 96 cm. Two days after procedure, there were improvement of symptoms, congestion, and renal function (Ur 32 Cr 0,9) accompanied with increase urine output (1500-1700cc/day).

Conclusion

In this case, the Renal Tamponade Hypothesis proposes that abdominal decompression can lead to improved renal function in patients with heart failure. This finding suggests that further research is warranted to investigate the potential of this approach as a novel therapy for managing renal dysfunction in heart failure patients.

Keywords: Mitral Stenosis, Heart Failure, Ascites, Abdominocentesis, Renal Tamponade

Partial Resolution of LA Thrombus in Mitral Stenosis after Optimal VKA Treatment

M.A. Wakasaputra¹, K. Saleh¹, A.F. Ghaznawie¹

Department of Cardiology and Vascular Medicine, Faculty of Medicine, University of Hasanuddin¹

Partial Resolution of LA Thrombus in Mitral Stenosis after Optimal VKA Treatment

Dr. M. Archie Wakasaputra, Dr. dr. Khalid Saleh, Sp.PD-KKV, dr. Aussie F. Ghaznawie, Sp.JP(K)

Department of Cardiology and Vascular Medicine, Faculty of Medicine, University of Hasanuddin

Abstrak

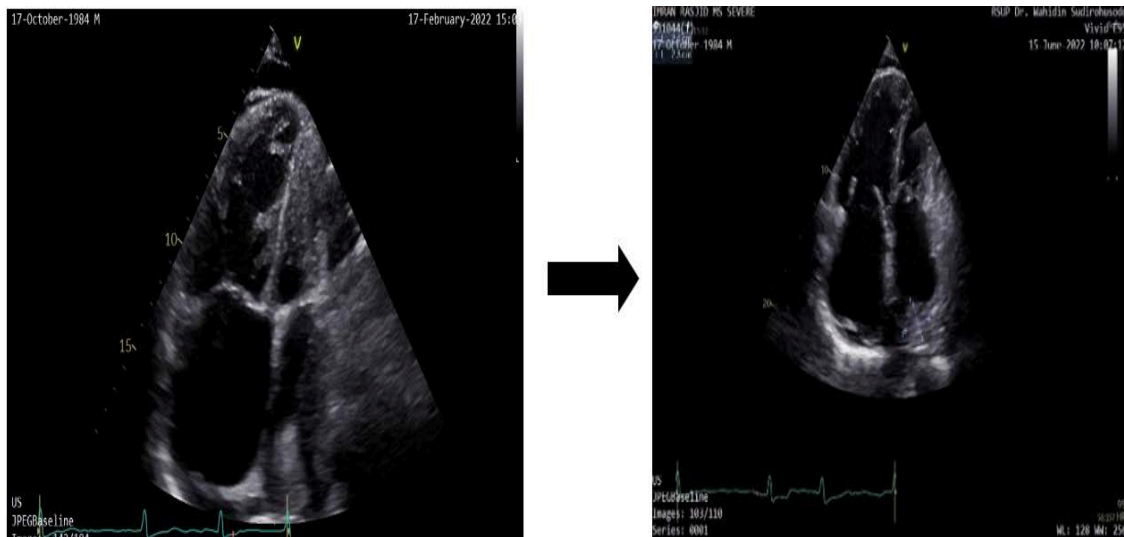
Background : Left Atrial (LA) thrombus until now still remains as the main reason of morbidity in mitral stenosis due to rheumatic heart disease. This condition caused by slow and static blood flow in left atrial due to stenosis in mitral valve and corresponding arrhythmia like atrial fibrillation can aggravate static blood flow. Some research claims that prevalence of LA thrombus is 5 – 27% in atrial fibrillation patient due to mitral stenosis


Case Illustration : We reported a 37 years old man with mitral stenosis, LA thrombus and corresponding atrial fibrillation. Transthoracic echocardiography showed 4,6 x 2,3 cm thrombus in left atrial. Thus, we preceded to treat with warfarin 2 mg/day. After 3 months of anticoagulation, we re-examine transthoracic echocardiography, and we found the size of preexisting thrombus decreased to 2,4 x 2,3 cm.

Conclusion : LA thrombus is a long term complication in mitral stenosis plus atrial fibrillation, this situation is caused by Virchow's triad : abnormal blood flow, abnormal vessel structure and abnormal blood constituents. To treat this condition, we need a medicine that can work as thrombolytic. In this report, we found that the use of anticoagulant like Vitamin K antagonist (warfarin), has thrombolytic properties in addition to its anticoagulant properties through thrombin-activated fibrinolysis inhibitor (TAFI) mechanism. In one study, warfarin has an additional nature as thrombolytic by reducing plasma TAFI which then cause thrombolytic action in preexisting thrombus.

Keywords : Left Atrial Thrombus, Mitral Stenosis, Atrial Fibrillation, Vitamin K Antagonist, Virchow's triad, Warfarin, Fibrinolysis, Thrombin-Activated Fibrinolysis Inhibitor

Keywords: left atrial thrombus, mitral stenosis, atrial fibrillation, vitamin K antagonist, warfarin





**EMERGENCY TREATMENT OF THE RARE HYPERKALEMIA INDUCED SYMPTOMATIC
BRADYCARDIA IN A DIABETIC TYPE II PATIENT, WHATS TO USE?**

S. Ashari¹, P.S. Bustanul¹
RSUD H. Abdul Manap¹

**EMERGENCY TREATMENT OF THE RARE HYPERKALEMIA INDUCED SYMPTOMATIC
BRADYCARDIA IN A DIABETIC TYPE II PATIENT, WHATS TO USE?**

Sara Ashari, Puspita S. Bustanul

BACKGROUND

Diabetes increases the need for pacemaker and other complications including hyperkalemia. In severe conditions, hyperkalemia induced cardiac conduction disturbances and arrhythmias, but the clinical symptoms that appear do not only depend on blood potassium levels but also due to the use of drugs and co-morbidities.

CASE ILLUSTRATION

A 69-year-old woman came to our hospital with signs of acute heart failure, she has history of type II DM and hypertension, no history of previous heart disease. The patient regularly consumes bisoprolol and other drugs. At the presentation the patient's vital signs was relatively stable except for decreased pulse up to 30 beats per minute. On ECG examination we found atrial to ventricular conduction block and disappearance of the P wave. Due to limited facilities, initial management was carried out by giving atropine but administration of a maximum 3 mg showed a poor response with a progression to cardiogenic shock. We decide to use dopamine then. Severe hyperkalemia is treated with triple drug therapy; calcium gluconate together with a combination of 40% dextrose infusion and insulin Aspart, as well as salbutamol's nebulization, all of which are carried out under the supervision of the emergency room. Failure of an adequate response and worsening of shock led to sodium bicarbonate infusion and initiation of norepinephrine. The patient's condition improved 12 hours later with the return of hemodynamic stability. The patient was then referred to a higher center.

CONCLUSION

In our patient, administration of dopamine and triple therapy alone was unable to control hemodynamics, so sodium bicarbonate and norepinephrine infusion were needed to restore the patient's general condition until finally referred to a higher center.

KEYWORD : Bradycardia, Hyperkalemia, DM.

Keywords: Bradycardia, Hyperkalemia, DM.

Inferior STEMI Induces Cardiogenic Shock, Sinus Bradycardia with First Degree AV-Block in Type 2 Diabetes Patient: How We Optimize the Treatment in Life-Threatening and Poor Outcome Patients in Type C Rural Hospital

W. Fathurrachman¹, A.Sunata²
Sambas General Hospital¹

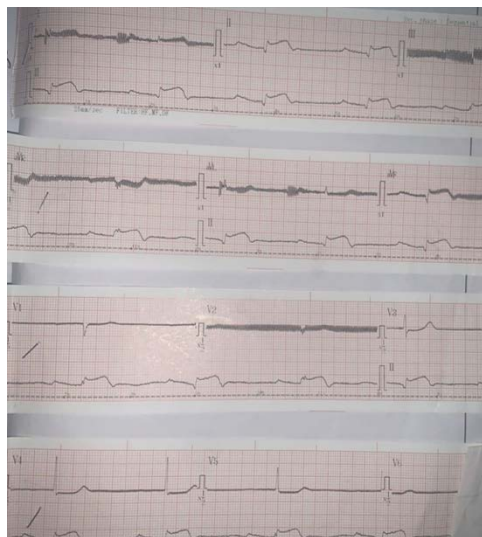Department of Internal Medicine of Sambas General Hospital²

Background: Inferior ST Segment Elevation Myocardial Infarction (STEMI) is a life-threatening condition. Almost 40% of the STEMI cases are inferior STEMI. Some complications that can occur because of inferior STEMI are supraventricular Arrhythmia, conduction blocks, right ventricular infarction. This condition can impair blood to the left ventricle and make the left ventricular underfilled, thus leading to Cardiogenic Shock.

Case illustration: A 69-year-old woman was admitted to the emergency department from other hospital with dull retrosternal chest pain for 25 hours. She was in acute distress secondary to the pain. She had a history of diabetes. This patient was diagnosed before in other hospital with inferior STEMI, type 2 diabetes and congestive heart failure and was treated with fluids, diuretics, PPIs, rapid-acting insulin, antiplatelets, ARBs, beta blockers, nitrates, lactulose, and sucralfate. The next day, patient's blood pressure dropped to 60/palpation. She was then referred to our hospital. On arrival, the patient was in pain with a blood pressure 70/palpation, a pulse of 51 bpm, 24 breaths per minute, 100% oxygen saturation with 4 lpm oxygen therapy via a nasal cannula. General examination revealed cold extremities. The ECG showed sinus bradycardia with ST elevation in leads II, aVF, ST depression in leads I, aVL and First-Degree AV Block. The patient's diagnosis was Sinus Bradycardia with Inferior STEMI Killip IV (Dry and Cold) with 25 hours onset, Cardiogenic Shock, First Degree AV-Block, and DM Type-2. In the ED, the patient received fluids, Oxygen, Dual antiplatelet therapy, rapid-acting insulin, unfractionated heparin, ionotropes. Even without revascularization, the patient was alive and the discharge after 6 days treated in the intensive care unit.

Conclusion: Adequate and appropriate management inferior STEMI may prevent life-threatening complications such as cardiogenic shock, conduction blocks especially in rural Hospital without availability of revascularization facility.

Keywords: Inferior STEMI, Cardiogenic Shock, AV-Block, DM Type 2, Rural.



Sinus Bradycardia with First Degree AV-Block and ST-segment elevation in leads II, aVF

AORTIC DISSECTION IN MARFAN SYNDROME: A DIAGNOSTIC APPROACH

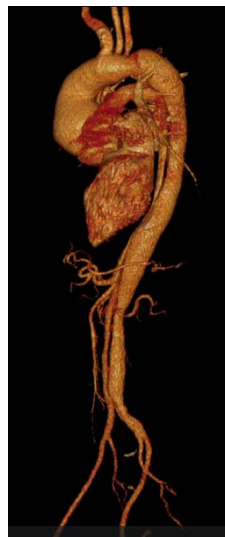
R.G. Adam¹, A.H. Alkatiri¹, A.F. Ghaznawie¹
Hasanuddin University¹

Background: The prevalence of Marfan syndrome (MFS) cases is estimated to be 1 per 5,000 population and 26% of patients have no family history of similar disease. Aortic dissection (AoD) is the main cause of death in MFS patients, with a mortality rate of approximately 1-3%. Medical treatment might not cure nor restore anatomical and physiological functions, however it could reduce the progression and severity of symptoms. This case report discusses MFS and AoD diagnosis and their treatment.

Case illustration: A 33-years old man came with a main complaint of intermittent shortness of breath in the last month and worsens for the last week. There was hypertension history and cardiovascular disease history in the family, where the patient's uncle died at the age of 40-years old with a tall stature. The patient also had a history of visual acuity problem. Physical examination using the Ghent criteria revealed a score of 10, and investigations showed widening of the aortic root on echocardiography. A thoracic computed tomography scan revealed AoD, hence the patient was diagnosed with a working diagnosis of congestive heart failure New York Heart Association (NYHA) class III, MFS, and AoD Stanford A. The patient did not approve for surgical treatment, therefore conservative treatment was opted with ACE-inhibitor and beta-blocker drugs as well as education for physical activity restrictions.

Conclusion: Young patients <40-years old with AoD should be suspected of MFS. Aortic root disease occurs in approximately 50-60% of adult Marfan syndrome patients and could easily be detected on echocardiography. Aortic root disease causes progressive aortic root aneurysms and is a major cause of morbidity and mortality in MFS. Diagnosis and treatment of MFS requires multidisciplinary management. A thorough physical examination, eye exam, genetic evaluation, radiography, and echocardiography are routinely recommended for clinical diagnosis. The Ghent criteria is useful for MFS diagnosis. Treatment must be tailored to clinical manifestations, because each patient has varying degrees of organ involvement.

Keywords: Marfan syndrome, aortic dissection, echocardiography, aortic root



A Diagnostic Challenge in Peripartum Cardiomyopathy with Chronic Kidney Disease: A Case Report

B.B. Pratiwi¹, A.A. Asmiragani²
General Hospital dr. Soediran Mangun Soemarso¹
General Hospital Universitas Brawijaya Malang²



Background

Peripartum cardiomyopathy is a potentially life-threatening pregnancy-associated disease that develops in the last trimester of pregnancy to 5 months postpartum. It is characterized by left ventricular dysfunction and heart failure. Symptoms of heart failure resemble those of a healthy pregnancy, making it challenging to diagnose and often resulting in a delay in diagnosis. Here, we present an unusual case of PPCM complicated by chronic kidney disease.

Case Illustration

A 34-years old woman with a history of preeclampsia pregnancy a year ago presented in the emergency department with symptoms of orthopnea, paroxysmal nocturnal dyspnea, and leg swelling for two days before admission. In 2 months postpartum, she also had similar symptoms and was hospitalized in a private hospital. The cardiologist prescribed her Clonidin and Propanolol as anti-hypertensive medications but she only took them for two months.

The physical examination showed blood pressure of 200/120 mmHg, tachycardia, no jugular venous distension, bibasilar crackles with decreased air entry at bases, pitting edema of legs, and SpO₂ (oxygen saturation) of 89%. A chest X-ray study showed pulmonary oedema with bilateral pleural effusion and cardiomegaly. Electrocardiography showed sinus tachycardia and poor R-wave progression. An echocardiogram performed on hospital day revealed left ventricular systolic dysfunction (ejection fraction 43%) and mitral regurgitation. The initial laboratory findings showed the levels of urea 212 mg/dl; creatinine 18.5 mg/dl; and eGFR 2.0 mL/min/1.73m². Cardiac marker couldn't be done because of limited facilities.

The patient was monitored in the intensive care unit (ICU). IV (intravenous) Furosemide and Nefrosteril were administered for the initial treatment. She required three hemodialysis sessions. The patient continued to improve clinically after therapy and still routinely undergoing routine hemodialysis two times one week.

Conclusion

The diagnosis of PPCM should be considered anytime a woman presents with even mild symptoms of heart failure in the last month of pregnancy or within the first 5 or 6 postpartum months. Early diagnosis is important and effective treatment is needed to decrease further complications such as chronic kidney disease.

Keywords:

Peripartum Cardiomyopathy; Chronic Kidney Disease; Hypertension

Arteriovenous Graft Thrombosis: Upper Extremity DVT in AV Graft Failure Post Covid-19 at Prof Dr. IGNG Ngoerah Hospital

I.W. Gunawan¹, B.A.P. Sutanegara¹, A.P. Suwirya¹

Division of Vascular Division, Department of Cardiology and Vascular Medicine, Prof Dr. IGNG Ngoerah Hospital, Denpasar, Indonesia¹

Background

Up to 10% of all DVTs are UEDVT. AV graft failure which manifests as AV graft thrombosis is a form of secondary UEDVT. It was considered as a major clinical event because it is strongly associated with increased mortality.

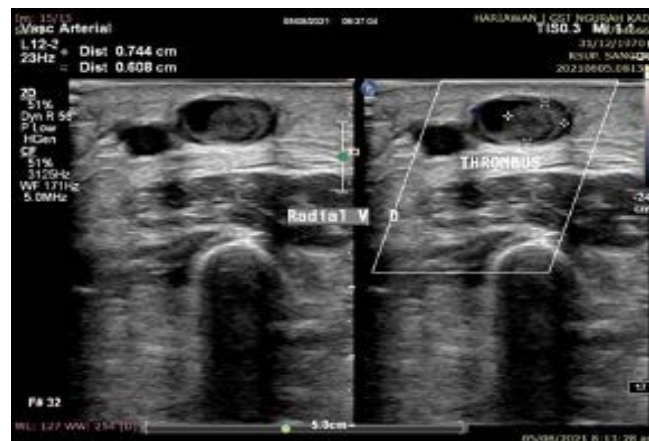Case Illustration

A male, 52 years old, complained swelling of the right hand since two weeks. There was a history of it one year before, DM with insulin, hypertension, CKD on regular HD. Venography one year ago revealed of total occlusion of the right innominate vein, also AVF RC pseudoaneurysm by duplex US. Then performed ligation of right AV BC shunt and Pseudoaneurysm, installation of left AV BC shunt. Temporary venous tunnelling access also experiencing recurrent thrombosis. That also aggravated by the patient was confirmed Covid-19 before. Physical examination revealed right upper extremity was oedema. Increased D-dimer (2.56 U_g/mL), decreased LV systolic function (EF BP 43.4%), with RWMA. Right upper extremity Duplex US shows thrombus appears in the right brachial vein with diameter of 7.4 x 6.8 mm (short axis), 19.2 x 4.3 mm (long axis) (**Figure 1**). Despite Well's score support the diagnosis was established with UEDVT, patients are treated by anticoagulant warfarin at a dose according to INR, failure, CAD, antihypertensives therapy, insulin, HD regular 3 times a week with heparin.


Conclusion

Management of predisposing factors & risk of thrombosis, maintain adequate HD were crucial on the future to improve strategy for early detection of thrombotic recurrence and subsequent management AV graft thrombosis for optimal treatment outcomes.

Keywords: AV Graft Thrombosis, UEDVT, AV Graft Failure, Post Covid-19.



Right upper extremity Duplex US



Respiratory Failure and Cardiogenic Shock in Advanced Heart Failure Patient: A Case of Survivor without Mechanical Circulatory Support Device

W. Tussakinah, C.I. Rahayu, B. Widyantoro
EMC Sentul Hospital, Sentul, Bogor

BACKGROUND

Acute pulmonary edema is a common case of acute respiratory distress in emergency department (ED). It has a high mortality rate up to 40%. Pulmonary edema can cause severe hypoxia and hypoxemia leading to respiratory failure and multi organ dysfunction. In pre-existing chronic heart failure patient, this condition further deteriorated myocardial function and triggered cardiogenic shock


CASE ILLUSTRATION

A 62 – year –old male admitted to ED with excessive shortness of breath from 30 minutes before. He felt shortness of breath graduating for a week. They were chest discomfort, fever, and wet cough reported. The patient was a smoker for 3 packs/day and had been diagnosed with heart failure while hospitalized 5 months before. He took medicine not regularly; spironolactone 25mg OD and valsartan 80mg OD. He denied history of myocardial infarction, stroke, hypertension, dyslipidemia and diabetes. In ED, The patient fully alert and gasping, his blood pressure was 90/50, HR 130 bpm, T 37.4 °C, RR 35x/m, SpO₂ 76-82. Physical examination found JVP 5+3 cmH₂O, rales 2/3rd up in bilateral lungs, cold extremities and clammy skin without edema. ECG showed sinus tachycardia with old LBBB. Laboratory revealed leukocytosis, increased NT-proBNP and respiratory acidosis. Echocardiography showed dilated heart with low LVEF 12-15% and TAPSE of 12 cm. The patient was diagnosed with cardiogenic shock following episode of acute pulmonary edema, triggered by pneumonia in advanced biventricular HF patient. The respiratory failure was treated with mechanical ventilation. The use of inotropes, vasopressor and ventilator setting were adjusted by close hemodynamic monitoring by cardiac intensivist with non-invasive echocardiography in ICCU. The patient was then treated with optimal medical therapy with antibiotics, lung protective ventilation strategies with low PEEP, restrictive fluid management, inotropes and vassopressor agents. Patient was successfully extubated in day-7, have a recovery phase with cardiac rehabilitation, and discharged with stable condition after 12-days hospitalization with optimal goal directed medical therapy for HF.

CONCLUSION

Treatment of respiratory failure and cardiogenic shock in advanced biventricular HF patient is challenging. Rapid assessment and cardiac intensive care management guided by non-invasive hemodynamic monitoring is needed to stabilize the patient.

Keywords: Respiratory Failure, Cardiogenic Shock, Heart Failure



Unexpected Cerebellar Infarction in A Patient with Tetralogy of Fallot: A Very Rare Complication

O. Sofyan¹, Y. Patimang¹
RSUP dr Wahidin Sudirohusodo¹

Background: Along with the increasing number of survival rate of Tetralogy of Fallot patients, the higher the incidence of complications of the disease. In TOF patients who do not undergo correction, the degree of RVOT stenosis is considered a factor that contributes to the risk of complications, one of which is hyperviscosity syndrome. incidence of cerebellar infarction in patients with TOF has not been previously reported.

Case illustration: 21 years old male came to Emergency Room with chief complaint headache, frequent vomiting and lightheadedness. When the patient was 2 y.o, patient started to felt shortness of breath during activities, squatting while dyspnea and looks cyanotic. Parents then brought the patient to Cardiology Pediatric and explained the patient had been diagnosed with ToF in whe he was 15 y.o, then lost to follow up. Physical examination showed underweight and oxygen saturation of 86% with room air at average extremities. the cardiac auscultation presence of right ventricular heaves, systolic murmur at ULSB with Grade III/VI. On the extremities showed cyanosis, clubbing fingers and syndactyly in left hand. The laboratory examination showed secondary polycythemia, coagulation abnormality, and elevated Fe serum. The electrocardiography showed extreme right axis deviation, RAE, RVH, abrupt R wave. The chest x-ray showed suggestive TOF. The echocardiography showed Tetralogy of Fallot and EF 40.1%. Brain MSCT scan and MRI showed cerebellum infarction. During the hospitalization, we treated the dehydration as the patient's hyperviscosity trigger with adequate rehydration and beta blocker as conservative treatment. From neurology department, the patient got symptomatic therapy supportive treatment with neuroprotector agent.

Conclusions :

We described a patient with a diagnosis of Tetralogy of Fallot and discuss the main outcome, diagnostic, and management aspects of the complication of this disease, which is cerebellar infarction. Symptomatic supportive treatment was effective in improving patient's complaint and motor condition.

Keywords: Cerebellar Infarction, Hyperviscosity Syndrome, Tetralogy of Fallot

CARDIAC REHABILITATION IN NO REVASCULATION PATIENT WITH CORONARY ARTERIAL DISEASES AND CABG SUGESSTION

C.T. Tjahjono¹, V. Mayangsari¹, C. Kahadi¹, A.Y. Suprpta¹
Brawijaya University - Saiful Anwar General Hospital¹

Background

Coronary heart disease (CHD) are still the leading cause of death throughout the world. An evidence-based medical studies have shown that cardiac rehabilitation can significantly reduce the days and cost of hospitalization, mortality, and cardiovascular events in patients with CHD. Studies showed that outpatient cardiac rehabilitation programmers could provide some benefits for patients, such as convenience, fitness, improved functional capacity, quality-of-life, as well as blood pressure. In this paper, we describe a case of patient with Coronary Arterial Disease (CAD) who refuse to Coronary Artery Bypass graft (CABG) and got Cardiac Rehabilitation.

Case Illustration

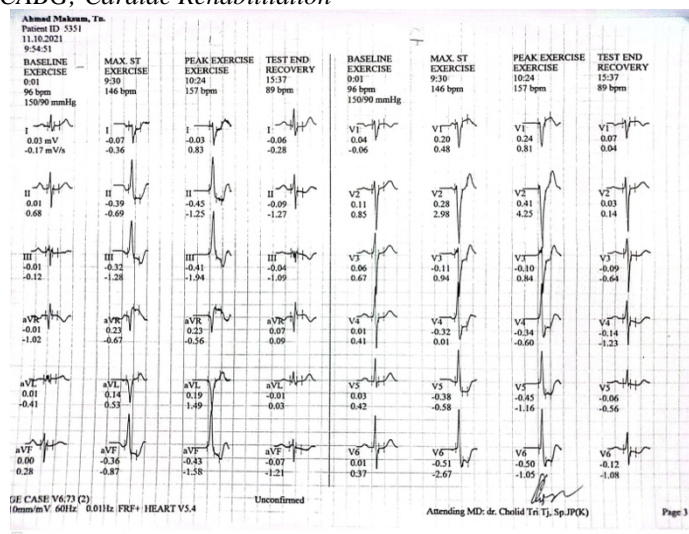
A 60-year-old Asian male was diagnosed as CAD 3VD with CTO at mid LAD and proximal RCA. He was suggest to CABG procedure, but because personal and family preference, he refuse taking that procedure. Sometimes he got chest discomfort when moderate to heavy activities, but it got better. He was in stable hemodynamic after discharge with BP 130/80, HR 70bpm, RR 20tpm, SPO2 99% Room Air. He got 6-minutes walking test and got 595m distance, 4,9 Mets and VO2 Max 17ml/Kg/min. Then he prescribed Phase II Rehabilitation with initial 3,6km/h and target 5,9km/h. After 4 weeks, patient taken Treadmill Evaluation with Bruce Protocol and got total 10.23min exercise time, max HR 96%, max BP 210/100, 13,5Mets, Functional Capacity I, DTS Score -12 (Risk Category High, 5 Years Survival 72%). After that he continue rehabilitation until target 5,9km/h. Treadmill evaluation in 8 weeks, he got increase his functional capacity and prognostic with total 11.42min exercise time, max HR 107%, max BP 170/90, 13,5Mets, Functional Capacity I, DTS Score -6 (Risk Category Moderate, 5 Years Survival 91%).


Conclusion

Cardiac rehabilitation can be a choice to improve functional capacity, quality-of-life as well as blood pressure, also increase prognostic in Patient with CAD and No Revascularization.

Keywords:

No Revascularization; CABG; Cardiac Rehabilitation





Supraventricular Tachycardi In Children With Dengue Fever

Y.D. Amalia¹, H.M. Rini¹, D. Eunike¹, A.J.C. Kamalo¹, M. Mahbubi¹, I. Fahmi¹
RSUD RAA Soewondo Pati¹


Background: Dengue fever (DF) is known to involve the cardiac. Cardiac complications in DF patients include atrioventricular conduction disorders, arrhythmias, myocardial disorders, and myocarditis. In this report, we present a case of supraventricular tachycardia (SVT) as the initial presentation of an children DF.

Case illustration: A 16-year-old girl presented with sudden onset of palpitation and breathlessness. She had fever for 3 days. Her blood pressure was 86/58 mmHg, pulse rate was 194 beats/minute, regular rhythm. Capillary refilling time was less than two seconds. The laboratory result showed leukopenia ($2.7 \times 10^3/\text{ul}$), trombositopenia ($71 \times 10^3/\text{ul}$), dengue IgG was positive. Electrocardiogram (ECG) showed SVT with the rate of 187 beats/minute. The child was diagnosed with DF complicated by SVT. Because the patient's condition was unstable. A 50 Joule (1J/kg) synchronous cardioversion was performed, followed by 2nd 100 joule (2J/kg) cardioversion because there was no response. The ECG remains unchanged after the cardioversion, therefore pharmacological therapy is needed. Injection of Amiodarone 150 mg IV was given because Adenosine was not available. Second injection of Amiodarone was also given because there was still no response after the 1st dose. The cardiac rhythm reverted to sinus rhythm.

SVT complication is less frequent in DF. Membrane potential changes as a result of inflammatory processes and cytokine storms affecting myocytes and the interstitium can lead Arrhythmias in DF. The treatment strategy of SVT depends on the hemodynamic condition. Cardioversion is needed to terminate SVT in children with unstable hemodynamic. In our case, SVT was no response to cardioversion, therefore pharmacological therapy was chosen. Adenosine is considered the drug of choice, if it's not available, Amiodarone IV may be a therapeutic option.

Conclusions: DF can lead to arrhythmias in some cases. Monitoring and managing cardiac arrhythmias are required in DF.

Keywords: Dengue fever, Supraventricular tachycardia



Modified pharmacological cardioversion in atrial fibrillation patients without significant structural heart disease: Case series from remote area

E. Zuhri¹


Teluk Bintuni Hospital, Papua Barat, Indonesia¹

Background. Based on the currently available evidence, the indication for rhythm control is to reduce atrial fibrillation-related symptoms and improve quality of life. In case of uncertainty, an attempt to restore sinus rhythm in order to evaluate the response to therapy may be a rational first step. Pharmacological cardioversion to sinus rhythm is a procedure indicated in haemodynamically stable patients. The choice of a specific drug is based on the type and severity of associated heart disease. But, in remote area, sometimes the only drug available is amiodarone. Amiodarone is given by giving a bolus of 5-7 mg/kg over 1-2 hour followed by an infusion of 50 mg/hour through a large vein. However, prolonged infusion of amiodarone can cause some serious side effects.

Case illustration. We made modified pharmacological cardioversion by giving 150 mg of amiodarone intravenously over 30 minutes in combination with 2.5 mg of bisoprolol orally in four patients with atrial fibrillation without significant structural heart diseases. If within one hour the rhythm had not been converted to sinus rhythm, another 150 mg of amiodarone was given intravenously over 30 minutes. The rate of conversion to sinus rhythm was achieved in less than 3 hours after the first administration of intravenous amiodarone and bisoprolol orally. There was no recurrence within 6 months of follow-up.

Conclusion. Combination intravenous amiodarone and bisoprolol showed its effectiveness in converting and maintaining sinus rhythm. However, a bigger sample of randomized control trial needs to be done to show the effectiveness combination intravenous amiodarone and bisoprolol orally.

Keywords: amiodarone, atrial fibrillation, bisoprolol



Cardiorenal Syndrome: A Case Report of Acute Decompensated Heart Failure and Glomerulonephritis in a Young Patient

Suhardi¹, A.E. Putri¹, J.A. Samjaya¹
RSUD Taman Husada Bontang¹

Background

Cardiorenal syndrome (CRS) is a clinical condition that impacts both the heart and the kidneys, dysfunction of one organ leads to acute or chronic dysfunction of the other and received very little research attention in children. This clinical case report is to highlight the unusual event of CRS in young patient with symptoms of acute heart failure and glomerulonephritis had a good outcome result.

Case Illustration

A 13 years old boy presented with shortness of breath, peripheral edema and tiredness. He had no medical history of disease. His blood pressure was 145/90 mmHg, regular heart rate 124 bpm, high respiration rate, inadequate to oxygen mask therapy therefore intubation is necessary. Physical examination got rhonchi bilateral on his lung and peripheral edema. ECG was sinus tachycardia. Transthoracic echocardiograph found LVEF 23%, global hypokinesis, normal chamber dimensions, and no valve dysfunction. Chest x-ray were batwing appearance and bilateral pleura effusion. Laboratory found leukocytosis, increase creatinine levels, high ASTO and CRP levels, and in urinalysis got gross hematuria also proteinuria.


Treatment that has been given was sacubitril-valsartan and bisoprolol per oral, injection of furosemide, ceftriaxone, omeprazole, and dexamethasone, and nebulizer with fluticasone, salbutamol.

In this case, significant improvement within 3 days after an adequate treatment and extubation within 4 days. In day 10 of treatment, patient got resolution of symptoms and echocardiograph shows normal cardiac function with LVEF 68%.

Conclusion

CRS have a higher risk of death and morbidity than those with each disease entity alone. The heart and kidneys interact bidirectionally and interdependently through several mechanisms. However, in pediatric patient even the evidence rarely to be found, this case illustrates the prompt and adequate treatment leading to optimal patient outcome, restore ventricular function and can be used in similar cases in the future.

Keywords: Cardiorenal syndrome, Acute Heart Failure, Glomerulonephritis



LARGE PERICARDIAL EFFUSION WITH TUBERCULOUS PERICARDITIS: A CASE REPORT

A.I.R. Paputungan*1, A.H. Nashar1, J. Kusumanegara2, I. Djaharuddin3

1Department of Cardiology and Vascular Disease, Medical Faculty, Hasanuddin University, Makassar

2Department of Thoracic Surgery, Medical Faculty, Hasanuddin University, Makassar

3Department of Pulmonology and Respiratory Medicine, Medical Faculty, Hasanuddin University, Makassar

Background: Tuberculous (TB) pericarditis has an incidence of $\leq 4\%$ of all pericardial disease in developing countries. Fifty to seventy percent of pericardial effusion cases are caused by TB in endemic countries. Assessment of TB infection possibility in pericarditis patients with epicardial effusion is important for cardiologists to provide adequate treatment. This case report discusses a case of large pericardial effusion with TB pericarditis.

Case illustration: A 19-years old female was referred to our hospital with a chief complaint of shortness of breath accompanied by intermittent fever and cough. Physical examination results revealed tachycardia and decreased breath sounds in right hemithorax. Echocardiographic examination revealed a large pericardial effusion. The patient underwent a pericardial window procedure then examined for pericardial fluid analysis and cytology. Chronic granulomatous inflammation was found with a specific process suggestive of TB pericarditis. The patient's Tygerberg score was 6, hence TB Pericarditis diagnosis could be established. The patient was treated for 18 days at Wahidin Sudirohusodo Hospital and was then given category 1 anti-tuberculosis drug treatment for 8 weeks and was sent home in stable condition.

Conclusion: Pericarditis is the main cause of pericardial effusion. Infection is often the main cause, one of which is TB infection. Diagnosing TB pericarditis could be challenging. Pericardial window is a procedure that could be both diagnostic and therapeutic in pericardial effusion. The Tygerberg score could also help its diagnosis. A total score ≥ 6 could establish TB pericarditis diagnosis with sensitivity = 86% and specificity = 85%.

Keywords: TB pericarditis, pericardial effusion, pericardial window, Tygerberg score



Ventricular Tachycardia and NSTEMI in a Patient with Prolonged QT Interval and Atrial Fibrillation: A Case Report

R.R. Eri¹, F. Setiyarizki¹, F.S.A. Pradana¹
RSUD Bagas Waras Klaten¹

Background

Prolonged QT interval is a condition where the heart takes longer than normal to recharge between beats, which can lead to increased risk of cardiac arrhythmia such as ventricular tachycardia and torsades de pointes. Meanwhile, atrial fibrillation is a type of arrhythmia that occurs when the electrical impulses that regulate the heartbeat become rapid and disorganized in the upper chambers of the heart. The combination of these two conditions might increase the risk of ventricular tachycardia, but whether it increase the risk of myocardial infarction is yet to be understood.

Case Illustration

A 73-year-old patient presented to the ED with general weakness, blurred vision, and epigastric pain, had seizure at home with duration of 5-10 minutes, with brief loss of consciousness. The patient had no neurological deficit, no headache, no palpitation. On presentation, patient had blood pressure of 140/90 mmHg, heart rate of 56 beats per minute. The patient has history of prolonged QT interval and atrial fibrillation. ECG revealed monomorphic ventricular tachycardia. The patient received synchronized cardioversion and lidocaine infusion. Later on, we found that the patient had elevated troponin-I levels, diagnosed with NSTEMI.

Conclusion

This case highlights the potential increased risk of ventricular tachycardia and NSTEMI in patient with prolonged QT interval and atrial fibrillation. Further studies are needed to better understand the underlying mechanisms and potential increased risk of myocardial infarction in these patients. This case report adds to the limited literature on the potential risks associated with the combination of prolonged QT interval and atrial fibrillation and emphasizes the importance of careful monitoring and treatment in these patients.

Keywords: Prolonged QT interval, Atrial fibrillation, Ventricular tachycardia, NSTEMI

A Reversible Type 1 Brugada-Like ECG Pattern In 67 Years Old Woman : A Syndrome or A Phenocopy?

A.R. Ananda¹, M. Amir², A.F. Muzakkir²
Wahidin Sudirohusodo Hospital, Makassar¹
Department of Cardiology Hasanuddin University²

Background : Brugada Syndrome (BrS) is an autosomal-dominant inherited disorder characterized with a typical ST Elevation followed with negative T wave in the right precordial leads without any structural cardiac malformations. Brugada Phenocopy is a clinical condition characterized by an identical ECG pattern to congenital Brugada Syndrome in general triggered by various factors. It is important to differentiate both conditions, here we reported a case of a 67 years old woman with a typical Brugada-Like ECG Pattern.

Case Illustration : A 67 years old woman admitted to the emergency unit due to her ongoing atypical chest pain with onset 5 hours accompanied with fever and cough 2 days prior her admission; her vitals showed elevated temperature 37.7 C; her ECG showed a typical coved typed ST segment elevation in V2 and inverted T wave in lead V1-V3 in accordance with type 1 Brugada's ECG pattern. Laboratory test demonstrated normal level of high sensitive troponin I (10.9 ng/l) with slightly elevated WBC (11.400/uL). Echocardiography was normal with LVEF 67%. However her Chest CT showed infiltrates in her right lung confirming Pneumonia. The patient was treated with prompt antipyretic, antibiotics, and mucolytic. After 3 days of treatment her ECG converted to normal without any documented episode of life-threatening arrhythmias, she was then discharged with stable condition and hemodynamic.

Conclusion : It is important to distinguish the diagnosis of Brugada Phenocopy to true Brugada Syndrome in order to achieve the right treatment. Pneumonia can be a factor in occurrence of Brugada Phenocopy. At this point, the right treatment for Brugada Phenocopy is to ameliorate the underlying conditions.

Keywords: Brugada Pattern, Arrhythmia, Phenocopy, Pneumonia, ECG

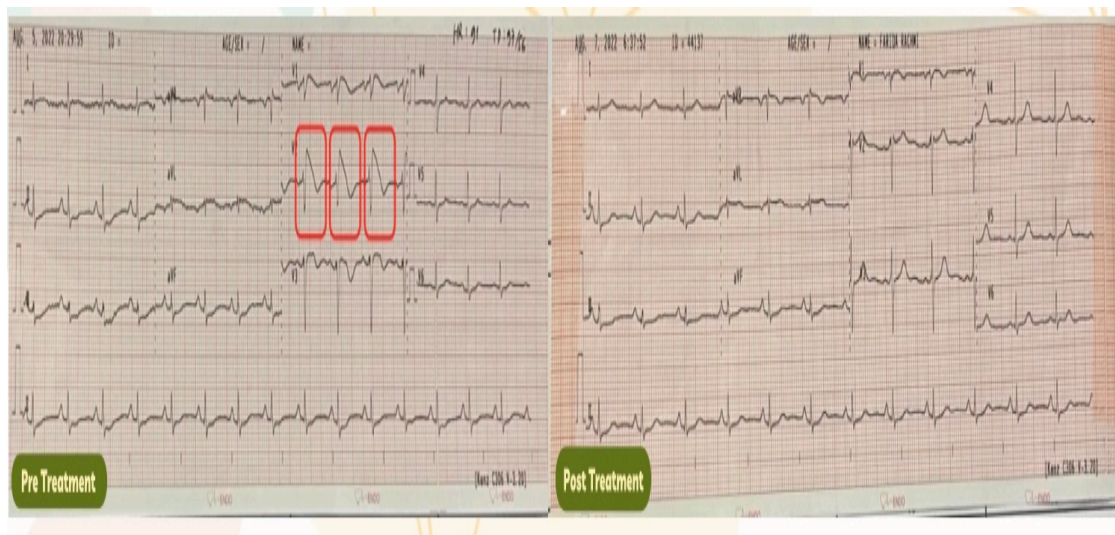



Figure 1. TransThoracal Echocardiography and MSCT Cardiac Aortography



Atrial Septal Defect (ASD) with Eisenmenger Syndrome Manifested with Clinical Sign of Left Heart Failure: a Case Report

S. Azzahra¹, M.J. Al-Farabi², M.Q. Ayun², T.R. Mahmudah², E. Hindariati²

Faculty of Medicine, Universitas Airlangga - Dr. Soetomo General Academic Hospital, Surabaya, Indonesia¹

Department of Cardiology and Vascular Medicine, Faculty of Medicine, Universitas Airlangga - Dr. Soetomo General Academic Hospital, Surabaya, Indonesia²

ABSTRACT

Background : Atrial septal defect (ASD) is usually manifested with pulmonary hypertension and right heart failure. Interestingly, we found an Acuted decompensated heart failure (ADHF) situation which may related with the presence of long-term ASD and right heart failure which led into left heart failure..

Case illustration : Woman, 50 years old, complained shortness of breath during heavy activity, worsening over the last five days, orthopnea and paroxysmal nocturnal dyspneu. Patient found out having septal defect, often seek for treatment but do not routinely take medication. ECG showed atrial fibrillation with rapid ventricular response with normal frontal dan horizontal axis. From chest x-ray, found cardiomegaly with prominent conus pulmonum and inverted coma sign, lungs got parahillar hazziness. Echocardiography showed ASD (3.4 cm) with bidirectional flow dominant R to L with high probability of pulmonary hypertension (TRVMax 4.5m/s) and RV failure (TAPSE 1.4 cm) with B lines suggesting congestion due to LV failure. Patient then treated with diuretics, inotropes (milrinone), and prostacycline analog (iloprost) and relieved her symptoms.

Conclusion : ADHF can also occur in longstanding ASD which has been manifested with rapid atrial fibrillation, pulmonary hypertension crisis and RV failure which then followed by LV failure. Diuretics combined with pulmonary hypertension drug remained effective treatment for this case.

Keywords: ADHF, ASD, Atrial Fibrillation, Eisenmenger Syndrome



Case Series of Total Atrioventricular Block (TAVB) Complicating Acute ST-Elevation Myocardial Infarction (STEMI): Culprit Vessel-Only or Complete Revascularization Strategy?

F.A. Nurullah¹, N.R. Utantyo¹
Embung Fatimah Regional Public Hospital¹

BACKGROUND

Total atrioventricular block (TAVB) is associated with poor clinical outcomes in ST-elevation myocardial infarction (STEMI). We compared two patients with chest pain and hemodynamic instability with different time delay to reperfusion.

CASE ILLUSTRATION

Patient A, 61 year old male with history of uncontrolled hypertension, was referred to our hospital with inferior STEMI 28 hours after onset and TAVB. Patient B, 66 year old male, with unknown medical history, came to our hospital complaining 2 hours onset of typical chest pain and shortness of breath. Both patients were hemodynamically unstable and both laboratory results showed elevated troponin I, additionally patient B has elevated blood glucose, liver enzyme and creatinine level. Both were diagnosed as acute inferior STEMI, TAVB and cardiogenic shock, patient B also has diabetes, secondary hepatic and kidney injury. Coronary angiography showed acute total occlusion in proximal right coronary artery (RCA) and significantly stenosed left anterior descending (LAD). PPCI was performed to the RCA, as culprit vessel. Evaluation showed TIMI flow III on both patients. On the next day, patient A developed acute pulmonary oedema and significant pleural effusion, he was intubated, mechanically ventilated and ultrasound-guided thoracentesis was done. Both patients' condition gradually improved, patient A was successfully being weaned from ventilator after 7 days, ECG returned to sinus rhythm even when temporary pacemaker was off on 8th day. Both patients were successfully discharged home in stable condition after 15 and 10 days of hospitalization.

CONCLUSION

In our case, PPCI was done to the culprit lesion in the acute emergency setting. Some literatures demonstrated there's no significant benefit for STEMI-CS patient treated with complete revascularization compared with culprit vessel-only intervention as patients are at increased risk of developing acute renal failure after multi-vessel intervention. Time from symptom onset to reperfusion is an important predictor of patient outcome.

Keywords: Acute coronary Syndrome, ST-Elevation Myocardial Infarction, Cardiogenic Shock, Total Atrioventricular Block, Culprit Vessel-Only Revascularization, Complete revascularization

A Rare Case Report of ST Segment Elevation in The Presence of Sepsis Complicated by Acute Respiratory Failure : Myocardial Infarction or Not ?

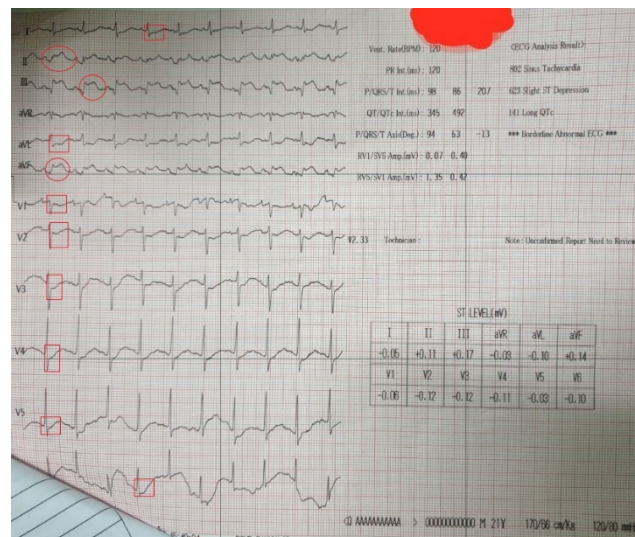
S.D.T. Sitanggang¹, C. J. Purba², N.G. Liman³
 RSUD Pakuhaji, Tangerang¹
 Putri Hijau Hospital, Medan²
 RSUD Pakuhaji, Tangerang³


Background : ST elevation (STE) is widely regarded as the sign of myocardial infarction (MI) along with typical symptoms of ischemia in many clinical settings. Furthermore, this sign was oftenly thought as acute coronary occlusion requiring urgent reperfusion. However, not all ST segment elevation is attributed to acute coronary occlusion, there are various etiologies that may cause STE. Sepsis is known to cause QRS changes and conduction block yet STE is rarely reported. This case report aims to present a rare case of STE in patient with sepsis complicated by acute respiratory failure.

Case Illustration : A 67 years old female was admitted to our emergency unit (EU) with loss of consciousness. Before unconscious, she complained worsening shortness of breath. Around a week ago, she had been hospitalized in our hospital due to pneumonia. No chest pain was reported. No history of cardiac disease. Vital sign on admission was BP 124/82, RR 22x/min, SpO2 80 % RA, HR 120x/bpm, coma state. Ronchi was found in physical examination. Laboratory findings showed leucocytosis 24.000/ul, increased ureum and creatinine, 77 mg/dL and 2,9 mg/dL, respectively. Arterial blood gas showed metabolic acidosis with partial compensation. Chest X-ray showed pneumonia. ECG showed inferior STE with ST depression in antero-lateral lead. She was diagnosed with impaired consciousness, sepsis, acute respiratory failure and pneumonia. Around 6 hours after admission, she had cardiac arrest then cardiopulmonary resuscitation was initiated along with intubation. The patient passed away after 20 minutes of resuscitation.

Conclusion : STE in sepsis can be a misleading condition. STE in sepsis is suggested due to oxygen supply/demand imbalance to myocardium without any occluded artery. These mechanism may cause myocardial injury known as type II myocardial infarction. Therefore, ST elevation during sepsis could rarely occur yet it should not urge physician to immediate reperfusion therapy.

Keywords: sepsis, myocardial infarction, respiratory failure, ST segment elevation





Double culprit ST elevation : Optimal guidance for revascularization completion

Sahniriansa, A.A. Alkatiri, S.S. Danny

Department of Cardiology and Vascular Medicine, Faculty of Medicine, University of Indonesia, Indonesian Cardiovascular Research Center, National Cardiovascular Center Harapan Kita, Jakarta, Indonesia

Background: In ST-elevation acute myocardial infarction, only one epicardial artery commonly contains an occlusive thrombus, widely referred to as the culprit artery. However, it is rare for patients to present with more than one acutely thrombotic coronary artery finding or double culprit.

Case Illustration: A 54-year-old man 30 minute onset of STEMI antero-inferior- RV infarct. He underwent Primary Percutaneous Coronary Angiography (PPCI), angiography showed total occlusion in proximal Left Anterior Descending (LAD) and proximal Right Coronary Artery (RCA), then the implantation of 1 Drug Eluting Stents (DES) in LAD was carried out. During observation at cardiovascular care unit (CVCU), he had an episode of chest pain accompanied by on ECG inferior ST elevation. Repeat angiography was performed, thrombosuction and another DES PCI was implanted in proximal RCA. Post PCI, the patient's physical condition improved, there were no complaints of chest pain. The patient was given optimal therapy and discharged on day 5 of treatment with well condition.

Conclusion: The possibility of double culprit's STEMI should be considered during primary PCI, especially in unstable patients. Rapid restoration of coronary blood flow will save the myocardium and decrease the risk of death. There are currently no guidelines for the optimal management strategy in patients with acute multi-vessel or double culprit. The choice of therapy is based on the patient's clinical and TIMI flow at the time of coronary intervention PCI.

Keywords: Acute ST Segment Elevation Myocardial Infarction, primary coronary intervention, double culprit, multi-vessel coronary thrombus.

“Heart in DRESS”, Heart Failure as Long-Term Effect of Drug Reaction Related Eosinophilia Systemic Syndrome (DRESS Syndrome) Related to Cefadroxil Use: Rare Sequelae of Rare Entity

A.B. Aryaputra¹, H.P. Bagaswoto², P. Mawardi³
RSU Islam Klaten¹

Department of Cardiology and Vascular Medicine, Faculty of Medicine, Public Health, and Nursing Universitas Gadjah Mada – Dr. Sardjito Hospital, Yogyakarta, Indonesia²

Department of Dermatology Venereology, Faculty of Medicine Universitas Sebelas Maret- Dr Moewardi Hospital, Surakarta, Indonesia³

Background

Background

Drug reaction related Eosinophilia Systemic Syndrome (DRESS Syndrome) presents as severe skin eruption, eosinophilia, fever, and internal organ damage. Cardiac involvement in DRESS Syndrome is quite rare.

Case Illustration

A forty-years-old male came to emergency department (ER) with fullbody rash and worsening itch after taking Cefadroxil 2 weeks before. We discovered wide, erythematous, maculopapular rash with areas of scaling on entire body. Both vital sign and chest x-ray were normal. Laboratory investigation showed leucocyte level of 41.600/ μ l with 24.7% of eosinophiles (normal 1-4%). Patient was diagnosed with probable DRESS Syndrome (RegiSCAR: 5) dd Steven-Jhonson Syndrome. He received with intravenous methylprednisolone and antihistamine as treatment. Patient was discharged with oral steroid provided. Two months later, patient had exertional dyspnea, fatigue, diaphoresis, and pleuritic chest pain for two weeks. He also felt palpitation 2 days before finally readmitted to ER. He had neither history of hypertension nor heart disease. All physical examination were normal, except for bibasilar crackles and heart rate of 200 bpm. The EKG showed SVT with aberrancy, accompanied by cardiomegaly and pulmonary edema on the chest x-ray. Laboratory test revealed elevated liver enzymes and normal troponin I level. The echocardiography revealed global hypokinetic with EF of 28% and TAPSE 9 mm. Although diltiazem successfully suppressed the heart rate, the dyspnea persisted, therefore furosemide was given a few more days, along with other drugs on heart failure regimnet. Patient was discharged after seven days with subsided symptoms. Eosinophilia-related cardiac toxicity was suggested for the mechanism of the acute heart failure. Further investigation using CMR should be done.

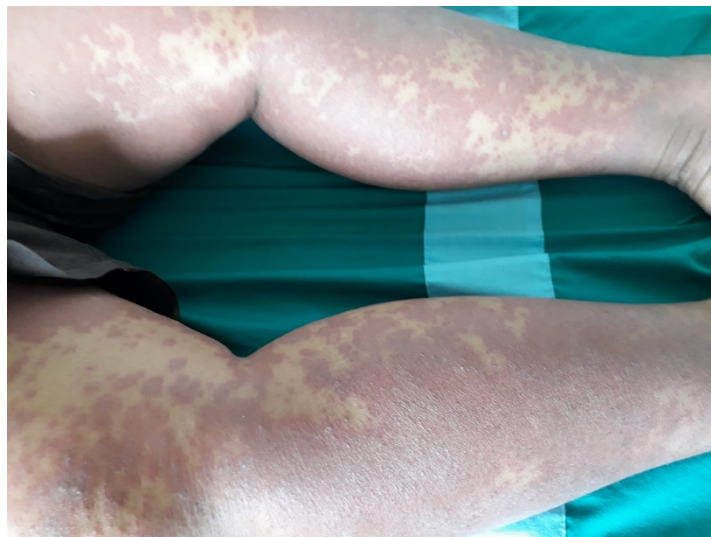
Conclusion


Cardiac complication of DRESS Syndrome are felt to be rare, but could also under-recognized and life-threatening.

Keywords

DRESS Syndrome, Heart Failure, Arrhythmia

Keywords: DRESS Syndrome, Heart Failure, Arrhythmia





High Bleeding Risk in Acute Coronary Syndrome: Stratification and Management

Background

In STEMI patients, bleeding considerably lengthens the stay in the intensive care unit and raises mortality. Morbidity and mortality in STEMI patients have been decreased by primary percutaneous coronary intervention (pPCI) and contemporary antithrombotic therapy. Nonetheless, bleeding issues may be linked to efficient treatment plans. Little literature exists on the risk of performing coronary intervention (PCI) on patients who have had recent gastrointestinal bleeding (GIB), although bleeding after PCI has been identified as a risk factor for long-term mortality.

Objective

To review and discuss the challenging treatment strategies in two patients with STEMI and concomitant bleeding event.

Case Illustration

First patient was 67-year-old female with inferior STEMI (14-h of onset) with concurrent of active GI bleeding, right ventricular infarction and TAVB (Total AV Block). He received inotropes, blood transfusions and PPIs to manage GI bleeding. PPCI was then carried out after stabilization of the patient. The Second patient was 64-year-old female with Antero-posterolateral STEMI with 4 hours onset, the patient underwent fibrinolytic successful therapy, the second day of treatment at CVCU the patient experienced GI bleeding, early routine PCI was delayed, treatment for GI bleeding was carried out, after the bleeding was resolved, the patient then underwent PCI with 2 DES implantation in LAD.

Discussion

Coronary intervention and dual anti-platelet medication for high risk acute coronary syndrome may increase the risk of bleeding despite the condition's life-threatening nature. In order to prevent Gastrointestinal bleeding, SAPT is advised in these circumstances, along with extra proton pump inhibitor therapy, therefore it was administered in both cases.

Conclusion

Both patients delayed PCI and were treated for GI bleeding and hemodynamic stabilization, the first patient had a malignant arrhythmia as a complication of ACS, while the second patient had revascularization successfully

Keywords : Acute Coronary Syndrome, Gastrointestinal Bleeding, STEMI

Myxoma and Its Complications: A Case Report

R.F.F. Rukman¹, H.W. Parlindungan²
Pematang Siantar Army Hospital¹

Department of Cardiology and Vascular Medicine, Pematang Siantar Army Hospital²

Background

Myxomas, a kind of cardiac tumor, may exhibit obstructive symptoms, yet many patients are asymptomatic at the time of diagnosis as the tumor may be identified incidentally on imaging studies. Myxomas could cause complications, such as potentially life-threatening thrombus, even cardiogenic shock when the tumor causes blockage.

Case Illustration

A 57 year old female patient was admitted to the ER with loss of consciousness. Found during physical exam, blood pressure of 60/40, heart rate of 132 bpm, 38.5 temperature, rhonchi in both lungs, diastolic murmur and edema in all limbs. The patient had a history of congestive heart failure, atrial fibrillation, type 2 diabetes, chronic kidney disease, and gangrene, with no familial history of heart disease. Electrocardiography showed AF with rapid ventricular response, and blood work result, anaemia of 6.1mg/dl. On norepinephrine, consciousness and vital signs showed improvement with 120/70 BP.

Hours after improved condition, the patient experienced altered mental status and drop in BP. Medicines used to combat the condition were norepinephrine, dobutamin, digoxin, furosemide, warfarin, spironolactone and bisoprolol. Echocardiography taken during previous hospitalization showed myxoma in the left atrium, size round 5x5cm located near the mitral valve with LA enlargement sized 5.82cm, and EF of 63.32%. The patient had previously been referred to a tertiary institution for surgery but the patient refused.

Conclusion

Myxomas most often originate from the left atrium and can obstruct the flow of blood in the heart depending on the location and the size of the tumor. Obstruction can cause low output symptoms and also lead to complications such as thromboembolism. Determining the correct diagnosis and earlier disease management ensure prevention for further complications, with echocardiography as a significant tool in the process.

Keywords: myxoma, atrial fibrillation, shock, thromboembolism

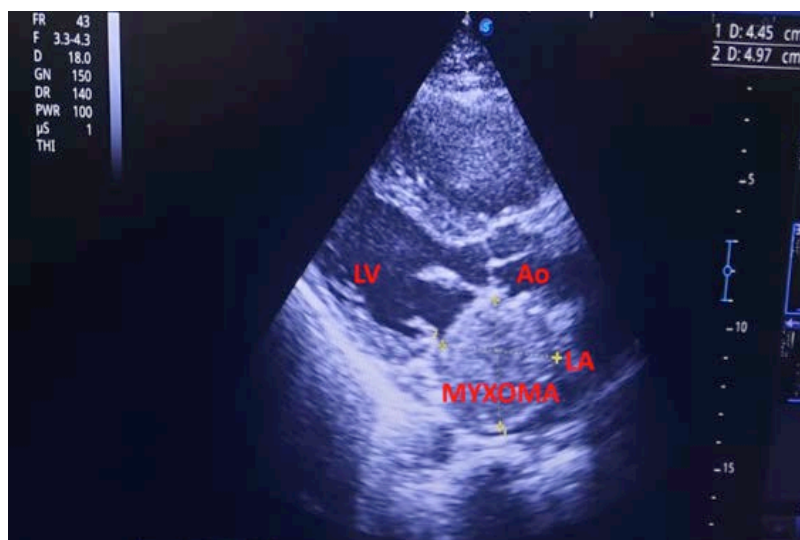


Figure 1. Echocardiography shows myxoma in the left atrium

Recognizing and Managing Frailty in Patients with Advanced Heart Failure

K.Triangto¹, B. Dwiputra², D.R. Desandri², A.M. Ambari², B. Radi², K.M.H.J. Tandayu¹
National Cardiovascular Center Harapan Kita, Jakarta, Indonesia¹
National Cardiovascular Center Harapan Kita²

Background: By the fact of the aging population in developing and developed countries, the prevalence of cardiovascular disease especially heart failure has dramatically increased causing morbidity, hospitalization and mortality in older people worldwide. Frailty, a biological syndrome that reflects a state of decreased physiological reserve and vulnerability to stressors, has become a high-priority theme in cardiovascular medicine due to aging and increasingly complex nature of cardiovascular patients. Up to 44.5% of HF patients were considered frail. Unfortunately, frailty is often unrecognized and many physicians are unaware of this condition

Case Illustration: Mr. RE, 59 yo, a former taekwondo athlete were consulted for cardiac rehabilitation therapy from outpatient clinic. He was diagnosed with CHF Fc II-III ec DCM (EF 12%, TAPSE 16), s/p ICD 2017, mod-severe MR ec functional, severe TR with high probability of PH, mild AR, T2DM, and renal insufficiency. He felt activity intolerance and fatigue, recently hospitalized for acute decompensation of heart failure. Initial 6MWT was 270 m (low) and we did the frailty assessments using FRAIL scale, SPPB, 5-m gait speed test, showing frailty in this patient. We planned supervised progressive exercise therapy and comprehensive cardiac rehabilitation, and after several visits, we could see dramatic improvement in 6MWT, SPPB, and quality of life.

Conclusion: Frailty is common in heart failure population. Heart failure and frailty are bidirectionally inter-related. Multiple assessment tools are available to assess frailty, FRAIL scale can be used to screen frailty and SPPB is one of practical assessment tools may be used to assess frailty. Exercise rehabilitation therapy is the cornerstone therapy of frailty, improving the functional capacity and quality of life of the patients.

Keyword: Heart failure; Frailty; Functional class; Cardiac rehabilitation; Quality of Life

Keywords:

Rehabilitation Visit	1	3	5	6	9	11	12	
Subjective	Fatigue						More fit, less fatigue	
Quality of Life (MLHF)	92/105						43/105	
FRAIL Scale	4/5						3/5	
SPPB	Balance	3						4
	Gait Speed	1						2
	Chair Stand	0						0*
	Total	4						6
Hand Grip	N/A						RA: 20.6 s	
5-m gait speed test	N/A						LA: 14.2 s	
CES-D	Positive						Negative	

Nb: *2 repeats in 30 sec, *5 repeats in 22 sec




Table Frailty and QoL assessments
Figures. The frailty assessment tools. (a) SPPB – balance; (b) SPPB – gait speed; (c) SPPB – chair stand; (d) Hand-grip assessment



Recurrent Ventricular Tachycardia from Myocardial Infarction Non-obstructive Coronary Artery : an unusual event

O. Sofyan¹, M. Amir¹, I. Mappangara¹
RSUP dr Wahidin Sudirohusodo¹

Background: Myocardial Infarction Non-obstructive Coronary Artery (MINOCA) is a new entity which is currently trend at interventional cardiology. Whereas cases of MINOCA may not need intervention treatment because of the absence of coronary artery occlusion. However, patient with MINOCA may have a worse prognosis if the condition is not appropriately managed, including recurrent ventricular tachycardia.

Case illustration: We reported a 55 year old male patient came to Emergency Room with typical severe precordial chest pain (VAS 8/10) accompanied with nausea within 2 hours and followed with palpitation. Upon admission, the HR was 200 bpm with wide QRS complex on monitor, initial defibrillation were prepared but then spontaneously convert to sinus rhythm. Initial blood sample shown increased hs-Troponin I. Surface ECG shown monomorphic ventricular tachycardia. Echocardiography findings showed mildly reduced LV & RV systolic function with EF 47.7%, and TAPSE 1.6 cm. Coronary angiography showed non-significant stenosis. On following days the patient was clinically deteriorating with recurrent ventricular tachycardia. Cardiac MRI showed positive late gadolinium enhancement at septal wall and confirmed microvascular obstruction. The antiarrhythmic agent was admitted, then electrophysiology study and ablation were performed with successful result.

Conclusion: MINOCA presenting as ventricular scars is sometimes fatal. Dramatic complication such as recurrent ventricular tachycardia leads this case to be more challenging. With guidance of cardiac MRI and ablation are important things to do with intensive optimal management strategy.

Keywords: Keywords : MINOCA, recurrent ventricular tachycardia.

Extremely Elevation of Troponin-I (cTnI) Values in Acute Myocardial Infarction Patients with Chronic Renal Failure

Y.W. Parhusip¹, M. Riski²

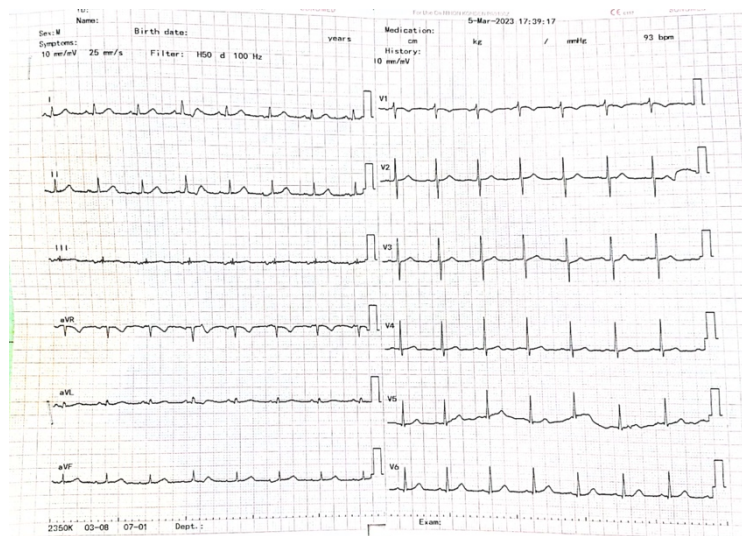
1. General Practitioner, Dr. Esnawan Antariksa Indonesian Air Force Hospital; Jakarta; Indonesia.
2. Department of Cardiology and Vascular Medicine, Dr. Esnawan Antariksa Indonesian Air Force Hospital; Jakarta; Indonesia.

Background: Coronary Heart Disease (CAD) is a multifactorial disease caused by atheromatous plaque deposition and progressive narrowing of the arteries, with the typical symptom of chest pain. The most frequently used diagnostic support for CAD besides electrocardiography (ECG) is Troponin I enzyme examination. In chronic kidney disease (CKD) case, the severity and prevalence of CAD increases 20 times compared to the normal population, due to the involvement of traditional risk factors (hypertension, smoking, diabetes mellitus, dyslipidemia, left ventricular hypertrophy, male sex), and uremia-related risk factors, which are often characterized by high Troponin I values.

Case Illustration: A 72 year old man came to the emergency department with complaints of left chest pain since the previous 4 days. Complaints of left chest pain that feels like a cut and gets worse with activity, usually get better with isosorbite. Since the last 10 years, the patient has a history of type II diabetes mellitus and impaired kidney function. Conscious awareness, blood pressure 90/61 mmHg, pulse 107 x/min, respiratory rate, 26 x/min, temperature 36 °C, oxygen saturation 99% and no abnormality was found on physical examination. Normal EKG examination, sinus rhythm, Troponin I > 15.5 ng/dl, urea 86 mg/dl and creatinine 1.8 mg/dl. Patient was diagnosed with NSTEMI with grade III CKD comorbidities. During treatment at the hospital, the patient received anti-platelet aggregation, anti-platelet and anticoagulant therapy. The results of serial ECG examinations on the 2nd and 3rd day of treatment showed anterior ischemia (inverted T) which returned to normal on the 5th day of treatment. This case report shows that not only due to infarction, but also exposure to high creatinine urea in the blood, causes increased damage to myocyte cells of the heart muscle in patients with CAD accompanied by CKD. Because the condition of uremia causes the Troponin I released gradually from myocyte cells. It is hoped that doctors will be more aware of the morbidity and mortality rates of patients who have cardiovascular disease accompanied by CKD.

Conclusion: The causes of damage to heart muscle myocyte cells can be caused by many factors. However, CAD patients accompanied by CKD, myocyte damage to heart muscle cells is also caused by exposure to high uremia conditions in the blood. Careful analysis of clinical data and laboratory findings can help to correctly diagnose and treat patients appropriately.

Keywords: Keywords: coronary artery disease, Troponin I (cTnI), chronic kidney disease (CKD).



PCI with DES and DCB for Treatment of Mixed In-Stent Restenosis and De Novo Stenosis: Case Report

D.A.K. Purba¹, A. Sitepu²

Faculty of Medicine, Universitas Sumatera Utara, Medan, Indonesia¹

Department of Cardiology and Vascular Medicine, Faculty of Medicine, Universitas Sumatera Utara, Medan, Indonesia²

Background: In-Stent Restenosis (ISR) is the re-narrowing condition of stented artery segment in around 20% of Percutaneous Coronary Intervention (PCI) patients. ISR significantly increases the risk of death, poorer outcomes, and Major Adverse Cardiovascular Events (MACE), which is challenging in daily practice.

Case Illustration: A 76-year-old man came with a clinical manifestation of Unstable Angina Pectoris. He had a history of hypertension and diabetes mellitus and had one stent placed in Left Anterior Descending Artery (LAD) 18 years ago. Through coronary angiography examination, there appears to be a Mixed ISR and De Novo Stenosis in LAD. Then an Intravascular Ultrasound (IVUS) examination was carried out with the results of fibrous plaque, stent under-expansion, and neo-atherosclerosis. Aggressive pre-dilation with Raiden non-compliant (NC) balloon 3,0x15mm-22 atm, cutting balloon Wolverine 3,5x25mm-14 atm and Ikazuchi 3,0x10mm-12 atm were performed before DCB Sequent Please 3,5x25mm-10 atm installed at the under-expansion and neo-atherosclerosis area. For de novo stenosis, DES Xience Xpedition 3,5x33mm-14 atm was utilized. The final results showed that LAD developed entirely with Minimal Stent Areas (MSA) 11,83 mm² in the ostial LAD and 7,52 mm² in the neo-atherosclerotic area.

Conclusion: DEB and DES are comparable and provide excellent clinical outcomes for ISR.

Keywords: In-Stent Restenosis, Percutaneous Coronary Intervention, Drug-eluting Stent, Drug-coated balloon, Coronary Artery Revascularization

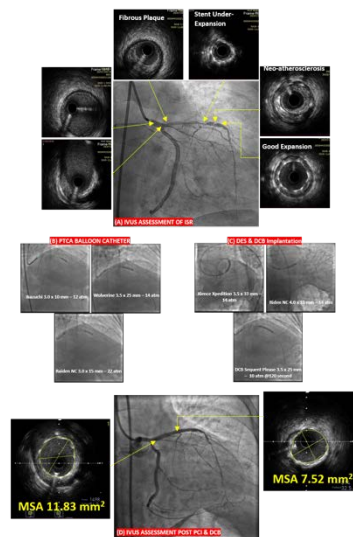


Figure 1. (A) IVUS Assessment of ISR; (B) PTCA Balloon Catheter; (C) DES & DCB Implantation; (D) IVUS Assessment Post PCI & DCB

Brugada Syndrome Induced By Fever In Pericarditis Tuberculosis Patient: A Case Report

D. Amelia¹, T. Erlanggawati², W.N. Hamdani³, E. Zuhri⁴
Kanujoso Djatiwibowo General Hospital, East Kalimantan, Indonesia¹
Panglima Sebaya General Hospital, East Kalimantan, Indonesia²
Abdul Wahab Sjahrani, East Kalimantan, Indonesia³
Teluk Bintuni General Hospital, West Papua, Indonesia⁴

Background: Brugada syndrome (BrS) is defined as rare autosomal-dominant inherited disorder that might lead to sudden cardiac death. One of the triggers for this syndrome is fever.

Case illustration: A 25-year-old man was admitted to the emergency department with complaints of chest pain and fever, with history of frequent syncope. There was a family history of sudden death on young age. During physical examination, patient had tachycardia and fever, and friction rub and decreased breath sound on left lung on auscultation. ECG showed coved-type ST-segment elevation with negative T wave in V1-V2 lead. Chest x-ray demonstrated minimal left pleural effusion, which proven to be granulomatous tuberculosis. Echocardiography revealed mild pericardial effusion. Patient was given daily maintenance IV fluid, anti pyretic, colchicine, antibiotic, and tuberculosis drug regimen. Fever is one of the triggers for Brugada Syndrome, but the pathophysiology is still not clear. There are some theories saying fever caused prematurely shorter period of action potential, accelerated inactivation of I_{Na} channels, decreased level of sodium channels expression, and the loss of sodium channel function.

Conclusion: Patient fulfilled the diagnosis criteria for Brugada Syndrome which is induced by fever caused by tuberculous pericarditis. As a clinician, we should be more aware about the possibility of this syndrome in patients with history of fever and syncope.

Keywords: Brugada Syndrome, Fever, Sudden Death

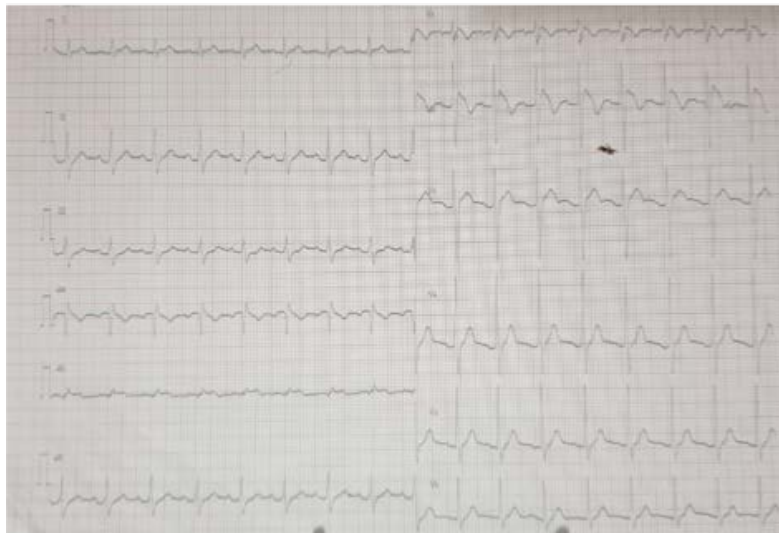


Figure 1. Patient's electrocardiogram at the time of admission in emergency department (Body's temperature 39,9 Celsius)

Successful Percutaneous Balloon Mitral Valvuloplasty in a Case of Natural History of Rheumatic Mitral Valvular Stenosis

R.A. Rizki¹, C.K. Krevani², W. Valerian¹, S.I. Herman¹
Andalas University¹
RSUP dr. M. Djamil Padang²

Background: Rheumatic Heart Disease (RHD) is a damage of the heart valve due to Acute Rheumatic Fever (ARF) which results from the body's autoimmune response to Streptococcal infection. ARF is one of the most important causes of Mitral Stenosis (MS) in developing countries.

Case illustration: A 41 years old woman came to the outpatient clinic with shortness of breath, fatigue, and ankle swollen. Symptoms had been felt since 3 days ago and worsened. The patient had a medical history of ARF at the age of childhood and was treated with antibiotic for 5 years, which developed into RHD with MS at the age of adult and routinely given medication of diuretics, beta blocker, and digitalis by cardiologist. The haemodynamic was stable. Chest examination found opening snap and mid-diastolic murmur at apex grade 2/4 did not spread to axilla and no gallop. Her extremities were warm with ankle swollen. An electrocardiogram showed no specific present. The results of blood laboratory have no specific present. Chest X-Ray showed cardiomegaly. Echocardiographic before admission found MS severe with Mitral Valve Area (MVA) 0.9 cm² ec RHD with Wilkins Score 8, and no thrombus found. Due to MS NYHA fc III ec RHD with Wilkins Score 8, we decided to do Percutaneous Balloon Mitral Valvuloplasty (BMV). Post BMV evaluation, the echocardiography showed an enlargement of MVA from 0.9 cm² to 1.2 cm², which was a success procedure. The next day after the procedure, the symptoms were reduced and planned to discharge with medication.

Conclusion: Rheumatic MS is a disease that progressive, usually with a latent phase of 20-40 years from the initial ARF to the development of symptoms. Symptoms gradually increase in severity over several years. Percutaneous or surgical intervention is the definitive treatment for relief MS.

Keywords: Mitral Stenosis, Rheumatoid Heart Disease, Percutaneous Balloon Mitral Valvuloplasty

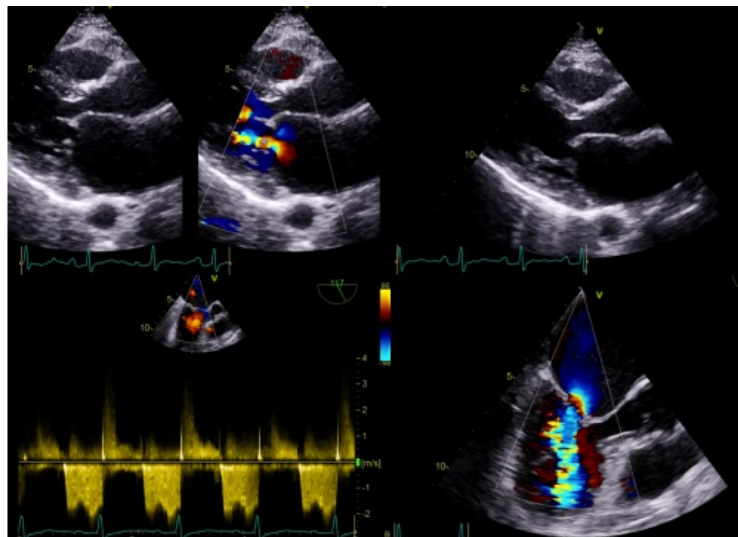



Fig. 1 Echocardiographic Findings

Complete Heart Block in Multigravida Inpartu Patient : One of the pacing tools options for intraoperative sectio caesarian setting

A.F. Abadi¹, M. Amir², A.I. Taim¹
Faculty of Medicine, Hasanuddin University, Makassar, Indonesia¹
Cardiac Center Wahidin Sudirohusodo, Makassar, Indonesia²




Background: The prevalence of bradyarrhythmia in women of reproductive age is 1/20,000 and a significant majority are diagnosed prior to pregnancy. Initial diagnosis in pregnancy requires specific approach. Management of a pregnant woman with complete heart block presenting with parturient and without pacing is challenging. Transcutaneous cardiac pacing offers several advantages when compared to the placement of a transvenous cardiac pacemaker in the emergency setting.

Case illustration: We report a case of successful management of a 23-year-old, pregnant woman with complete heart block who had an emergency caesarean delivery under spinal anesthesia. She was an unbooked patient detected with complete heart block during active stage of labour. An emergency transcutaneous cardiac pacing was used during surgical procedure under the supervision of cardiologist, anesthesiologist, and obstetrician. Emergency caesarean procedure was uneventful with uncompromised hemodynamic status. The transcutaneous cardiac pacing was removed shortly after surgery and the patient was scheduled for permanent pacemaker implantation.

Conclusion: Medical emergency has its own challenge for the management principles and implementation especially in pregnant woman. Known complete atrioventricular block patients with pregnancy should always be counselled and worked up for permanent pacemakers. However, temporary pacemaker is needed in emergency settings. Transcutaneous cardiac pacing is an ideal early and temporary intervention for patients requiring stabilizing cardiac pacing support until more invasive procedures can be arranged in the proper clinical setting.

Keywords: Transcutaneous cardiac pacing, complete heart block, pregnancy, emergency caesarean section



Pulmonary Embolism Masquerading as Pneumonia: A Case Series

G.P. Hapsari¹, E.A.D Batubara¹, L. Widiyanto¹, D.R. Fauzan¹, K.A. Nugraha², R.U. Setiani², Haryadi², Yulianto², I.A. Siregar²

Cardiology Resident, Department of Cardiology and Vascular Medicine, Faculty of Medicine University of Indonesia / National Cardiovascular Center Harapan Kita¹

Cardiologist, Department of Cardiology and Vascular Medicine, Navy Hospital Mintohardjo, Jakarta, Indonesia²

Background:

Pulmonary Embolism (PE) is often hard to distinguish because it shares similar clinical features with pneumonia. This case series aims to show the importance of comprehensive evaluation for PE mimicking pneumonia which is frequently overlooked.

Case Illustration:

A 55-year-old male presented with fever and sharp chest pain. Physical examination revealed high BP, tachycardia and desaturation. ECG showed sinus tachycardia. CXR showed pneumonia with pleural effusion. He was treated as pneumonia and antibiotics was administered but did not show significant improvement. Echocardiography evaluation showed dilated MPA with hazy appearance suspected as thrombus. clinical DVT was not found. Laboratory evaluation revealed normal troponin dan increased D-dimer level. CT Pulmonary Angioram (CTPA) then was planned but hemodynamic was unstable. He was diagnosed with acute PE. Optimal dose of heparin was given, unfortunately the patient did not survive. Second case, a 33-year-old obese male with medical history of Covid-19 and arthroscopy complained of dyspnea and pleuritic chest pain. Physical examination revealed high BP, tachycardia and desaturation. CXR showed bilateral pleural effusion and pneumonia. He was treated for pneumonia and an antibiotic was given but was not improved clinically. Initial echocardiography revealed normal findings. During treatment, he was clinically deteriorating. Laboratory evaluation revealed normal troponin dan increased D-dimer level. ECG evaluation showed S1Q3T3 pattern. Repeated echocardiography evaluation showed RA thrombus, dilatation of RV, MPA, LPA, RPA, with positive Mc-Connell Sign. He has absence of clinical DVT. CTPA confirmed thrombus PA. The patient then was treated as an acute PE with a fondaparinux but did not survive.

Conclusion:

PE should be considered as the differential diagnosis in patients who are deteriorating even with optimal pneumonia treatment and no risk factors of PE. As these cases have a lethal condition, a comprehensive evaluation is necessary to prompt diagnosis of PE mimicking pneumonia to reduce mortality by appropriate treatment. CTPA are essential diagnostic tools to confirm the diagnosis.

Keywords:

Percutaneous Transluminal Angioplasty for Total Occlusion of Subclavian Artery with Clinically Manifested Subclavian Steal Syndrome

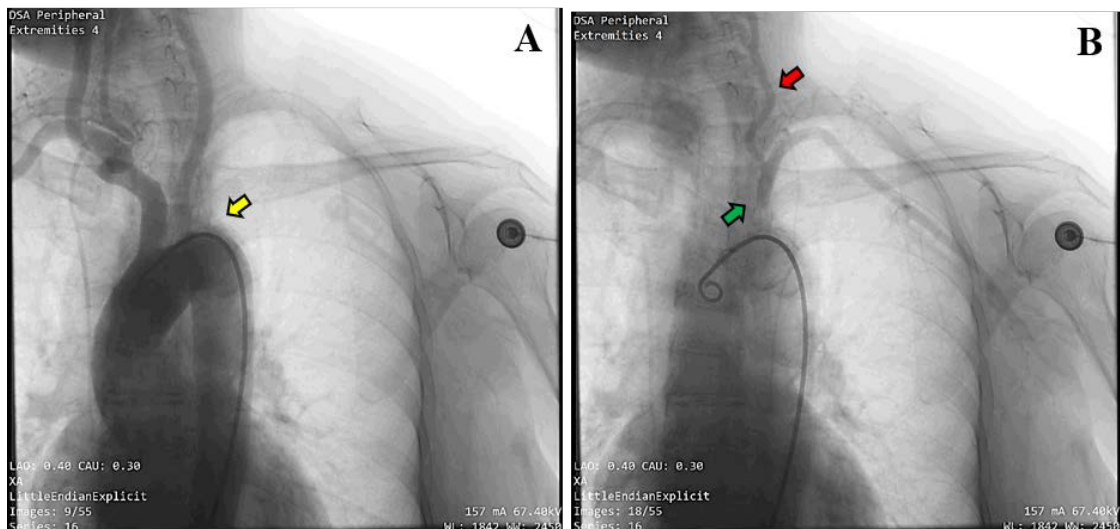
H.O. Hermawan¹, P.D.K. Devi¹, P.M.H. Putri¹, A. Halim¹, R.M. Budiarto¹
Universitas Airlangga / RSUD Dr. Soetomo¹


Background: Subclavian steal syndrome (SSS) refers to a phenomenon of flow reversal from the vertebral artery to the subclavian artery due to hemodynamically significant lesion of the proximal subclavian artery. SSS can manifest in some patients related to circulation insufficiency to the central nervous system and/or upper extremities. The presence SSS is associated with increased total mortality and cardiovascular disease mortality. Percutaneous transluminal angioplasty is a minimally invasive strategy with a high success rate in managing SSS.

Case Illustration: A 72 years old female comes with left arm claudication, aggravated with moderate activities. Physical examination showed a discrepancy of 51 mmHg in blood pressure taken in both upper extremities. Duplex ultrasonography revealed a caudalad/retrograde flow at the left vertebral artery and monophasic morphology at the left axillary, brachialis, ulnar, and radial arteries without significant plaque/thrombus along arteries. Catheter-based angiography confirmed total occlusion at the left proximal subclavian artery (Figure 1). The patient underwent percutaneous transluminal angioplasty with marked flow improvement at the left subclavian, vertebral, and internal mammary arteries. Re-evaluation of duplex ultrasonography showed cephalad/antegrade flow at the left vertebral artery.

Conclusion: Subclavian steal syndrome is related to arterial insufficiency in a branch of the subclavian artery due to stenosis at the proximal subclavian artery. Subclavian stenosis should be considered in any patient with arm claudication with a discrepancy of > 15 mmHg in blood pressure taken in both upper extremities, as well as judicious use of duplex ultrasonography and angiography can determine the need for invasive strategy. Percutaneous transluminal angioplasty has a high success rate with marked clinical improvement.

Keywords: Subclavian steal syndrome, subclavian stenosis, percutaneous transluminal angioplasty





DIAGNOSTIC APPROACH BY SPECKLE TRACKING ECHOCARDIOGRAPHY IN CARDIAC AMYLOIDOSIS : A CASE REPORT

W.E. Putri¹, A.F. Ghaznawie¹, A.F. Muzakkir¹


Department of Cardiology and Vascular Medicine, Faculty of Medicine, Hasanuddin University/ Dr. Wahidin Sudirohusodo Hospital, Makassar, Indonesia¹

Background: Cardiac amyloidosis (CA) is a form of infiltrative cardiomyopathy due to deposition of amyloid fibrils in the myocardium. Amyloid fibril infiltration impairs myocardial function, often with a normal appearing Left Ventricle ejection fraction (LVEF). Two-dimensional speckle-tracking (STE) imaging is used to measure myocardial deformation and is proven to be useful in the case of cardiac amyloidosis.

Case Illustration: We report the case of a 55-years-old female referred to our Hospital with progressive shortness of breath and lower extremity oedema. The electrocardiogram showed: sinus rhythm of 85 bpm, LVH with low-voltage criteria. Chest radiography proved lung edema and cardiomegaly. Laboratory analysis showed mild hyponatremia (130). Echocardiography showed: increased left ventricular (LV) and right ventricular (RV) wall thickening, biatrial enlargement with increased atrial septal thickness, grade II diastolic dysfunction with elevated LV filling pressures, severely reduced mitral annular tissue doppler velocities, pericardial effusion, diffuse valve thickening and a preserved ejection fraction with low stroke volume index. Based on her basic echocardiographic, cardiac amyloidosis was strongly suspected. LV longitudinal strain obtained by STE, showed a reduced global longitudinal strain with apical sparing. A Cardiac MRI was planned but due to the patient's intolerance of lying for long durations, the examination was not completed. GLS is a unitless measure of longitudinal deformation with more negative values denoting greater deformation. When it is abnormal, it reflects contractile dysfunction. Abnormal GLS in the mid and basal walls of the LV with normal values in the apex, when plotted on a bull's-eye map, known as the apical sparing pattern (or "cherry on top" pattern), is 93% sensitive and 82% specific in identifying patients with CA.

Conclusion: This case underlines the importance of non-invasive diagnostic techniques such as STE for Cardiac Amyloidosis's early diagnosis, especially when CMR cannot be performed.

Keywords: Cardiac Amyloidosis, Speckle Tracking, Echocardiography



DIABETIC CARDIOMYOPATHY IN 42 YEAR-OLD WOMAN MIMICKING ACUTE CORONARY SYNDROME

A. Surya¹, A.F. Muzakkir¹

Department of Cardiology and Vascular Medicine
Faculty of Medicine, University of Hasanuddin Makassar.¹

Background :

Diabetic cardiomyopathy is defined as changes in myocardial structure and function in diabetic patients, in the absence of other cardiovascular risks such as ischemic hypertension, or significant valvular disease.

Case illustration :

A 42 year-old woman came to the hospital with chief complaints of substernal chest pain radiating to the back accompanied by cold sweat. Patient also experienced shortness of breath that has worsened since a day ago. ECG showed sinus rhythm with HR 100 bpm, normal heart axis (-10 degrees), poor R wave but no ST segment or T wave changes. Laboratory findings showed no increase in Hs Trop I and HbA1C was 10.8%. Chest x-ray displayed cardiomegaly. Coronary angiography did not show any significant stenosis. Cardiac *Magnetic Resonance Imaging* (CMR) was performed and EF was 33%. T1 *mapping* with a value of 1413 ± 338 , $R^2 = 0.996$, showing a positive *Late Gadolinium Enhancement* (LGE) indicating the presence of fibrosis or infarction of the myocardium, with overall conclusions of early cardiomyopathy, left ventricle enlargement, and abnormal LV systolic function.

Conclusions :

Diabetic cardiomyopathy is a complication occur in patients with a history of diabetes mellitus. Diabetes mellitus mainly cause hyperglycemia, systemic insulin resistance, and impaired insulin metabolic signaling in the cardiac that induce dysfunction of ventricular contractility and finally result in heart failure or cardiomyopathy. The clinical symptoms of this patient resembling acute coronary syndrome, but from the examinations no significant signs of acute coronary syndrome were found. CMR was the choice of examination despite the limited use in daily practice.

Keywords: Diabetic cardiomyopathy, acute coronary syndrome, diabetic mellitus



Rare Case Ruptured Sinus Valsava in Adolescence with Doubly Committed Subarterial Ventricular Septal Defect and Infective Endocarditis

L. Setiadi¹, I. Sakidjan¹

¹Department of Cardiology and Vascular Medicine, Universitas Indonesia/National Heart Center Harapan Kita, Jakarta, Indonesia

Background:

Ruptured Sinus Valsava is a rare disorder, with incidence ranging from 0.1 to 3.5% of all congenital heart diseases, occurring between the ages of 20-40 years. Ruptured sinus valsava can be congenital or acquired as a result of a ventricular septal defect, endocarditis, or chest trauma. The occurrence of VSD and concurrent endocarditis infection can hasten sinus valsava rupture.

Case Illustration:


15-year-old girl present with fever for one month prior to admission to the hospital, and are known to have congenital heart disease since the age of nine, with no prior symptoms. From the physical examination revealed signs of heart failure symptoms such as increased JVP, rales in bilateral pulmonary basal, and to-and-fro murmur on the left sternal border. On the ECG and x-ray of the thorax revealed left ventricular hypertrophy. Echocardiography reveals ruptured of sinus valsava, VSD SADC, aortic regurgitation and vegetation. A typical infectious endocarditis bacteria, streptococcus mitis / streptococcus oralis, was discovered in the blood culture examination. The patient was then given antibiotics based on the IE bacteria, as well as surgery to repair the valsava sinus rupture, close the VSD, repair the aortic valve, and evacuate the vegetation.

Conclusion:

There have been reported case of 15-year-olds with ruptured sinus valsava, in VSD SADC, and Infective Endocarditis. Both, can result in a faster occurrence of complications, such as ruptured of the valsava sinus. Monitoring and early management of patients with VSD SADC, and aortic regurgitation should be more strictly enforced in order to prevent severe complications or increase morbidity and mortality in patients.

Keywords:

Ruptured sinus valsava, VSD SADC, Infective Endocarditis



Role Of Echocardiography In The Diagnosis Of Cardiac Amyloidosis

I. Setiadi¹, E. Rudiktyo¹

¹ Department of Cardiology and Vascular Medicine, Universitas Indonesia/National Heart Center Harapan Kita, Jakarta, Indonesia

Background:

Amyloidosis is a rare group of protein-misfolding illnesses that usually affect the heart due to the deposition of amyloid fibrils. Cardiac Amyloidosis (CA) has a low survival rate, limited access to diagnostic modalities (endomyocardial biopsy, CMR, or Bone scintigraphy), and is often underdiagnosed. Echocardiography plays a major role in the non-invasive evaluation of CA. Boldrini et al, introduced a diagnostic algorithm using an echo parameter called increased wall thickness (IWT Score) which has high specificity in diagnosing CA

Case Illustration:

First patient was 54-year-old male presented to the clinic due to shortness of breath, during activity and ascites. Initial clinical workup revealed ascites, elevated JVP, low voltage ECG tracing, and highly elevated NT Pro BNP. Echocardiography revealed right and left ventricular hypertrophy, sparkling granulation, average GLS -4,7%, ejection fraction strain rate of 8.3, and apical sparing pattern, with an IWT score of 10, which has a specificity of 98%. Second patient was 54-year-old male presented to the outpatient clinic due to a chief complaint of shortness of breath, during activity and bilateral peripheral edema. Initial clinical workup revealed bilateral peripheral edema, elevated JVP, low voltage ECG tracing, and highly elevated NT Pro BNP. Echocardiography revealed right and left ventricular hypertrophy, average GLS -6,1% with ejection fraction strain rate of 3.4 and apical sparing pattern, with an IWT score of 10, which has a specificity of 98%. CMR imaging revealed global transmural late gadolinium enhancement suggestive ATTR Cardiac Amyloidosis.

Conclusion:

The use of echocardiography and IWT diagnostic scoring can show high specificity in diagnosing CA, avoid unnecessary tests, and limit the time to diagnose CA

Keywords: Echocardiography, Diagnosis, Cardiac Amyloidosis, IWT Score

Subvalvular Aortic Stenosis Caused By Structural Abnormality Subaortic Membrane

A.I.S Putra¹, N.M.A.W Sari², L.O.S. Suastika², I.B.R. Wibhuti²

¹Residence at Faculty of Medicine Udayana University/Prof. dr Ngoerah Hospital, Denpasar,

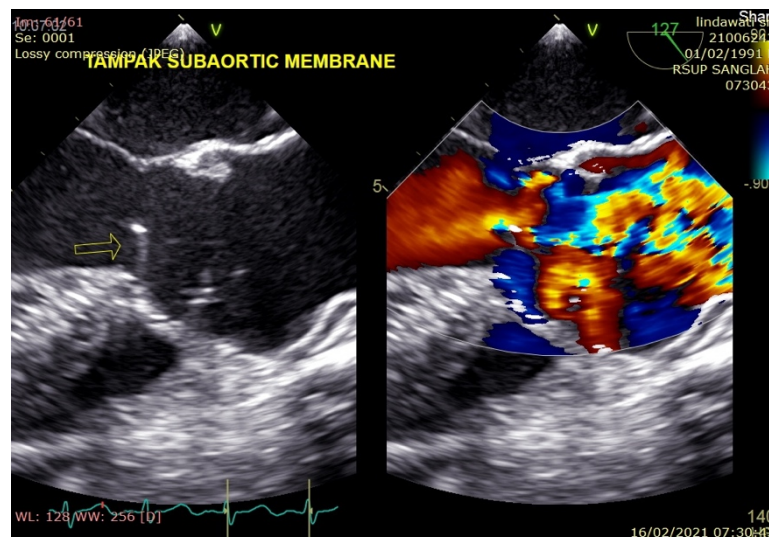
²Faculty of Medicine Udayana University/Prof. dr Ngoerah Hospital, Denpasar, Indonesia, Echocardiography Division


Background : Diagnosis and management of aortic valve abnormalities are still challenging in the field of cardiology, especially in some cases such as congenital aortic abnormalities. Subaortic membrane causing subvalvular stenosis and LVOT obstruction may impair person's quality of life. This case report fully discusses the challenging diagnosis to appropriate treatment of this population.

Case Illustration : A 30-year-old female referred to central referral hospital for TEE procedure for definite diagnosis. The patient was consulted to cardiology for cardiac clearance for thyroid open biopsy procedure. Patient with unremarkable physical examination except diastolic murmur at left sternal border was noted. TTE confirmed the moderate aortic regurgitation with suspected bicuspid valve. Due to unclear structural and aortic mechanism from TTE, patient then conducted TEE. Specific findings of the aortic valve showed 3 cusps, short LCC structure causing moderate AR with an eccentric jet. A protruding structure seen at the LVOT (subaortic membrane) causing LVOT obstruction with moderate aortic stenosis (AV Vmax 3.44 m/s, AV meanPG 22.8 mmHg, AV maxPG 44.7 mmHg). Thus, the patient was diagnosed with rare subvalvular aortic stenosis caused by structural abnormality subaortic membrane. According to the guideline, specific treatment does not required for this patient, unless the severity of the abnormal valve increases upon observation. Resection of the sub-aortic obstruction, concomitant repair of the aortic valve, can ideally delay or prevent surgical aortic valve replacement.

Conclusion: This case demonstrated the challenging diagnosis of patient with rare structural abnormality of the aorta. Patient with subvalvular aortic stenosis caused by subaortic membrane. TTE showed good result for early diagnosis, however TEE shown to be effective in diagnosing such patient. Treatment of choice was based on clinical presentation, abnormal valvular severity and team discussion would be useful for the patient

Keywords: Subvalvular Aortic Stenosis, Subaortic Membrane, Transesophageal Echocardiography





Subsequent Pregnancy in Previously Diagnosed Peripartum Cardiomyopathy: A Case-Series

P. Arianeu¹, T.I. Dewi², M. Hasan², H.S. Prameswari²
General Practitioner, Hasan Sadikin General Hospital, Bandung, Indonesia¹
Cardiologist, Hasan Sadikin General Hospital, Bandung, Indonesia²

Background

Peripartum cardiomyopathy (PPCM) is a cardiomyopathy related to pregnancy. Patient with previously diagnosed PPCM has a risk of relapse during subsequent pregnancy (SSP), especially those with persistent LV dysfunction. There is limited data regarding SSP. Thus the aim of this study is to describe the pattern of presentation, course of disease and outcome of SSP.

Case illustration

A prospective study of fourteen cases of SSP in PPCM patients was conducted at Hasan Sadikin General Hospital Bandung from January 2015 to January 2023. Age distribution, symptoms, risk factors, medical management and pregnancy outcome were documented. Echocardiography was obtained before, at onset of SSP, during SSP, and after delivery. In this study 3/14 (21%) classified as NYHA II. Pre-eclampsia occurs in 1/14 (7%), and 1/14 (7%) had co-existing hypertension. Five unplanned pregnancies (35%) occurred in women with persistent LV dysfunction. One of the 5 patients experienced worsening of the symptoms, dyspnea and peripheral edema, and also decreased LVEF >5%. Nine well planned pregnancies (65%) had improved LV function (LVEF >50%). Out of the 9 patients, none experienced worsening of the symptoms, and 1 patient experienced reduce LVEF >5%. All patients gave birth to live children, two of them were born prematurely and one was intrauterine growth restriction (IUGR). Ten out of fourteen patients were followed up for a period of one year out of which 30% (3/10) patients have not fully recovered. There was no maternal mortality and rehospitalisation during follow up.

Conclusion

The impact of SSP on cardiac function vary one to another. Low LVEF prior to SSP can lead to deterioration of symptoms and LVEF during pregnancy. Counseling should be given prior to SSP and close monitoring throughout the pregnancy is a necessity

Keywords: Subsequent pregnancy, Peripartum Cardiomyopathy, Heart failure

Background:

Organ injury is commonly present in patients with heart failure due to organ hypoperfusion. Ischemic gastritis is a rare disease with poor prognosis in patients with hemodynamic disruption. Low output state and repeated episodes of hypotension, can lead to organ perfusion impairment, one of them occurs in the gaster which is rarely reported. We present a case report of ischemic gastritis in a patient with heart failure reduced ejection fraction (HFrEF).

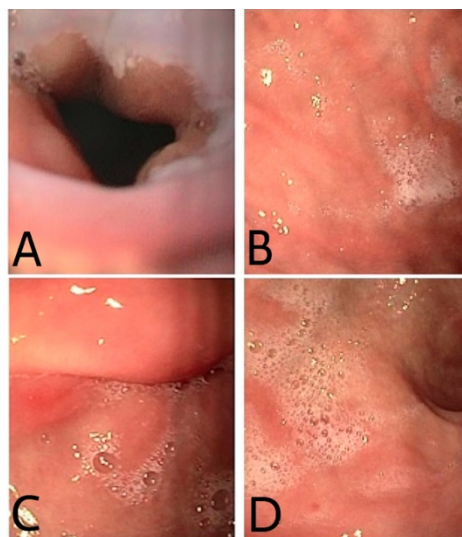
Case illustration:

A 56-year-old-male came to the ER with major complaint of nausea, vomiting after every time he eats, and epigastric pain since 3 days ago with a history of chronic epigastric pain for the last 4 years. The pain was sharp and non-radiating. No chest pain, palpitations, nor dyspnea. He has history of CAD with 2 stents at LAD, CHF, and AF NVR. Blood pressure was 87/49 mmHg and heart rate was 60 bpm irregular. ECG showed AF NVR, LBBB, and prolonged QTc (605 ms). Physical examination revealed soft, non-distended abdomen with epigastric pain. Laboratory studies showed Hemoglobin 15.8, Creatinine 3.08, NT-pro-BNP 2678, and Kalium 2.6. Left ventricular ejection fraction was 24%. He underwent gastroscopy and had several episodes of hypotension during the procedure that required 1000ml total of fluid resuscitation. Gastroscopy showed mucosal break at the distal esophagus, pale inflamed gastric mucosa with multiple erosions at the corpus and antrum. Biopsy was concluded as chronic active gastritis. He was given aggressive PPI therapy and gastric mucosa protector.


Conclusion :

Patients with HFrEF, repeated episodes of hypotension, history of CAD and AF could experience ischemic gastritis due to chronic gastric hypoperfusion. Early diagnosis with gastroscopy and aggressive therapy is required to increase survival by preventing the development of hematemesis or gaster necrosis. Heart failure treatment also plays an important role in improving patient's outcome.

Keywords: Heart failure reduced ejection fraction, ischemia gastritis, hypoperfusion



Gastroscopy showed mucosal break at the distal esophagus (A), pale inflamed gastric mucosa with multiple erosions at the corpus (B, C) and antrum (D).



CARDIORENAL SYNDROME (CRS) TYPE-5 IN SYSTEMIC LUPUS ERYTHEMATOSUS (SLE): A RARE CASE REPORT

G.S. Ambara¹, K.S.S Darma²

¹Department of Cardiology and Vascular Medicine, Faculty of Medicine Udayana University, RSUP Prof. dr. I. G. N. G. Ngoerah, Denpasar, Indonesia¹

²Department of Cardiology and Vascular Medicine, Faculty of Medicine Udayana University, RSUP Prof. dr. I. G. N. G. Ngoerah, Denpasar, Indonesia²

Background

Cardiorenal syndrome (CRS) is a dysfunction of heart and kidney that occur simultaneously and overlap, develops into a vicious cycle in the form of a decrease in interrelated and lethal function in both organs.

Case Illustration

A 20-year-old female, complained shortness of breath since 3 days and getting worse since 1 day ago. She also complained of swelling in both legs since 1 month. The patient has a history of SLE since 1.5 years. Physical examination: BP 90/60 mmHg, pulse 100 x/min regular, JVP neck PR+5 cmH₂O, rhonchi +++/---, all four extremities cold, edema +/-/-. EKG: sinus rhythm, HR 99x/min, LAD axis, P wave normal, PR interval 160 ms, QRS complex <0.12 sec, R/S ratio in V1 <1, RV5+SV1 >35 mm and T-inversion non-specific at II, III, aVF, with an effect of SR, 99 bpm, LVH. Laboratory examination: HGB 8.35, BUN 34.3, SC 1.34, eGFR 55.88, Procalcitonin 58.96, pH 6.94, pCO₂ 77.4, HCO₃- 16.40. UL results: leukocytes 2+, nitrites (-), ketones (-), protein (2+), sedimentary leukocytes 48, bacteria ++. The patient was diagnosed with ADHF Profile C ec SLE related cardiomyopathy, cardiogenic shock, EF 40%, ACKD ec pre-renal on CKD suspect lupus nephritis, cardiorenal suspect type-5(CRS type-5)?, and severe metabolic acidosis(6.94). The patient was admitted to the ICCU.


Discussion

CRS-type 5's risk factors include sepsis, vasculitis and systemic conditions (SLE, amyloidosis and obesity) lead to cardiac and renal dysfunction. CRS type-5 mechanism include systemic inflammation, increased central venous pressure (CVP), activation of the renin-angiotensin-aldosterone system (RAAS), sympathetic neurohormonal system (SNS), oxidative stress, dysfunction vascular endothelium lead to cardiac and renal fibrosis resulting cardiac and renal insufficiency.

Conclusion

CRS type-5 is a complex condition that includes broad systemic disorders which there is progressive concomitant and overlapping cardiac and renal dysfunction that can result from systemic conditions such as SLE.

Keywords: CRS, SLE, heart dysfunction, kidney dysfunction



Not Every ST Elevation is a STEMI: Tachycardia induced ST Elevation in a Post-STEMI Patient

R. Ayuningtyas¹, A. Ciptasari¹, S. Inayasari¹, A. Novitasari¹, N.A. Novembri¹, W. Pamungkas², M.G. Suwandi¹,
L. Pribadi¹, A. Muthmaina¹
Rumah Sakit Pusat Angkatan Udara Suhardi Hardjolutukito, Bantul, Indonesia¹
Adisutjipto Air Force Base, Bantul, Indonesia²

Background

ST elevation in an ECG is most often attributable to an episode of STEMI. Nevertheless, we should consider other possibilities which can evoke this ECG finding.

Case Illustration

A 62-year-old man presented to emergency department with chest discomfort and palpitation. He had a history of CHF CF II ec IHD/HHD presenting with inferior posterior lateral STEMI Killip II onset 3 hours seven days ago. He was referred to a bigger hospital to undergo primary coronary intervention. His coroangiography showed 80% occlusion in mid LAD, hence 1 DES was implanted in LAD. During his hospitalization, his ECG was back to baseline. He was discharged after sevendays, six hours before his second attack.

Six hours after discharge, he came back to our ER with the same presentation. He was compos mentis with irregular heart rate of 178 bpm, tachypnea with oxygen saturation 98% using NRM 10 lpm. His blood pressure was normal. His ECG showed lateral STEMI with atrial fibrillation with rapid ventricular response. The patient was assessed with Reinfarction of lateral STEMI Killip II onset 1-2 hours, AFRVR, CHF CF II (Low EF) ec IHD/HHD. He was then referred again for further investigations. At the referral hospital, he was given Metoprolol for rate control. His pulse slowed down and during so, his ST segment came back to baseline.

Conclusion

When faced with ECG findings of ST elevation and AFRVR, moreover there's a history of CAD/IVD not long before, the first diagnosis comes to mind must be a reinfarction. But before hastily make the decision, we should eliminate another differential diagnosis that can mimic those of STEMI reinfarction. The process leading to the diagnosis of STEMI relies on integration of multiple clinical, laboratory and ECG findings, assessment prompted by single cues must be avoided.

Keywords: Atrial fibrillation, STEMI, Electrocardiogram



ST-ELEVATION MYOCARDIAL INFARCTION (STEMI) INFEROPOSTERIOR + RIGHT VENTRICLE INFARCT IN A PATIENT WITH HUMAN IMMUNODEFICIENCY VIRUS (HIV) INFECTION: A CASE REPORT

G.S. Ambara¹, H. Wirawan¹

Department of Cardiology and Vascular Medicine, Faculty of Medicine Udayana University, RSUP Prof. dr. I. G. N. G. Ngoerah, Denpasar, Indonesia¹

Background

HIV infection has role in triggering and accelerates atherosclerosis. Atherosclerosis associated with HIV infection etiological factors and clinical features is different from atherosclerosis in non-HIV.

Case Illustration

A 41-year-old man, complained of left chest pain since 5 hours ago. The patient has a history of HIV and taking ART. Patient still smoking 2 packs/day. Blood pressure was 145/93 mmHg, normal S1S2, regular, no murmurs. On the serial ECG showed sinus rhythm, HR 56 x/minute, normal axis, normal P wave, normal PR interval (160 ms), complex QRS <0.12 sec, R/S ratio in V1 < 1, RV5+SV1 <35 mm and ST elevation in leads II, III, aVF, V4R-V6R, V7-V9 back to the isoelectric line, with STEMI Inferoposterior impression + RV Infarct (susp autolysis?). Troponin I 342.8 and CKMB 132.2. The patient was diagnosed with STEMI Inferoposterior + RV Infarct Killip I (onset 5h, TIMI 1/14, EF BP 57%), Stage I hypertension, Dyslipidemia, Hypertriglyceridemia and stage I HIV infection. The patient undergoes conservative treatment and ARV FDC(TDF/3TC/EFV).

Discussion

Risk factors for MI in HIV patients include age, male sex, smoking, hypertension, co-infection and also ART especially protease inhibitor agents (PIs). Endothelial dysfunction secondary to the use of ART occurs by decreased of nitric oxide (NO) production, increased reactive oxygen species (ROS), impaired cholesterol, and accelerated foam cell formation. HIV infection increase the risk of CVD through the role of viremia, viral translocation, other co-infection which will cause hypercoagulation, endothelial dysfunction and myocardial fibrosis.

Conclusion

HIV infection creates a pro-inflammatory environment that stimulates the progression of atherosclerosis, which correlates with increased risk MI. However, despite control of viremia with the use of ART, continued low levels of HIV replication resulting in ongoing inflammatory processes and immune activation facilitate the progression of CVD.

Keywords: Myocardial Infarction, HIV infection, inflammatory processes, immune activation

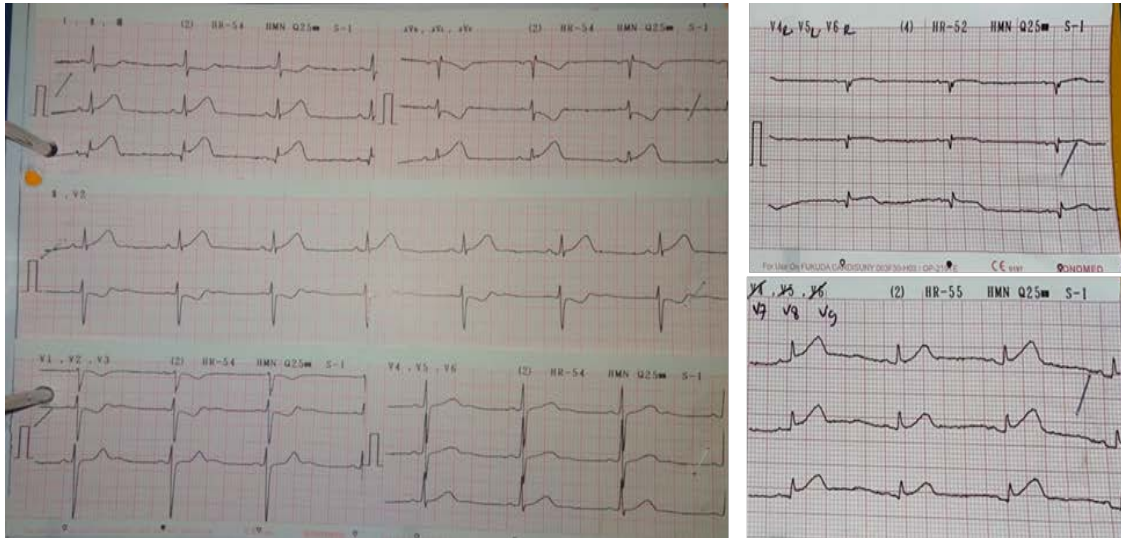



Figure 1. ECG in ER (STEMI Inferoposterior + RV Infarct)



Surviving VSR: When to Operate and What Vascular Complications to Expect?

M.J. Al-Farabi¹, R.R. Juwita¹, R. Bagus¹, Y.H. Oktaviono¹, Andrianto¹, M.Y. Alsagaff¹, Y.E. Sembiring², O. Revianto²

Department of Cardiology and Vascular Medicine, Faculty of Medicine, Airlangga University, Surabaya, Indonesia¹

Department of Thorax Surgery, Faculty of Medicine, Airlangga University, Surabaya, Indonesia²


Background: Ventricular septal rupture (VSR) is one of the most lethal mechanical complications following acute myocardial infarction (AMI) with 94% mortality in one month without surgery. Since it is a rare case, only a few consensus are available to guide us in managing VSR, determining the surgical timing, and understanding potential complications. Interestingly, in June 2022 we have 6 cases of VSR admitted to Soetomo General Academic Hospital. Herein we describe insightful lessons from these case series.

Case Illustration:

6 cases of VSR were admitted to our hospital in June 2022. All cases are late-presentation of non-reperused Anterior STEMI coming from a rural hospital. All cases developed recurrent congestion and circulatory failure. 4 cases used IABP (Intra-Aortic Balloon Pump) to prevent cardiogenic shock and further development of VSR. 4 cases underwent surgery with a 75% survival rate. Two cases failed to undergo surgery due to irreversible shock despite multiple hemodynamic support including IABP, another case was due to no insurance. VSR case who was operated on the 21st day had the best clinical outcome and was discharged immediately 4 days after surgery with NYHA Class II, however, we need to deal with sepsis since the patient had a prolonged stay. Another case who was operated at the 14th day was having progressive residual VSR (0.6-1.2 cm) and develops circulatory failure which ended up in progressive kidney and liver damage. However, the patient survived and was discharged 14 days after surgery with NYHA Class IV. Cases that were operated on the 7th day have conflicting outcomes, the first case was successfully corrected with NYHA Class II outcome but with Acute Limb Ischemia in both of her legs, thus they were amputated. The second case failed to be corrected since no scar was available thus VSR hole cannot be stitched and the patient died immediately after. Other interesting findings are all survivors developed vascular complications. 3 cases developed blue toe syndrome and one case develop Acute Limb Ischemia.

Conclusion: Ventricular septal rupture (VSR) timing of surgery may determine the success rate, survival, type of complications, and NYHA class outcome. Delaying surgery until the 21st day may provide the best outcome and survival yet it will be challenging for the cardiologist due to the risk of sepsis and recurrent congestion. Earlier surgery may be challenging for thoracic surgeons since the risk of stitching failure and residual VSR is high. We also need to be aware of vascular complications when managing VSR which may be caused by macro or microemboli which may be triggered by IABP, interseptal patch, or blood turbulence.

Keywords: STEMI, Surgical Timing, VSR, Vascular Complication



Total AV Block and Sinus Node Dysfunction in Acute Myocardial Infarction: To Pace or Not to Pace?

A.C. Zulfiqar, S.B. Raharjo

Departement of Cardiology And Vascular Medicine, Faculty of Medicine Universitas Indonesia

Background : Conduction disorder are frequent in cases of myocardial infarction. It represents 2-5% of the population with myocardial infarction and are three times more frequent in inferior myocardial infarction than in other region of infarction. Current guidelines recommend permanent pacemakers only for “persistent” infra-nodal or symptomatic second- or third-degree AV block or sinus node dysfunction, however determining persistent conduction disorder after MI are frequently challenging.

Objective : To present a case of cardiac conduction disturbance in SA and AV node following inferior myocardial infarction and its reversibility during hospitalization.

Case Illustration : A 62 years old male came to the emergency room with typical ischemia chest pain since 1 days prior to index hospitalization and evidence of inferior ST-segment elevation. Reperfusion was done percutaneously with 1 drug eluting stent at the right coronary artery. During observation he developed complete AV block on the second day without evidence of re-infarction followed by Sinus node dysfunction on the eighth day of hospitalization. The conduction disorder showed improvement after the tenth days of observation, thus cardiac pacemaker plan was deferred. The patient was discharged from hospital with good haemodynamic status, and with good improvement of the ECG rhythm.

Conclusion : STEMI especially inferior MI is frequently associated with conduction disorders due to its region of vascularization. Most of the conduction disorders in myocardial infarction are reversible. Careful observation and analysis of the 12-lead ECG in patient with conduction disorders will lead to better patient survival.

Keywords: Acute myocardial infarction, TAVB, SND, pacemaker

Management of Clinically Suspected Rheumatic Heart Disease in Rural Area

V. Calosa¹, M. Valeria², N. Dewi³

General Practitioner, Bajawa Public Hospital, East Nusa Tenggara, Indonesia¹

General Practitioner, Inerie Public Health Center, East Nusa Tenggara, Indonesia²

Department of Internal Medicine, Bajawa Public Hospital, East Nusa Tenggara, Indonesia³

Background: Rheumatic heart disease (RHD) is a sequela of acute rheumatic fever (ARF). Although rarely found nowadays, RHD persists among low to middle and income countries (LMIC), including Indonesia. Approximately 82% of deaths occurred in RHD-endemic locations. Adequate treatment when Streptococcal infection or ARF occurred may prevent RHD. It is often not achieved due to low socioeconomic status and limited access to health care. Most patients seek medical treatment once complications occur, therefore RHD has to be recognized earlier. Diagnosis requires echocardiogram and treatment requires surgical intervention, which are often unfeasible in rural area. We present two cases regarding management of clinically suspected RHD in rural area.

Case Illustration: A thirty-five-year-old ('Patient A') and a twenty-nine-year-old woman ('Patient B') had complaints of dyspnea, orthopnea, fatigue, palpitation, cough, and epigastric pain. 'Patient A' had history of heart failure (HF) for 11 years, while 'Patient B' had history of dyspnea since first trimester of pregnancy. Both had frequent sore-throat in childhood. Physical examinations revealed tachycardia, tachypnea, diastolic murmur at cardiac apex, bibasilar crackles, and leg edema.

The predominant cause of mitral stenosis (MS) is rheumatic fever and two-thirds of patients with rheumatic MS are female. Both patients were female and had diastolic murmur at cardiac apex which suggested MS. Clinically-suspected RHD was diagnosed based on history of frequent sore-throat in childhood, LMIC, RHD-endemic area, MS, HF, and AF. We treated the HF and AF. We administered aspirin for the MS and AF instead of vitamin-K-antagonist anticoagulant due to its unavailability. Patients had improved conditions, therefore were discharged and referred to cardiologist for further assessment and management.

Conclusion: It is possible to diagnose clinically-suspected RHD, particularly in LMIC and RHD-endemic area with evident past medical history and clinical findings. Treatments are aimed to overcome RHD complications. Eventually, referral to cardiologist is mandatory.

Keywords: rheumatic heart disease, mitral stenosis, acute heart failure, atrial fibrillation, rural area

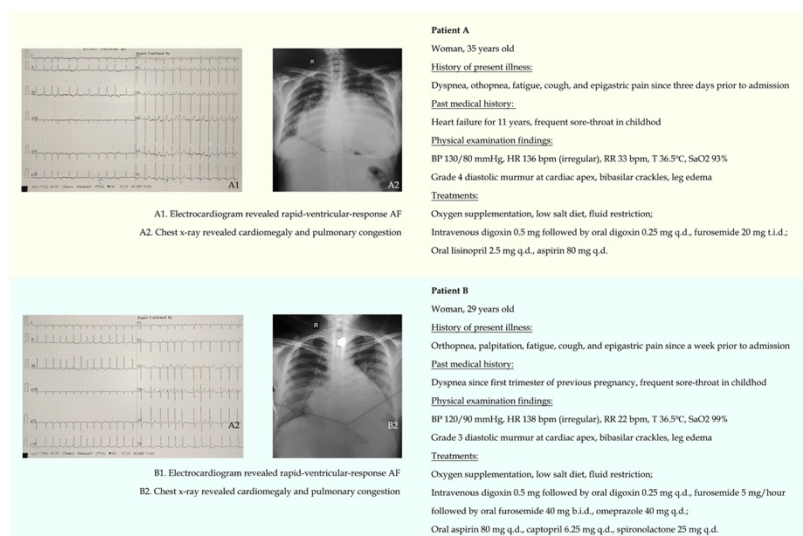


Figure 1. Clinical findings, electrocardiogram, and chest x-ray of Patient A and Patient B

Deep Dive Into Aminophylline as Precipitating Factor of Atrial Fibrillation : A Case Report

N.A. Novebri¹, A. Ciptasari¹, R. Ayuningtyas¹, S. Inayasari¹, S. Novitasari¹, M. Mohamad², L. Pribadi¹, A. Muthmaina¹, M.G. Suwandi¹
RSPAU HARDJOLUKITO¹
PUSKESMAS BANGUNTAPAN 2²

Background: Atrial fibrillation (AF) can occur from many causes. One of which less familiar to general practitioners are pulmonary drugs can also induce atrial fibrillation, including Aminophylline.

Case Illustration: a 57-year-old woman came to the emergency department with chief complaints of a palpitation since one day before admission, she also complaint of short of breath, and severe sweating. No sign of acute decompensated heart failure (ADHF), including rales and pitting oedema. She had medical history of diabetes type II, hypertension, acute bronchitis, CHF NYHA III and AF. the patient was taking routine medicines novorapid 8 units, candesartan 16 mg, aminophylline 200 mg, amlodipine 10 mg. her temperature was normal, blood pressure was 159/91 and her pulse rate was 203 bpm with Irregular heartbeat. The initial ecg showed a rapid atrial fibrillation response. Upon laboratory examination, there was slightly increase in leukocytosis, blood sugar, and markers of kidney function. The patient was diagnosed with CHF fc II et causa HHD dd IHD, AFRVR, Hypertension, Diabetes type II, and Renal Insufficiency. Initially, the patient received a slow bolus injection of 500 mcg digoxin and was admitted to the ICU for further treatment.

Discussion: Aminophylline is nonselective adenosine receptor antagonist. It has been demonstrated that aminophylline reduces the effective and functional refractory period of human and canine myocardium. This electrophysiological effect will dispose to a disparity in the recovery of atrial excitability that may initiate multiple reentrant circuits leading to AF. In this case, there is no sign of ADHF, the patient had history of aminophylline treatment. This condition could be the reason of atrial fibrillation in this patient.

Conclusion: in this patient could be induced by many factors. Based on the risk and historical treatment, the used of aminophylline could be the reason of AF in this patient.

Keywords: Atrial Fibrillation, Aminophylline, Diagnose, Electrocardiogram

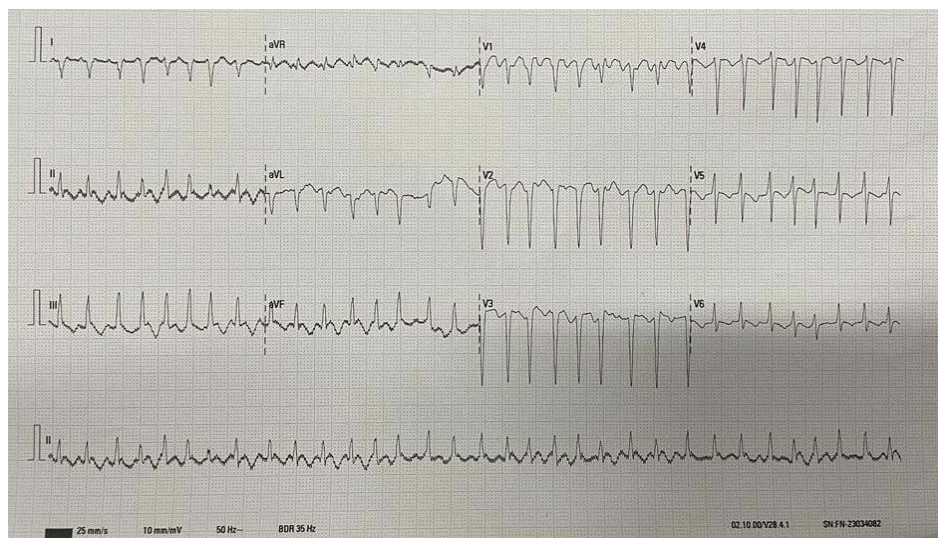



Figure 1. The initial ECG at Emergency Department with occurrence of AF RVR right after the patient came.



To justify aVR, a single lead ST-elevation with high-priority reperfusion

E.R. Utami¹, I. Pratanu¹, M. Budiarto¹, Y.H. Oktaviono¹

¹Medical Faculty Airlangga University, Soetomo General Hospital, Surabaya, Indonesia

Background

The 12-lead electrocardiogram (ECG) is a crucial tool in the diagnosis and risk stratification of acute coronary syndrome (ACS). Unlike other 11 leads, lead aVR has been long overlooked until recent years. However, recent investigations have shown that an analysis of ST-segment shift in lead aVR provides useful information on the coronary angiographic anatomy and risk stratification in ACS.

Case illustration

A 42 years old male patient with unremarkable medical history presented to the emergency room with typical chest pain one hour before initial assessment. His only risk factor is history of heavy smoker for 30 years. Initial electrocardiogram (ECG) showed ST elevation in aVR accompanied by diffuse ST depression. Sequentially, ECG evaluation showed QS pattern in inferior lead. Echocardiography evaluation displayed regional wall motion abnormality in inferior and posterior basal region. Intriguingly, cardiac marker result showed normal troponin I level (0.1 ng/mL). Persistent chest pain occurred despite optimal medical therapy. Urgent coronary angiography than was performed resulting in significant stenosis in distal left main, total occlusion in obtuse marginal (OM) 1, chronic total occlusion in left anterior descending and diffuse disease in right coronary artery. A drug eluting stent then landed in OM 1. Clinical evaluation indicated a substantial decline in chest pain visual analogue score from 7 to 3.

Conclusion

Cardiologists should pay more attention to the tracing of lead aVR when interpreting the 12-lead ECG in clinical practice.

Keywords

ST elevation, aVR, reperfusion.

Keywords: ST elevation, aVR, reperfusion.



Ashman's Phenomenon – An Unusual Electrocardiogram Pattern in Atrial Fibrillation: A Case Report

E.A.D Batubara¹, G.P. Hapsari¹, L.Widianto¹, D.R. Fauzan¹, R.U. Setiani², Haryadi², Yulianto², I.A. Siregar²
¹*Cardiology Resident, Department of Cardiology and Vascular Medicine, Faculty of Medicine University of Indonesia / National Cardiovascular Center Harapan Kita / University of Indonesia Academic Hospital, Jakarta, Indonesia;* ²*Cardiologist, Department of Cardiology and Vascular Medicine, Navy Hospital Mintohardjo, Jakarta, Indonesia*

Background:

The Ashman phenomenon is a rare electrocardiogram (ECG) finding. It is easily misinterpreted as a premature ventricular contraction (PVC) or ventricular tachycardia. The following presented case is a fascinating specimen of the ECG findings of a symptomatic Ashman phenomenon. Therefore, it is engaging because of the rarity of the case and also brings proper attention to the study of rhythm disorder.

Case Illustration:

A 53-year-old male complained of chest discomfort 4 hours prior, palpitation, and nausea. He had a history of hypertension, coronary artery disease, and atrial fibrillation. Coronary angiography two years ago revealed non-significant coronary stenosis with echocardiography concluded hypertrophic cardiomyopathy with normal LV systolic function (Ejection fraction 73%). Clinical examination showed an irregular heartbeat with grade I hypertension. ECG showed atrial fibrillation with aberrant conduction (the Ashman phenomenon), which has an RBBB pattern and occurred when a short R-R interval followed a long R-R interval. Laboratory examination and troponin were all within normal limits. The patient was treated with ramipril, atorvastatin, simarc and amiodarone but later was discontinued following a slow heart rate. Differentiating the Ashman phenomenon vs PVC could be challenging, especially if the heart rate is fast. Fisch criteria may help to discern between typical Ashman phenomenon and PVC, yet some references said that electrophysiological data might not confirm this criterion. Symptoms of the Ashman phenomenon are related to the underlying cardiac condition. No treatment is needed explicitly for this condition. Therapy mandates controlling heart rate or rhythm in atrial fibrillation.

Conclusion:

In principle, the Ashman phenomenon is related to its underlying cardiac condition. However, it is necessary to describe and discuss the interpretation of this rare electrocardiographic finding because it should be differentiated from wide-complex ventricular arrhythmia.

Keywords: The Ashman phenomenon, Atrial Fibrillation, Electrocardiogram



Successful Reversal of Triple Manifestation of Amiodarone Acute Toxicity in Patient with Total Occlusion of LMCA Complicated with Recurrent Ventricular Tachycardia.

M.J. Al-Farabi¹, Y. Azmi¹, A. Kamardikan¹, R. Mahardika¹, M.Y. Alsagaff¹, A. Bachtiar², Y.H. Oktaviono¹
Department of Cardiology and Vascular Medicine, Faculty of Medicine, Airlangga University, Surabaya,
Indonesia¹

Department of Pulmonology, Faculty of Medicine, Airlangga University, Surabaya, Indonesia²

Background

Amiodarone is reported to cause a wide continuum of serious lethal side effects. These include Amiodarone-induced pulmonary toxicity (AIPT), serious bleeding when combined with warfarin, and prolonged QT Interval which can manifest into Torsade de Pointes.


Case Illustration

We describe a 57-year-old patient who developed severe Anterior STEMI which manifested with recurrent ventricular tachycardia. On admission, the patient developed recurrent VT (Ventricular tachycardia) 3 times, and Atrial Fibrillation, hence Amiodarone was given repeatedly until reached 8.2 grams, and warfarin was given to prevent stroke. The patient underwent Percutaneous Coronary Intervention due to hemodynamic deterioration. We found total occlusion on its Left Main Coronary Artery and we stented its Left Main Coronary Artery to mid-LAD. Two days after PCI and 7th days after amiodarone first injection, the patient developed recurrent Torsade de Pointes with prolonged QT Interval (QTc 521), massive epistaxis, worsening bilateral infiltrates, and nodular opacities on chest imaging. We suspected the patient had developed multiple manifestations of amiodarone toxicity thus we stopped amiodarone infusion. We have excluded possible other causes of these manifestations since the patient has normal electrolyte levels, no sign of congestion on echocardiography, and negative bacterial culture. We successfully reversed Torsade de Pointes through cardioversion, prevent its recurrence using Lidocaine, stopped massive epistaxis using bellocq tampon, reversed INR level with Vitamin K, and reversed interstitial lung damage using the steroid for 1 month. 2 months after discharge, the sign of amiodarone toxicity has been reversed proven with normal QTc Interval and no sign of bilateral infiltrates on chest imaging.

Conclusion

To our knowledge, this is the first case of triple Amiodarone toxicity manifestation on LM Occlusion. This case also gives insight into the early identification and aggressive reversal of amiodarone toxicity, which has proven to improve clinical outcomes.

Keywords: Amiodarone Toxicity, Epistaxis, STEMI, Torsade de Pointes



Atrioventricular Node Ablation with Permanent His Bundle Pacing in Patient in Concomitant Atrial Fibrillation and Hypertrophic Obstructive Cardiomyopathy

Rufiat¹, Muzakkir^{1,2}

¹Faculty of Medicine, Hasanuddin University, Makassar, Indonesia;

²Cardiac Center Wahidin Sudirohusodo, Makassar, Indonesia

Background:

Atrioventricular node ablation combined with His bundle pacing (HBP) are feasible, safe, and effective in patients with refractory atrial fibrillation. Among hypertrophic cardiomyopathy with left ventricular outflow tract obstruction patients, atrial fibrillation is a common sustained arrhythmia, primarily caused by left atrial dilatation and remodelling.

Case Illustration :

We report a case of successful atrioventricular node ablation combined with His bundle pacing in a 35-year-old male with slow atrial fibrillation and hypertrophic obstructive cardiomyopathy with left ventricular outflow tract obstruction. Echocardiographic examination showed maximum left ventricle outflow tract gradient of 64.61 mmHg, severe mitral valve regurgitation due to prolapse anterior mitral leaflet, normal systolic left ventricular function with ejection fraction of 68% and normal systolic right ventricular function prior to procedure. Maximum left ventricle outflow tract gradient was significantly reduced to 36.5 mmHg after procedure.

Conclusion :

His-Purkinje conduction system pacing combined with atrioventricular node ablation system pacing combined with atrioventricular node ablation (AVNA) is a feasible and safe with a high success rate in persistent atrial fibrillation patients with heart failure and ICD indication, such as hypertrophic obstructive cardiomyopathy with left ventricular outflow tract obstruction. AVNA with HBP in this condition is associated to improve symptoms and quality of life through decrease in left ventricle outflow tract obstruction.

Keywords: atrioventricular node ablation, permanent his bundle pacing, atrial fibrillation, hypertrophic obstructive cardiomyopathy

A Rare Case of Total Atrioventricular Block in Children: what we can do in remote district hospitals?

Eliza¹, K.D. Krisnayanti¹, G.A.R. Pertiwi¹

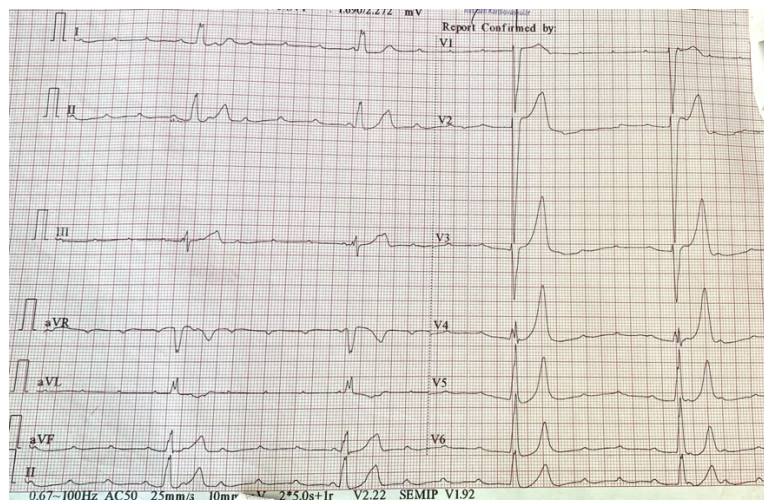
Waikabubak Regional District Hospital, West Sumba, East Nusa Tenggara, Indonesia¹

Background: Myocarditis complicated total atrioventricular block (TAVB) is rare in children. Of the varied presentations of myocarditis, total atrioventricular block (TAVB) was thought to be an isolated feature, with rapid and full recovery if it was diagnosed early and treated with emergency pacemaker implantation.

Case Illustration: A 16-year-old male came to the emergency department with recurrent syncope of 10-minute episodes at home. One week ago, he developed a fever, epigastric pain and repeated vomiting. Physical examination were unremarkable except heart rate (HR) of 24 bpm. An electrocardiogram (ECG) showed a total AV Block with ventricular escape rhythm (atrial rate 100 bpm, ventricular rate 27 bpm). The chest x-ray and echocardiogram findings were normal. The LED level was increased (30 mm/h). Acute myocarditis with alternative of electrolyte imbalance were considered as underlying causes. Despite of maximal atropine sulfate doses, followed by a dopamine infusion, the ventricular rate relatively unchanged. So we start epinephrine infusion, combined with salbutamol, and ibuprofen as anti-inflammation. The HR was improved after third day with evolution to 2nd degree AV Block type I and the patient was safely discharged at the 8th day. A TAVB is ideally treated with a temporary pacemaker. However, as it was not available in our area, treatment was limited to the oral and IV medications described above. The fever and increased LED pointed to myocarditis as the underlying cause. The vomiting indicated the possibility of an electrolyte imbalance and this could not be definitely ruled out as we did not have the modality to check for electrolyte levels.

Conclusion: Myocarditis should be considered as a transient TAVB in children. In remote area, the core management include hemodynamic support and adequate anti-inflammation.

Keywords: TAVB in childhood, symptomatic bradycardia, syncope, myocarditis acute



Total AV Block Echocardiogram

Newly documented right bundle branch block in presence of lateral STEMI: A predictor of poor prognosis?

R. Ayuningtyas¹, N.A. Novembri¹, A. Ciptasari¹, S. Inayasari¹, A. Novitasari¹, W. Pamungkas², M.G. Suwandi¹,
L. Pribadi¹, A. Muthmaina¹

Rumah Sakit Pusat Angkatan Udara Suhardi Hardjolukito, Bantul, Indonesia¹
Adisutjipto Air Force Base, Bantul, Indonesia²

Background:

ST-segment elevations in two or more contiguous leads or either new left bundle branch block (LBBB) or right bundle branch block (RBBB) on ECG in a patient with acute onset chest pain are diagnostic criteria for acute myocardial infarction and generally condone coronary angiography and cardiac catheterization.

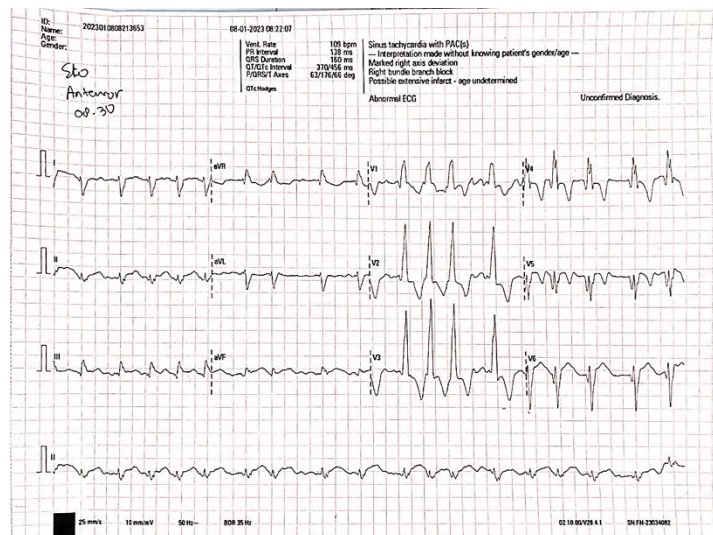
Case Illustration:

A 62-year-old man presented to emergency department with chest discomfort and cold sweats. He was comatous with irregular heart rate of 109 bpm, tachypnea with oxygen saturation 98% using NK 3 lpm. His blood pressure was normal. He had a history of heart failure with low EF and also stroke, not routinely controlled or monitored. His ECG showed lateral STEMI with new onset RBBB. The patient was assessed with Lateral STEMI Killip II onset 3 hours, AFRVR, CHF of II (Low EF) ec IHD/HHD, PETA, renal insufficiency. Due to worsening chest pain and relative contraindicative for fibrinolysis, he was then referred for primary coronary intervention. His coronoangiography at the referral hospital showed 80% occlusion in mid LAD, hence 1 DES was implanted.

Conclusion:

New-onset RBBB in a patient with typical STEMI and ischemic symptoms should raise suspicion of critical LAD coronary occlusion. It is increasingly being recognized as one of ECG patterns associated with worse outcome. It is important to minimize the delay in performing reperfusion therapy as they can improve outcome and survival.

Keywords: STEMI, RBBB, Acute Coronary Syndrome



Clinical Outcome of Post Right Ventricular Outflow Tract Stenting in the Severe Cyanosis Tetralogy of Fallot Case With Down Syndrome

I.S. Pradisa¹, M. Pramudyo¹

Department of Cardiology and Vascular Medicine, Faculty of Medicine, University of Padjadjaran, Bandung, Indonesia¹

Abstract

Background. Surgical repair of Tetralogy of Fallot (TOF) in early infancy has become advances. A less invasive strategy such as Right Ventricular Outflow Tract (RVOT) stenting has many potential benefits in term of stabilizing the clinical condition. However in a critically condition with severe cyanosis, surgical repair is expected to carry a high morbidity and mortality risk. ToF represents 75% in cyanotic congenital heart disease and infrequent association with Down Syndrome (DS). A good corrective surgery of TOF with DS patients can prolong their life. Thus, in this case report, we would like to propose clinical outcome of post RVOT stenting in the TOF patient with DS.

Case Illustration. A 6-month-old girl presented to Hasan Sadikin Hospital due to worsening shortness of breath and progressively cyanosis 30 minutes prior to arrival. Her weighed 5.5kg and length 48cm. She was saturating 65% and had severe cyanosis. The child was intubated on ventilator. On physical examination, she has short stature, flattened facies with depressed nasal bridge, almond-shaped eyes, all the symptoms refers to DS. Echocardiography was performed and showed TOF with subinfundibular stenosis. She was brought to the catheterization laboratory for RVOT stenting. In the middle of procedure, she has severe bradycardia and cardiac arrest, fortunately she was Return of Spontaneous Circulation (ROSC) without any complication and show clinical improvement without cyanosis..

Conclusion. TOF with DS has high risk of severe cyanosis and can be increase morbidity and mortality risk in surgical repair. RVOT stenting is relatively safe for TOF case with DS without any complication.

Keywords. tetralogy of fallot, right ventricular outflow tract, down syndrome, clinical outcome
Keywords: tetralogy of fallot, right ventricular outflow tract, down syndrome, clinical outcome

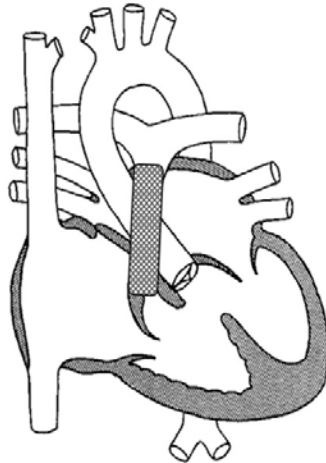


Figure 1. Post right ventricular outflow tract stenting in patients tetralogy of fallot with down syndrome



Management of Tuberculous Pericarditis with Cardiac Tamponade in Remote Area: A case report

E. Zuhri¹, W.S. Yahya¹

Teluk Bintuni Hospital, Papua Barat, Indonesia¹

Background. Tuberculosis accounts for up to 4% of acute pericarditis and 7% of cardiac tamponade cases. Cardiac tamponade is a life-threatening condition. Emergent pericardiocentesis should be performed. But, sometimes in remote area, the standard equipments to perform pericardiocentesis are not available.

Case Illustration. A 66-year-old man presented to the emergency room with dyspnea and hypotension. Chest X-rays showed global cardiomegaly with a rounded heart shape. The echocardiogram showed a large pericardial effusion with sign of cardiac tamponade. Because of limited equipment, an emergent pericardiocentesis was performed using double lumen central venous catheter 7F through apical approach. There is no complication during and post procedure. The pericardial fluid was seroxanthochrome and the nested real time-polymerase chain reaction (PCR) of pericardial fluid examination showed tuberculosis infection. Cytology revealed no malignant cell. The serology for HIV was negative. Anti-tuberculosis regimen in combination with corticosteroid and colchicine was then started. The patient's condition improved and was discharged on the tenth day. After 6 months of therapy, no signs of constrictive pericarditis was found.

Conclusion. Key management of tuberculous pericarditis is the administration of anti-tuberculosis regimen and anti-inflammatory drugs to prevent further complications such as constrictive pericarditis. If tuberculous pericarditis is accompanied by cardiac tamponade, emergent pericardiocentesis should be performed even with limited equipment.

Keywords: Cardiac tamponade, pericarditis, pericardiocentesis, tuberculosis

a case of 20 years old man with acute pericarditis

A. Mahadewa¹

Departemen Kardiologi FK Unhas¹

BACKGROUND

Acute pericarditis is a syndrome of inflammation of the pericardium with or without pericardial effusion. The etiology of acute pericarditis consists of both infectious and non-infectious consequences. Infection can be caused by viruses, tuberculosis, and pyogenic bacteria. While non-infectious can come from post myocardial infarction, uremia, malignancy, radiation-induced, connective tissue disease, and drugs. The characteristics of pericarditis consist of 3 stages, namely 1) local vasodilatation through fluid transudation into the pericardial cavity; 2) increased vascular permeability causing protein leakage into the pericardial cavity; 3) leukocyte exudation, starting from neutrophils then followed by mononuclear cells.

The most common symptoms are chest pain and fever. Chest pain may be severe and is usually localized to the retrosternal and left precordial areas. Dyspnea also usually occurs but is not affected by activity and may result from the patient's fear of taking a breath due to pleuritic pain. The clinical diagnosis can be established by 2 out of 4 criteria, namely typical sharp chest pain, pericardial friction rub, diffuse ST segment elevation on EKG examination, and pericardial effusion

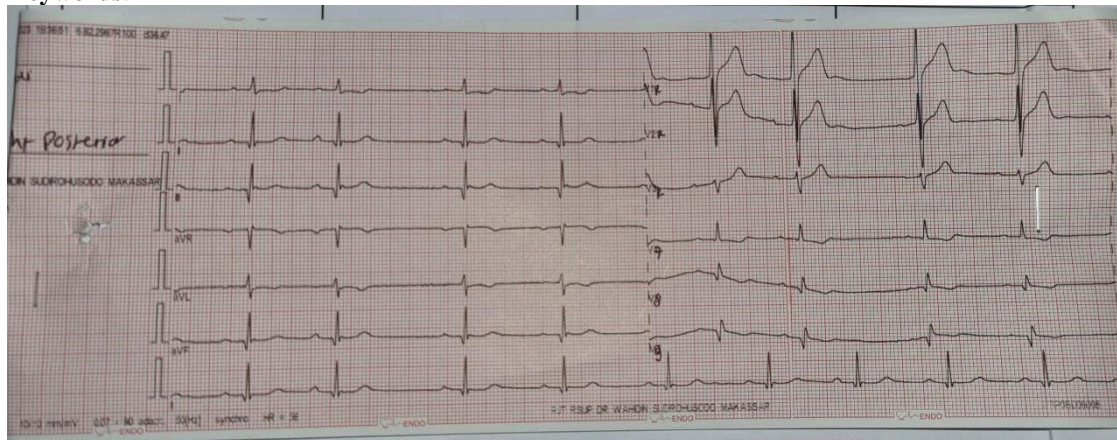
CASE ILLUSTRATION

Acute pericarditis is a form of pericardial inflammatory disease with idiopathic or viral as a common cause. We reported a case of 20 years old man with acute pericarditis of unknown cause. The patient has appearance of clinical and typical electrocardiography finding for acute pericarditis. Inhospital management using ibuprofen and colchicine with improvement therapeutic result. Pasien had discharge 5 days later and constantly receiving colchicine to avoid further complication

CONCLUSION

It has been reported a male patient aged 20 years with complaints of pain acute chest, pleuritic and aggravated by lying down and relieved by sitting position. Preceded by an episode of fever 5 days earlier which resolved with itself. Electrocardiographic examination showed ST segment elevation diffuse and diffuse segment depression. Laboratory tests show leukocytosis, increased ESR and increased cardiac enzymes. Patient later diagnosed as acute pericarditis.

Keywords:



Catheter-directed Thrombolysis in Acute Lower Limb Ischemia Rutherford II B

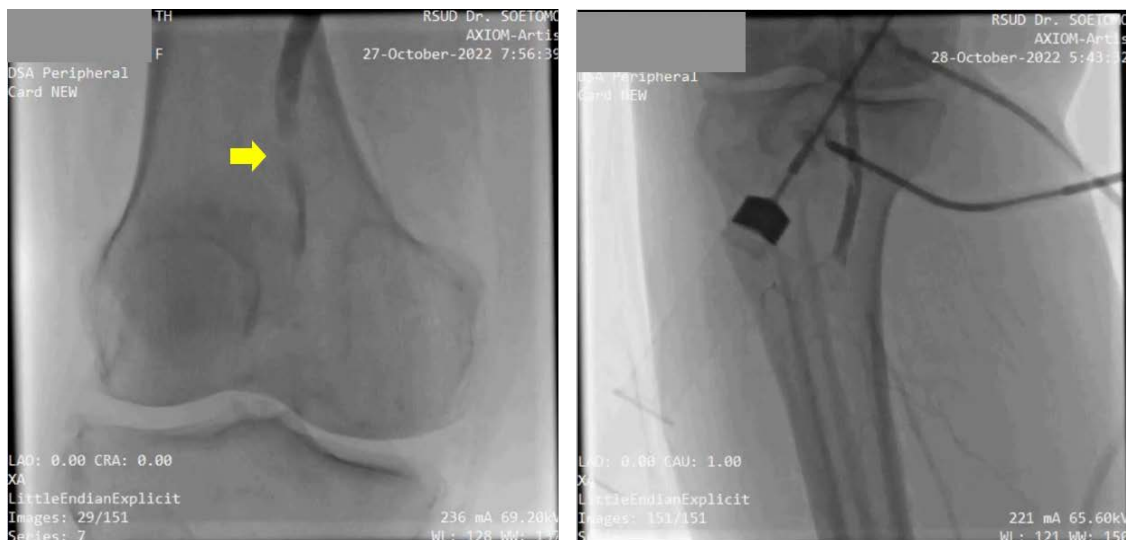P.D.K. Devi¹, L.H. Andira¹, J.N.E. Putranto¹
Faculty of Medicine Universitas Airlangga / RSUD Dr. Soetomo¹

Background: Catheter-directed thrombolysis (CDT) is the treatment of choice for patients with relatively mild acute limb ischemia (ALI) (Rutherford categories I and II A) with no contraindications to thrombolytic therapy. However, patients with severe acute limb ischemia (Rutherford category IIb) also need emergent revascularization. CDT should be considered, nonetheless, if the relative risks compared with the primary operation are favorable.

Case Illustration: A 66 years old female comes with progressive pain on the right lower extremity, concomitant with pulselessness, pallor, and mild muscle weakness. Physical examination showed pulseless on the right distal femoral, popliteal, tibialis anterior, tibialis posterior, and dorsalis pedis arteries. Duplex ultrasonography showed irregularity of arterial wall along right leg arteries, partially color-coded at mid superficial femoral artery (SFA), no color-coded at distal SFA, popliteal artery, anterior tibialis artery, proximal tibialis artery, and distal peroneal artery. Angiography revealed total occlusion at distal SFA, then the patient underwent percutaneous catheter-directed intra-arterial thrombolysis. Re-angiography evaluation showed flow resolution at distal SFA, consistent with clinical improvement.

Conclusion: Thrombolysis is the treatment of choice for ALI patients with categories I and II A, whereas patients with progressive ischemia or category II B are indicative of surgical revascularization. However, some studies show Rutherford II B ischemia can be safely treated with endovascular intervention, which may be an attractive option for patients at high risk for surgery due to prohibitive medical risk or anatomic factors.

Keywords: Acute limb ischemia, Rutherford, catheter-directed thrombolysis, endovascular intervention



Hypertrophic Cardiomyopathy: a Case Report

R.S. Ayuningtyas¹, R. Wahyuni, Michael¹, E. Mariska¹, N. Primaditta¹, N. Marliyanti¹, M. Jufianti¹, S. Hidayatullah¹, P.P. Dewi²

¹General Practitioner, International Central Army Hospital Gatot Soebroto, Jakarta, Indonesia; ²Cardiologist, International Central Army Hospital Gatot Soebroto, Jakarta, Indonesia

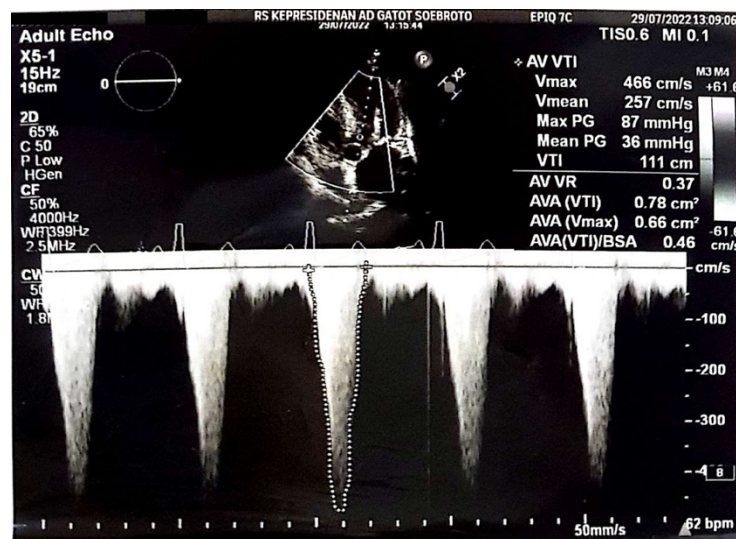
Background: Hypertrophic cardiomyopathy (HCM) is a common inheritable cardiac disease defined by presence of increased left ventricular (LV) wall thickness >15mm in adults, often accompanied by left ventricular outflow tract obstruction (LVOTO), and malignant arrhythmia leading to sudden cardiac death (SCD). Annual incidence of SCD in adult patients with HCM is approximately 1-2%.

Case Illustration: A 68-year-old female was referred to a cardiologist with complaints of shortness of breath with marked limitation of physical activity and occasional palpitation. Her blood pressure was 127/87 mmHg, pulse rate 67 bpm regular, respiratory rate 20 times/minute and temperature 36,6 °C. Mid-systolic heart murmur at 6th left intercostal space was also present. ECG findings were not specific with sinus rhythm, normal axis, no pathological Q wave nor ST-T changes. CT coronary angiogram showed non-significant 10% stenosis in LAD, Calcium score was 111. Her NT-proBNP level was 1528 pg/mL.


Transthoracic echocardiogram (TTE) showed concentric left ventricular hypertrophy (LVH) with interventricular septal thickness in diastole (IVSD) of 25mm, systolic anterior motion (SAM) with moderate regurgitation of mitral valve, and Max LVOT gradient of 87 mmHg. Patient was treated with Bisoprolol 2,5mg SID, Furosemide 20mg SID, Spironolactone 25mg SID, Candesartan 8mg SID, Acetylsalicylic Acid 80mg SID and Atorvastatin 20mg SID. Patient's shortness of breath was alleviated after given therapy, but she remained limited to minimal physical activity. Presence of LVOT gradient \geq 50mmHg and refractory symptoms despite medication indicates consideration for septal reduction therapy (SRT). Patient was offered alcohol septal ablation (ASA), but patient declined interventional therapy for now. 24-hour holter monitoring is scheduled to find presence of arrhythmia to determine 5-year risk of SCD and indication for prophylactic ICD.

Conclusions: HCM is closely related to sudden cardiac death, therefore risk stratification is important to determine patient's plan of therapy.

Keywords: hypertrophic cardiomyopathy, left ventricular outflow tract obstruction, HCM, LVOTO



Echocardiogram showing Max LVOT Pressure Gradient of 87 mmHg



SATISFYING OUTCOME IN PATIENT WITH LAUBRY-PEZZI SYNDROME WITH INFECTIVE ENDOCARDITIS FOLLOWING CARDIAC SURGERY: LESSON LEARNED IN CASE OF 22 MALE YEARS OLD

I. Defriany¹, Y. Patimang², A.A.U. Armin², M.N. Mallapasi³, J. Kusumanegara³

Cardiovascular Department, Faculty of Medicine, Hasanuddin University-Hasanuddin University Hospital, Makassar, Indonesia¹

Pediatric Division, Cardiovascular Department, Faculty of Medicine, Hasanuddin University-Hasanuddin University Hospital, Makassar, Indonesia²


Cardiovascular and Thoracic Surgery Department, Faculty of Medicine, Hasanuddin University-Hasanuddin University Hospital, Makassar, Indonesia³

Background: Laubry-Pezzi syndrome combines a ventricular septal defect (VSD) and aortic regurgitation (AR) due to coronary cuspid prolapse. Inadequate correction can exacerbate existing aortic regurgitation, even triggering complications of infective endocarditis.

Case illustration: A 22-year-old man came to the emergency room with complaints of fever three weeks ago, which did not improve with antipyretics. This complaint has been accompanied by coughing and shortness of breath during activities since 1-3 months ago. There was no history of sore throat, visits to the dentist, or history of blues as a baby before. The hemodynamic state was relatively stable. However, a body temperature of 38.2°C, a harsh holosystolic murmur of degree III/VI at the lower left sternal border, a grade III/IV diastolic murmur at (Intercostal Space) and apex, and pathognomonic signs of aortic regurgitation was obtained. This clinical condition is supported by cardiomegaly with an R-L shunt on chest X-ray examination, leukocytosis, and neutrophilia. Echocardiographic examination showed a subaortic VSD, severe AR, vegetation on the aortic valve that exceeded 10 mm, left ventricular dilatation, and mild pericardial effusion but preserved systolic function in both ventricles. The diagnosis of Laubry-Pezzi Syndrome with infective endocarditis was made in this patient and followed by VSD Closure, Aortic Valve Replacement (AVR), and vegetation evacuation. The patient's condition gradually improved during treatment, and he was subsequently discharged in a stable hemodynamic state. In this case, a subaortic VSD is suspected, which can cause a venturi effect and lead to AR. This venturi effect may also precipitate infective endocarditis in these patients. Based on the size of the vegetation and severe AR on echocardiographic examination, vegetation evacuation is indicated with recommendation class IIa.

Conclusion: Surgical correction with VSD closure, AVR, and vegetation evacuation can provide good outcomes in patients with Laubry-Pezzi Syndrome with infective endocarditis.

Keywords: Aortic Regurgitation, Infective Endocarditis, Laubry-Pezzi Syndrome, Surgery, Ventricular Septal Defect



Hybrid Endovascular Procedure in Chronic Aortic Dissection: First Time Experience outside of Central Indonesia

A.M. Tahir¹, I. Mappangara¹, A.H. Nashar¹, A.A.U. Army¹, J. Kusumanegara², A. Adil³

¹Department of Cardiology and Vascular Medicine, Faculty of Medicine, University of Hasanuddin
²Division of Thoracic and Cardiovascular Surgery, Department of Surgery, Faculty of Medicine, University of Hasanuddin
³Division of Cardiovascular Anesthesia, Department of Anesthesiology and Intensive Care, Faculty of Medicine, University of Hasanuddin


Background: Aortic arch repair and great vessel are complex procedures and carries a high risk of complications as well as mortality. Type A Aortic dissection is a life-threatening condition that occurs in 60% of cases of aortic dissection. There is no general consensus in classifying 'fitness for open arch surgery', TEVAR or hybrid procedures, depends on the surgeon's individual experience only. Hybrid endovascular procedures combines traditional open surgery with stent placement (Thoracic Endovascular Aneurysm Repair/TEVAR).

Case Illustration: We reported a 58-year-old male patient presented with progressive shortness of breath due to a large aneurysm of distal aortic arch and descending aorta (max diameter 80 mm). The patient diagnosed with Chronic Stanford A debakey type I Aortic Dissection underwent total arch debranching and concomitant on-pump surgery. Operations were performed under deep hypothermic circulatory arrest (DHCA) and selective antegrade cerebral perfusion (SACP). During antegrade cerebral and lower body (distal) perfusion, the ascending aorta was resected and an 'elephant trunk procedure' with a 22-mm prosthetic graft (Gelweave™). The aortic valve was competent. Hybrid endovascular procedures (TEVAR) was performed during the same operation as the debranching procedure. TEVAR of the transverse arch (after artery innominate) using one stent graft 28(24) x 150 mm (Seal®). TEVAR coverage extended aortic descendens, was successfully performed retrogradely via the femoral artery under fluoroscopy with good perfusion below followed by completion angiography.

Discussion: The optimal treatment of Chronic Stanford A debakey type I Aortic Dissection remains unclear. Strategies to aortic arch treatment is the hybrid aortic repair, which combine open surgical (total arch debranching) and endovascular techniques simultaneously in a single single-stage procedure in high-risk patients. Hybrid and total endovascular approaches show promising results but are associated with the risk of complication in early postoperative period and the risk of multiple in the late postoperative period, therefore careful attention about this fact must be required during follow up.

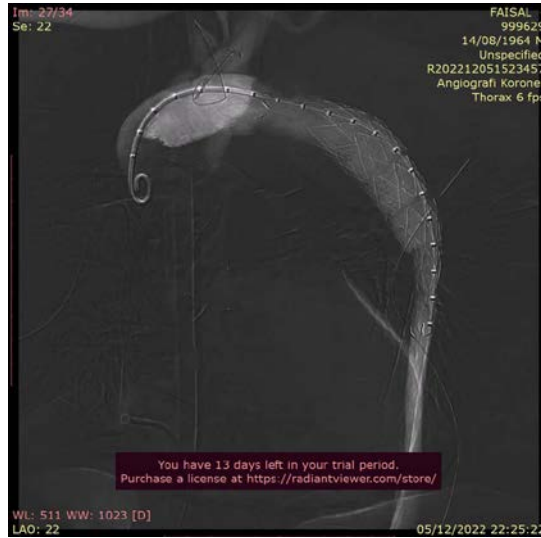Conclusion: Open arch surgery continues to be the current "gold standard" for treatment of aortic pathology, and currently other lesser invasive procedures such as hybrid endovascular procedures (including debranching techniques) was performed. Target treatment strategies for Aortic Dissection are treat the rupture, reverse malperfusion and prevent acute aneurysm formation. The First Hybrid Endovascular Procedure was successfully performed on a single-stage procedure in our centre.

Keywords: Chronic Stanford A debakey type I Aortic Dissection, Hybrid Endovascular Procedures, Total Arch Debranching, Thoracic Endovascular Aneurysm Repair.




Indonesian Journal of Cardiology

Indonesian J Cardiol 2023;44:suppl_A
pISSN: 2830-3105 / eISSN: 2964-7304
doi: 10.30701/ijc.1537



3D RECONSTRUCTION



A Rare Case: RV Infarction due STEMI Inferior

R. Carolin¹, M.S. Queen¹, A.S. Shahab¹, A.A. Indah², S. Firdausia¹, A.T. Faizal³

Faculty of Medicine, National Development University Veteran of Jakarta, Jakarta¹

Department of Cardiology and Vascular Medicine Faculty of Medicine University Indonesia, National Heart Center
Hospital, Jakarta²

Cardiologist, Department of Cardiology and Vascular Medicine, Raden Said Sukanto Hospital, Jakarta³

Background:STEMI is an indicator of total coronary artery occlusion. Inferior STEMI is one of the most common types of ACS with 40% of the total incidence. This situation requires myocardial reperfusion as soon as possible. This case report describes inferior STEMI with a wide variety of clinical manifestations before and after treatment.

Case Illustration:A 52th y.o. man presented with typical chestpain, diaphoresis, vomit since 3hours before hospitalization. During triage, the ECG finding was ST elevation II, III, aVF, 3rd degree AV Block. General examination revealed GCS E3M5V3, BP 60/40mmHg, HR 35x/m, CK-MB 26U/L, and diagnosed by inferior STEMI, cardiogenic shock, and treated with SA 1mg, Dopamin 5mcg, Norepinephrine 12mcg, Clopidogrel 300mg, ASA 160mg, Atorvastatin 40mg/24h, and plan transferred to have PCI. ECG during thrombolytics showed ST elevation II, III, aVF, atrial fibrillation, 1st degree AV Block, pathological Q waves II,III,aVF. After thrombolytic patient transferred for PCI. After PCI ECG showed 1st degree AV Block, pathological Q wave III,aVF, inverted T waves II,III,aVF.

Inferior STEMI is diagnosed if there is >1-2mm of ST elevation in two contiguous leads (II, III, aVF) with ischemic chest pain. In this case, the ECG shows ST elevation in leads II,III,aVF, with ST elevation in lead III higher than lead II. Right ventricular infarction is observed in patients with inferior wall myocardial infarction. Assessment of right precordial lead is particularly helpful for diagnosis of RV infarction. ST elevation >1.00mm in lead V4R and V6R is highly suggestive of proximal RCA occlusion and RV infarction.

Conclusion: In the case of RV infarction, right-sided ECG and posterior ECG needs to be done in order to confirm the diagnosis. For the treatment, PCI should be done in under 12 hours after the onset in order to maximize the reperfusion of heart and to increase the life expectancy.

Keywords: Acute Coronary Syndrome, STEMI inferior, RV Infarction



The Essential of Serial Electrocardiography in Patient with Chest Pain: A Case Report

R. Rasaki¹, M. Fitra¹, T. Heriansyah¹, M. Muqsith¹

¹Department of Cardiology and Vascular Medicine, Faculty of Medicine, Universitas Syiah Kuala, Banda Aceh, Indonesia.

Background: Electrocardiography (ECG) is the established diagnostic tool in the assessment of patients with typical chest pain. The ECG characteristic in the setting of NSTEMI-ACS includes ST-segment depression, transient ST-segment elevation, T-wave changes, or normal ECG. Guidelines recommend serial ECG evaluation in the routine management of NSTEMI-ACS. In clinical practice, serial ECG may also identify dynamic T-wave changes.

Case Illustration: We reported a 44-year-old man presented to the emergency department with a chief complaint of chest pain 4 hours before admission. His cardiovascular risk factor was smoking. Physical examination was unremarkable. Initial ECG showed normal sinus rhythm without ST-T abnormalities and initial laboratory findings showed normal Troponin-T level. We managed him with double anti-platelet, anticoagulant, statin, and isosorbide dinitrate. After 3 hours of observation, we performed serial ECG showing a normal sinus rhythm with inverted T-waves in leads V2-V6. Then we performed a serial Troponin T testing showed a significant increase in Troponin-T level. We planned to perform an early invasive strategy for the management of high-risk NSTEMI. Several hours later, ECG showed deeper inverted T-waves in leads V2-V6 plus inverted T-waves in leads I and aVL. Then, we performed coronary angiography revealing critical stenosis in proximal LAD, stenosis of 90% in distal LCx, and stenosis of 60% in PDA. It was managed by percutaneous coronary intervention using DES implantation in proximal LAD.

Conclusion: Electrocardiography is a feasible and useful tool to evaluate patients with chest pain. It provides an important tool for the diagnosis and risk stratification of patients with acute coronary syndrome. Furthermore, serial ECG and troponin-T testing are essential to determine the best management for patients with NSTEMI-ACS.

Keywords: *Chest Pain, Serial Electrocardiography, Troponin-T*

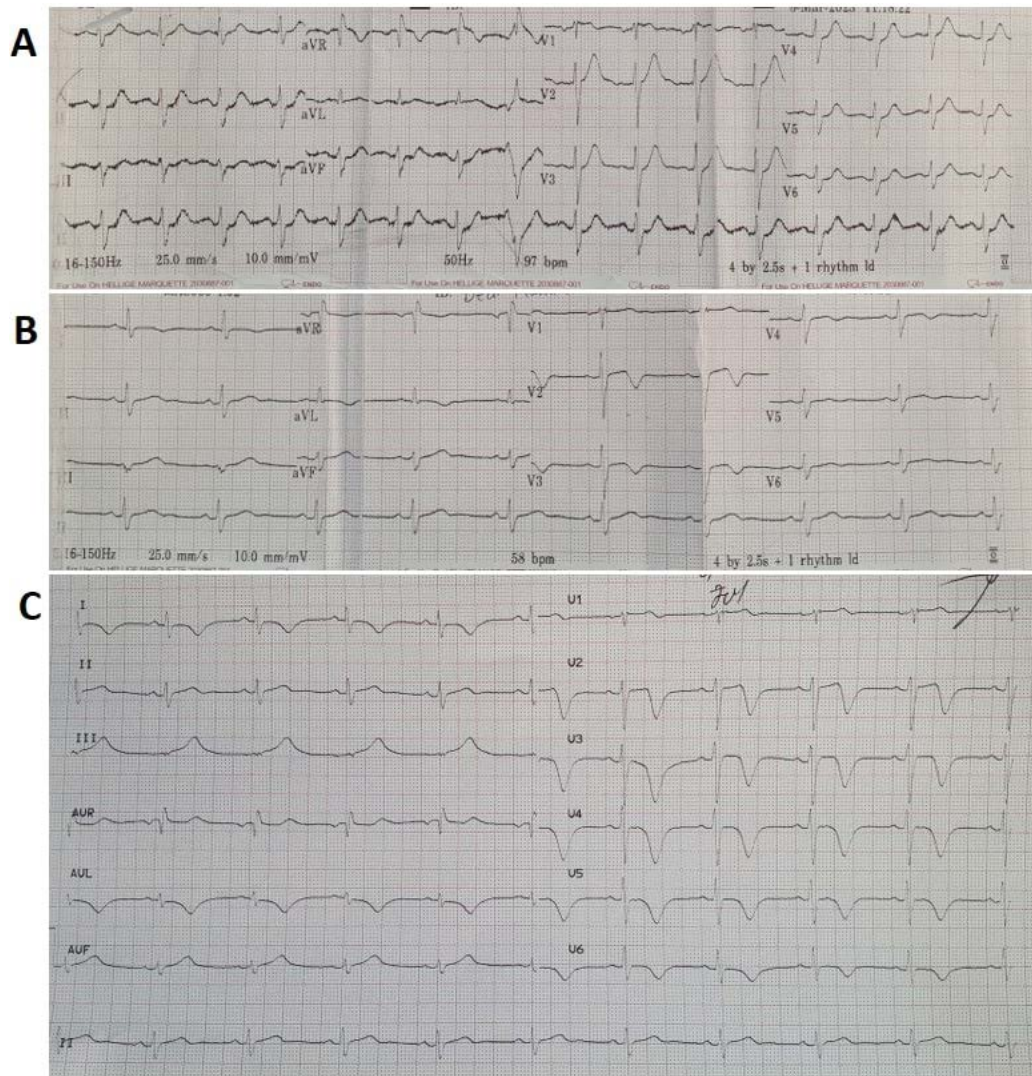


Figure 1. Serial electrocardiography tracing (A). Sinus rhythm with a heart rate of 97 beats per minute and incomplete right bundle branch block without ST-T abnormality, (B). After 3 hours of observation



Right Superior Pulmonary Venous Aneurism: The Role of Computed Tomography to Reveal It – A Rare Case

A. Achmad¹, H.A.P. Lubis², S. Tarigan³, I.A. Pratiwi⁴, A.C. Lubis⁵, C.A. Andra⁶, K.K. Ilyas⁷


^{1,3}Cardiology Resident at Cardiac Center H. Adam Malik Hospital, Faculty of Medicine Universitas Sumatera Utara, Medan, Indonesia ^{2,4,5,6,7} Cardiologist at Cardiac Center H. Adam Malik Hospital, Faculty of Medicine Universitas Sumatera Utara, Medan, Indonesia

Background Pulmonary venous aneurism (PVA) is a rare vascular anomaly characterized by local aneurysmal dilatation of the pulmonary vein. Contrast CT Scan can help diagnose of a rare case venous anomaly such as PVA without having to performed invasive diagnostic test. PVA may present as a pulmonary nodule or mediastinal mass, and often deviced from incidental findings. The etiology of PVA can be an acquired or a congenital origin. Patients often asymptomatic, while some patients could have hemoptysis, dyspnea, chest tightness or cerebral thromboembolism. The cause of PVA may be associated with mitral regurgitation and increase left atrial pressure. Proper diagnosis is crucial to avoid unnecessary testing or surgical procedures.

Case illustration: A 62-years-old woman with atypical chest pain with history of hypertension. The physical examination was unremarkable. ECG showed sinus rhythm. Chest X-Ray showed a solid lesion on the right lower region of the lung, mild cardiomegaly and aortic dilatation. A transthoracic echocardiography showed preserved LV systolic function, TR mild, normal RV function and no sign of pulmonary hypertension. Contrast chest CT scan revealed right superior pulmonary venous aneurysm with ostium diameter 15.3mm and aneurism diameter 49.6 x 41.3 mm. Aneurysm defined as a 50% increase from normal size of PVA. We found large PVA with more than 50% enlargement from contrast CT.

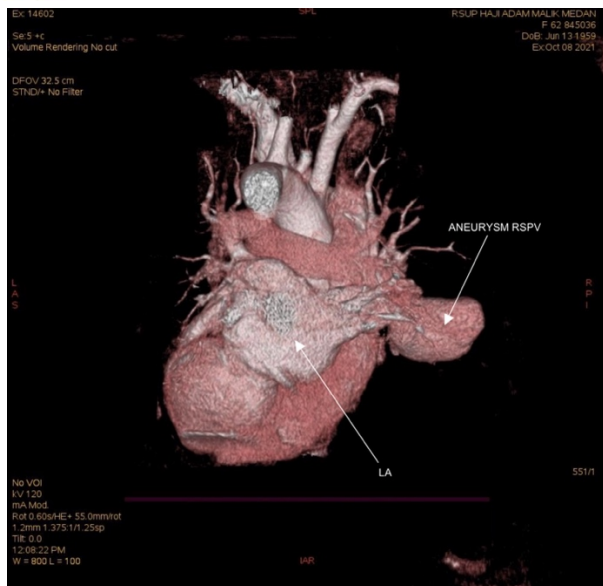
Conclusion: Pulmonary venous aneurism (PVA) is a rare vascular anomaly characterized by local aneurysmal dilatation of the pulmonary vein. CT Scan can help diagnose PVA without having to performed invasive diagnostic test. Our case report showed PVA with no sign of mitral regurgitation and we suggest surgery procedure if patient develop worsening of clinical symptoms.


Keywords: Pulmonary Venous Aneurysm CT-Scan



Indonesian Journal of Cardiology

Indonesian J Cardiol 2023;44:suppl_A
pISSN: 2830-3105 / eISSN: 2964-7304
doi: 10.30701/ijc.1537





Intra-aortic Balloon Pump For Haemodynamic Stabilization in Acute Myocardial Infarction Complicated by Cardiogenic Shock after Primary Percutaneous Coronary Intervention : A Case Report

L.H. Hutapea¹, K.K. Ilyas², A. Sitepu³, F. Habib⁴, C.A. Andra⁵


¹Cardiology Resident, Department of Cardiology and Vascular Medicine, Faculty of Medicine, Universitas Sumatera Utara, Medan, Indonesia;^{2,3,4,5}Cardiologist, Department of Cardiology and Vascular Medicine, Faculty of Medicine, Universitas Sumatera Utara, Medan, Indonesia

Background: Mortality rate of over 40% occurred in patients of Acute Myocardial Infarction complicated by Cardiogenic Shock (AMICS). Nonetheless, many patients with AMICS have potentially significant amounts of stunned myocardium that could recover within days post-revascularization. The role of mechanical support with intra-aortic balloon pump (IABP) after percutaneous coronary intervention (PCI), is still questionable but sometimes can be considered as a bridge therapy to maintain hemodynamic stability and support myocardium recovery.

Case Illustration: A 40 – year – old male presented with ventricular tachycardia (VT) and cardiogenic shock in recent anteroextensive MI and complained of chest pain, palpitations, and diaphoresis three days prior. He was a smoker, with neither any other modifiable risk factor nor significant family history with cardiovascular disease. ECG findings were ST segment elevations with pathological Q wave in lead V1-V6, I, and aVL followed by sustained VT. Echocardiogram revealed left ventricular dysfunction with 38% ejection fraction. In less than 24 hours, we conduct angiography and found total occlusion in Left Anterior Descending (LAD) artery which were then stented in proximal – mid LAD. After revascularization, the patient remained hemodynamically unstable and had recurrent VT, which became more frequent when we titrate inotrope and vasopressor. We decided to perform IABP placement, then the hemodynamic status gradually improved and VT incidence was markedly decreased. The patient was weaned from IABP after 5 days of care and hemodynamic improvement. Patient then discharged with HF therapy, DAPT, and antiarrhythmic medicine.

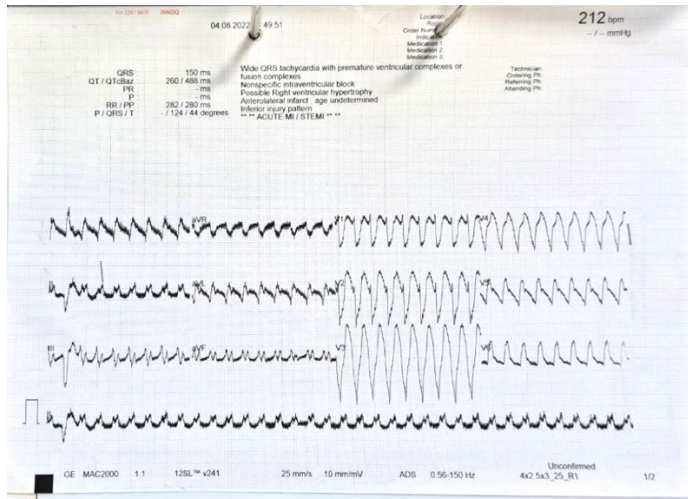
Conclusion: Studies showed no benefit of IABP in clinical outcome and mortality, albeit some benefit in hemodynamic stability in AMICS patients. In this case, IABP improved patient's hemodynamic status after PCI. Failure of various studies to establish the role of device support in AMICS management may have resulted from their more relevant use in other cause and heterogeneity of CS classification criteria.


Keywords : IABP, AMICS, Ventricular Arrhythmia, Heart Failure



Indonesian Journal of Cardiology

Indonesian J Cardiol 2023;44:suppl_A
pISSN: 2830-3105 / eISSN: 2964-7304
doi: 10.30701/ijc.1537





PCI to CTO lesion in Intractable Heart Failure Patient, Is There any Benefit?

F.A. Kusyanto¹, H. Munirwan², T. Heriansyah²

^{1,2} Department of Cardiology and Vascular Medicine, Faculty of Medicine, Universitas Syiah Kuala, Banda Aceh, Indonesia.

Background: A chronic total occlusion (CTO) percutaneous coronary intervention (PCI) is one of the most challenging procedures in interventional cardiology right now. Various angiographic scoring systems are being developed to assess the difficulty of guidewire crossing. The J-CTO score shows how challenging the CTO crossing is.

Case Illustration: We present a case of a 53-year-old male who was submitted to the ER with typical chest pain and difficulty breathing. The patient had a history of prior PCI with a patent stent in the LM and LCx. Echocardiography and cardiac SPECT imaging showed RCA still viable. Based on those findings, we decided to perform PCI. Throughout the PCA procedure JCTO was 3, from PCI procedure we had difficulties to penetrate the lesion. In the end, using backup balloons, the lesion was successfully penetrated and a drug-eluting stent was placed in the RCA. A few months after the pci the patient's condition is getting better. A thorough history check, appropriate imaging techniques, and choosing the right equipment and approach of PCI are vital for the success rate of CTO PCI.

Conclusion: In patients with chronic total occlusion, percutaneous coronary intervention is still a possible option, despite the difficulties. Preparation and the use of angiographic scoring systems, such as the J-CTO score, to estimate the probability of success and the type of approach is essential in the planning of CTO PCI. CTO PCI can reduce the incidence of cardiac death compared to optimal medical therapy in patients with CTO. The yield of complete revascularization for mortality is similar to that of CABG but the rate of short-term attacks is less with PCI. It was further explained that PCI in reducing morbidity and mortality is better than optimal medical administration

Keywords: Chronic Total Occlusion, Percutaneous Coronary Intervention



"Combination of Mechanical Unloading and Pharmacotherapy for Management of Post Infarction Ventricular Septal Rupture" : A Case Report

M. Ferhat¹, A.C. Lubis², K.K. Ilyas³, A.N. Nasution⁴, T.W. Ardini⁵, C.A. Andra⁶

¹Cardiology Resident at Cardiac Center H. Adam Malik Hospital, Faculty of Medicine Universitas Sumatera Utara, Medan, Indonesia

^{2,3,4,5,6}Cardiologist at Cardiac Center H. Adam Malik Hospital, Faculty of Medicine Universitas Sumatera Utara, Medan, Indonesia

Background

Ventricular septal rupture (VSR) is a rare yet serious complication of acute myocardial infarction and leading to ventricular remodeling and subsequent heart failure. Mechanical unloading plays an important role during critical period especially as bridge to definitive treatment in ventricular septal rupture. Pharmacotherapy is another essential modality to prevent deterioration and halting cardiac remodeling. Combining mechanical support and medical agents may help ensure satisfying outcomes.

Case Illustration

A 52 years old male admitted with the chief complaint shortness of breath. 7 days before admission to the hospital, the patient complained of chest pain. 3 days before admission, the patient was taken to the local hospital because of shortness of breath and got hospitalized for 1 day and then referred to Adam Malik hospital for further treatment. Patient diagnosed with recent Anterolateral MI. Echocardiography showed IVS rupture at the apical septum with tunneling morphology 19 mm length, left to right shunt with a diameter of 11-14 mm. Coronary angiography showed total occlusion after Diagonal 1, and 20-30% stenosis at distal OM3. LV graphy showed contrast filling of the LV and RV through the VSR with diameter 6-7 mm. Patient recieve therapy ACE-i, MRA, diuretic, DAPT, and high intensity statin. Low Dose Inotropic were also given to reduce shunting. An Intra-aortic balloon pump (IABP) was inserted for reduce afterload and augmentation of cardiac output on day 13th. PCI was performed on day 17th and percutaneous closure was done on day 21st after MI onset. The patient was discharged 3 days after percutaneous closure in good condition.

Conclusion

Combining mechanical unloading and aggressive pharmacotherapy can help halting cardiac remodelling and a viable option to achieve hemodynamic stabilization allowing a delayed closure of VSR in MI patients and contributing to improved survival.

Keyword : Ventricular septal rupture, Myocardial infarction, Intra-aortic balloon pump, Unloading

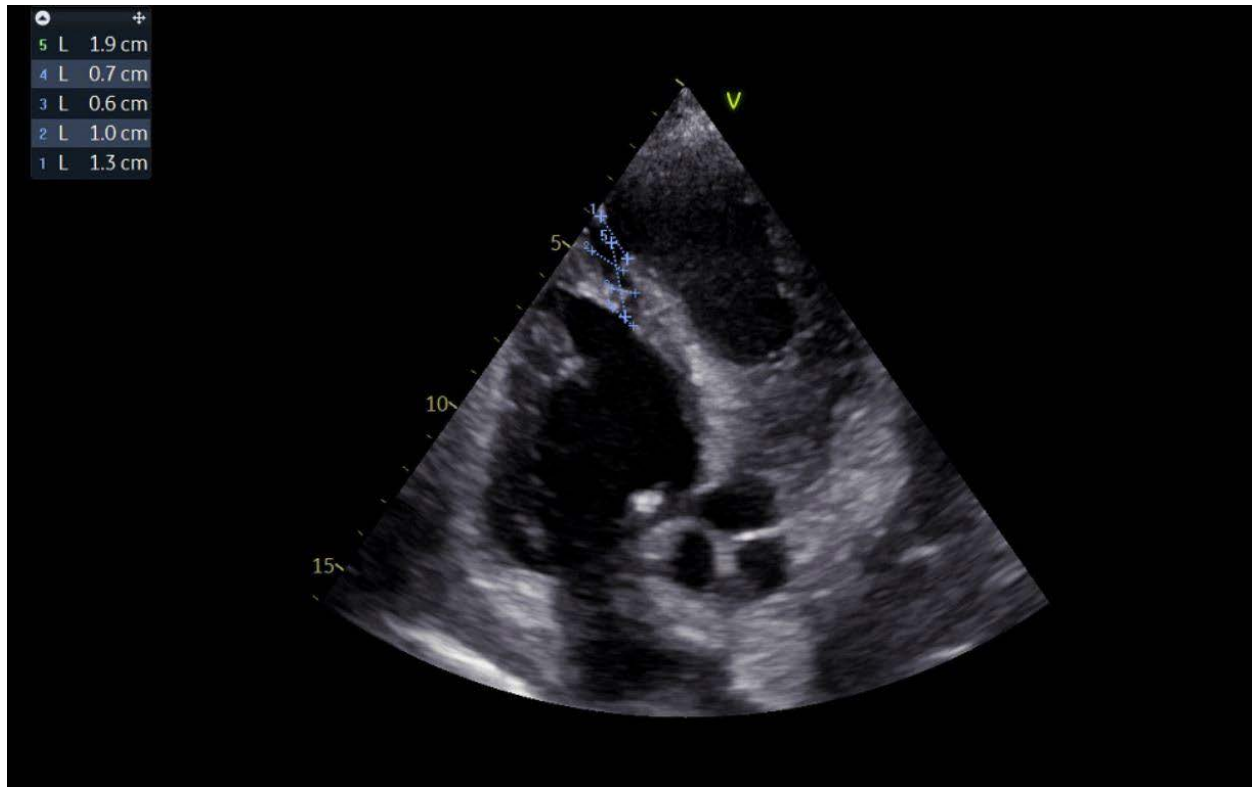



Figure 1 : Echocardiography showed IVS rupture at the apical septum with tunnel form 19 mm length, with a diameter of 11-14 mm.



Considerations in Management of Atrial Septal Defect with Pulmonary Hypertension on A Young Woman: A Case Report of Treat and Repair

F. Napitupulu¹, A.N. Nasution², T.W. Ardini², C.A. Andra²

¹Cardiology Resident, Department of Cardiology and Vascular Medicine, Faculty of Medicine, Universitas Sumatera Utara, Medan, Indonesia

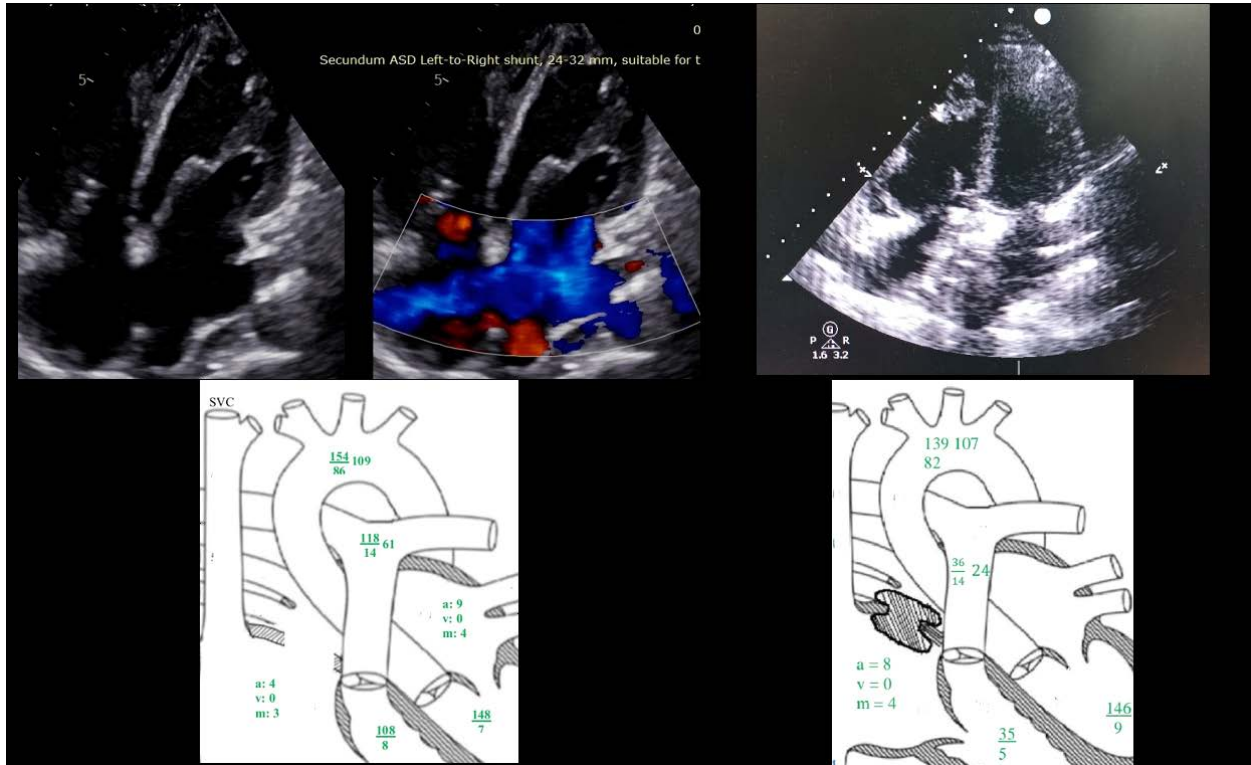
²Cardiologist, Cardiac Center H. Adam Malik Hospital, Medan, Indonesia


Background: Atrial septal defect (ASD) is an adult congenital heart disease that is often found in Sumatera Utara and can occur at every social level. Closure of an ASD that caused functional limitations cannot be done immediately. There is consideration such as the pulmonary arterial hypertension (PAH) which has developed. The ‘treat and repair’ is the method used to treat ASD with PAH and a pulmonary vascular resistance (PVR) > 5WU. In this case, we present a young woman with PVR > 5WU, how we treat her.

Case Illustration: A 27 years old woman was referred to H. Adam Malik Hospital with a history of fatigue, shortness of breath during light activity, and hoarse voice. She was diagnosed by ASD with severe PH based on transthoracic echocardiography (TTE) and right heart catheterization (RHC). Transesophageal echocardiography (TEE) showed secundum ASD 24-32mm, left to right shunt, rims were suitable for transcatheter device closure. Patient took PH therapy sildenafil citrate 3x20mg for two months. Functional class became better. Percutaneous transcatheter closure by Amplatzer Septal Occluder (ASO) guiding TEE with zero fluoroscopy was done. Sildenafil therapy was continued. There was a period of two months without sildenafil due to unavailability. On follow-up, 8 months post closure, World Health Organization Functional Class (WHO-FC) was improved from 2 to 1, voice was soft. TTE showed no residual leakage, no more right atrium (RA) and right ventricle (RV) dilation. RHC showed reduction of mean Pulmonary Arterial Pressure (mPAP): 61 to 24 mmHg, Pulmonary Vascular Resistance (PVR): 6,6 to 4,57 WU, Flow Ratio (FR): 4 to 1,2.

Conclusion: Clinical improvement, high flow to the lungs, and young age women can be considerations not to delay defect closure in ASD with PAH. Longterm follow up is still needed.

Keywords: ASD, PAH, Treat, Repair





"Management Strategy of Paroxysmal Atrial Fibrillation in Pre-excitation Syndrome : A Life-threatening Arrhythmia Case."

M.R. Asepty¹, A.C. Lubis², C.A. Andra³

1 Cardiology Resident at H. Adam Malik Cardiac Center, Faculty of Medicine Universitas Sumatera Utara, Medan, Indonesia

2 Cardiac Electrophysiologist at H. Adam Malik Cardiac Center, Faculty of Medicine Universitas Sumatera Utara, Medan, Indonesia


3 Cardiologist at H. Adam Malik Cardiac Center, Faculty of Medicine Universitas Sumatera Utara, Medan, Indonesia

Background : Atrial fibrillation becomes a potentially lethal arrhythmia when occurred in pre-excitation syndrome, thus requiring further management such as ablation procedure. Rapid ventricular activation from the accessory pathway can lead to ventricular arrhythmia and making atrial fibrillation extremely life-threatening.

Case Illustration : A Male, 54 years old patient was referred to H. Adam Malik Cardiac Center with history of palpitations and weakness which experienced intermittently since 3 years ago. The ECG examination at the previous hospital shown irregular wide QRS complex tachycardia. The 24 Hours Holter ECG Monitoring at the previous hospital found episodes of narrow-complex Atrial Fibrillation. While at H. Adam Malik Cardiac Center, the ECG shown sinus rhythm with delta wave morphology . EASY-WPW algorithm was used to predict the location of the accessory pathway, which suggestive of an accessory pathway in the posterolateral mitral annulus. The patient was immediately scheduled for electrophysiology study and ablation procedure, then fusion waves morphology was found which suggestive of an accessory pathway that located in the posterolateral mitral annulus, and then the ablation procedure was done in that location. After the ablation procedure, the ECG shown sinus rhythm with no pre-excitation morphology was found.

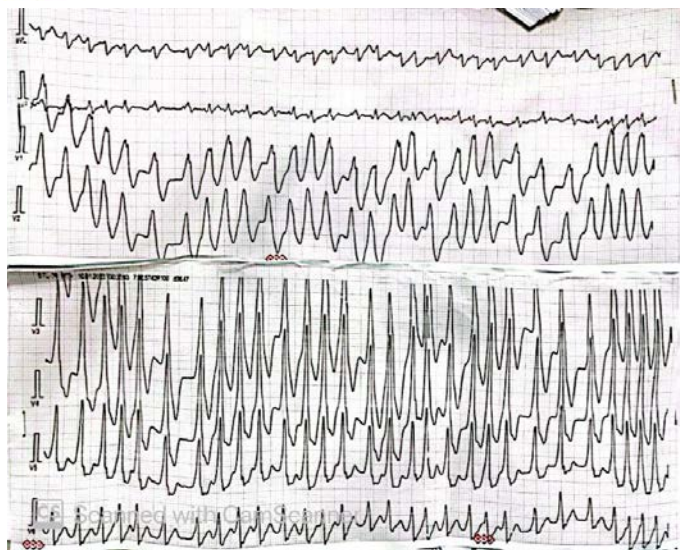Conclusion : Appropriate diagnosis, approach, and management strategy of patients with atrial fibrillation with pre-excitation is vital in preventing patients from falling into life-threatening condition.


Keywords : Pre-excitation Syndrome, Wolff-Parkinson-White Syndrome, Ablation.



Indonesian Journal of Cardiology

Indonesian J Cardiol 2023;44:suppl_A
pISSN: 2830-3105 / eISSN: 2964-7304
doi: 10.30701/ijc.1537





NON ST-ELEVATION MYOCARDIAL INFARCTION WITH TOTAL OCCLUSION OF THE CORONARY ARTERY : CASE REPORT

D. Khairunnisah¹, C.A. Andra², A.N. Nasution³, H. Hasan⁴

¹ Cardiology Resident, Department of Cardiology and Vascular Medicine, Faculty of Medicine, Universitas Sumatera Utara, Medan, Indonesia; ^{2,3,4} Cardiologist, Department of Cardiology and Vascular Medicine, Faculty of Medicine, Universitas Sumatera Utara, Medan, Indonesia

BACKGROUND

Total occlusion of infarct-related coronary artery is an uncommon finding for Non ST-Elevation myocardial infarction (NSTEMI) during routine angiography, and usually found in STEMI cases. NSTEMI patients with Total occlusion of the artery (TOA) prevalence was 29% and usually characterized by higher cardiovascular risks, such as diabetes, active smoker, and hypertension. NSTEMI patient with TOA is associated with greater extent of necrosis and worsen prognosis, and thus, must be treated with emergent reperfusion therapy. Early reopening of a completely occluded coronary artery reduces myocardial damage, prevents heart failure, and improves clinical outcomes.

CASE ILLUSTRATION

We present a patient admitted to the hospital with symptoms of chest pain since 3 days ago. He had previous history of uncontrolled hypertension and smoking. His ECG showed ST-segment depression in lead II, III, AVF and V4-V6. Chest X-Ray revealed Cardiomegaly, and high troponin level. Echocardiography revealed akinesia inferoseptum segment, hypokinesia other segment and decreased left ventricular systolic function. Then, he underwent trans-radial approach coronary angiography and the result was total occlusion of the right coronary artery (RCA). Stents were implanted to the lesion. No complication after the procedure and he was discharged several days later. The patient then planned to continue therapy at the outpatient clinic.

CONCLUSION

We reported a case of NSTEMI patient with TOA. NSTEMI patients should undergo strict evaluation for signs indicating possible TOA and then performed reperfusion therapy as needed.

KEYWORD

NSTEMI, Coronary Angiography, Total occlusion of the coronary artery.

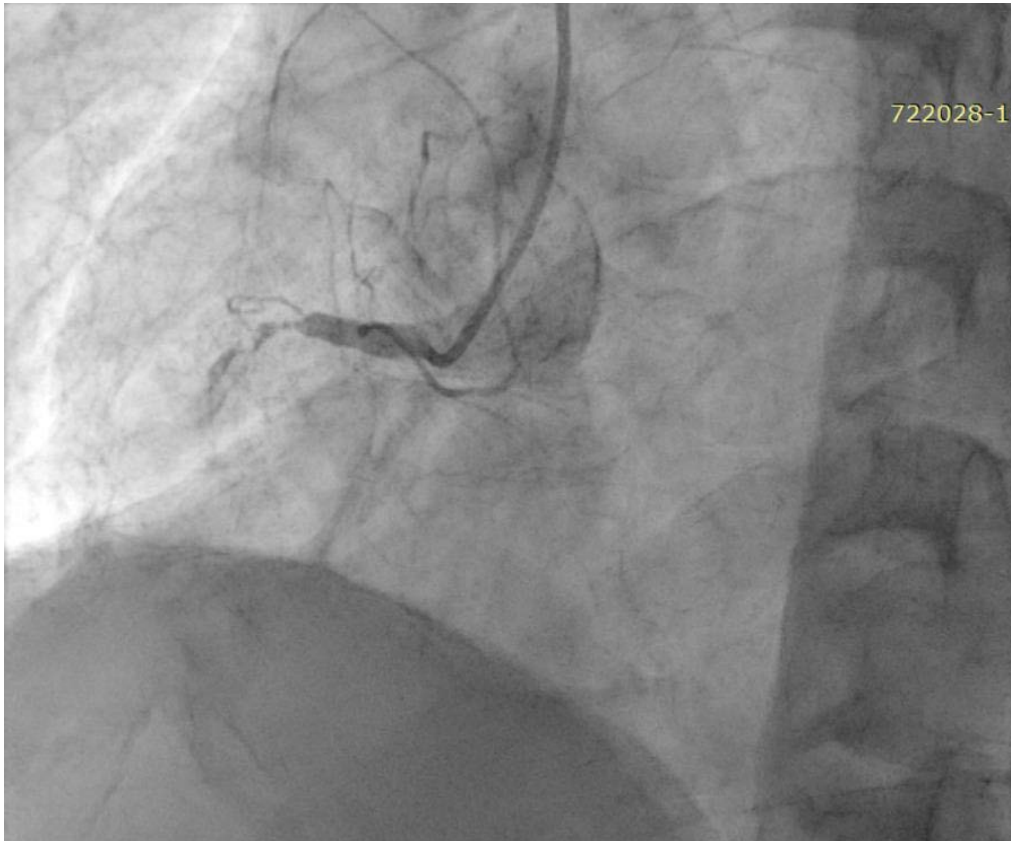



Figure 1. Coronary Angiography of the patient showed Total Occlusion of the Right Coronary Artery.



Acute limb ischemia – Effectivity of Percutaneous Intra-arterial Thrombolysis as a First Choice: A Case Report

M.H.M. Putra¹, T.B. Haykal², Y.F. Siregar², A.C. Lubis², C.A. Andra², K.K. Ilyas²

¹ *Cardiology Resident, Department of Cardiology and Vascular Medicine, Faculty of Medicine, Universitas Sumatera Utara, Medan, Indonesia*

² *Cardiologist, Department of Cardiology and Vascular Medicine, Faculty of Medicine, Universitas Sumatera Utara, Medan, Indonesia*

Background

Acute limb Ischemia (ALI) was characterized by sudden decrease limb perfusion, which threatens limb viability and had symptoms for less than 14 days. The incidence of ALI is estimated to be 15 cases per 100,000 population per year, and constitutes 10% -16% of all vascular cases. In the case of ALI, the decrease in tissue perfusion occurs suddenly and results in a rapid and threatening ischemia process and there is not enough time for the formation of new blood vessels as collateral to compensate for the perfusion decrease. Therefore rapid detection and proper handling are very influential on patient prognosis.

Case Illustration

A 65-year-old female patient came with pain on her left foot for 1 week during activity and worsen within 2 days where pain also occurs at rest. Pallor and poikilothermia of the left foot was also found. Patient has controlled type 2 diabetes with insulin treatment, a controlled hypertension, CAD post PCI and paroxysmal atrial fibrillation. Left foot saturation was 86% until 90%. Her ECG showed sinus rhythm and echocardiography showed good LV systolic function with 60% EF. doppler ultrasound showed monophasic waves from common femoral artery until dorsalis pedis artery, thrombus and plaque at SFA, arterial flow was not found in popliteal, posterior tibial artery and dorsalis pedis artery. She was diagnosed with Grade I ALI on left leg. Arteriography showed occlusion in DFA and SFA sinistra. Percutaneous Intra-arterial Thrombolytic (PIAT) was done with streptokinase 100.000 IU for 4 hours via femoral catheter continued with 5000IU/hour for 24 hours was given. Two days later, a follow-up arteriography showed no thrombus at SFA and with good flow in SFA.

Conclusion

PIAT is the appropriate treatment in grade I and IIA ALI with no contraindications for thrombolytic and there is sufficient time for reperfusion to preserve tissue viability. Streptokinase was one of the drugs of choices for PIAT. Within 3 days of treatment, the patient showed a good response to PIAT.

Keywords: acute limb ischemia, percutaneous intra-arterial thrombolysis, streptokinase




Indonesian Journal of Cardiology

Indonesian J Cardiol 2023;44:suppl_A
pISSN: 2830-3105 / eISSN: 2964-7304
doi: 10.30701/ijc.1537

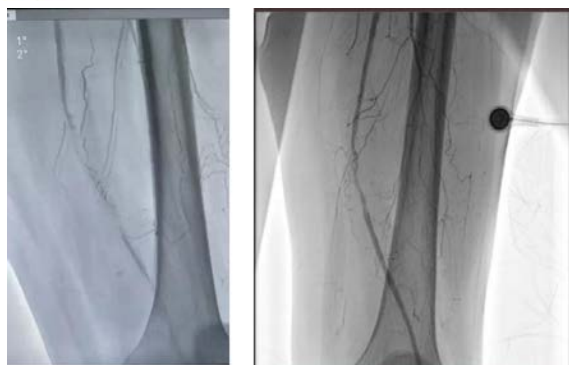

Figure 1 Arteriography, at admission (Left); post PIAT (Right)



Unraveling the Cause of Angina in Patient with Rare Malignant Right Anomalous Coronary Artery From the Opposite Sinus with Stenotic Lesion

Y. Adani¹, P.P.R. Gharini¹, N. Taufiq¹

Department of Cardiology and Vascular Medicine, Dr Sardjito Hospital, Yogyakarta/Faculty of Medicine, Public Health and Nursing, Universitas Gadjah Mada, Yogyakarta, Indonesia

Background:

Anomaly of coronary artery from the opposite sinus (ACAOS) is a rare congenital disease (0.2-1.2%) with right coronary artery arise from left coronary sinus (R-ACAOS) is the most common form. Approximately 20% has interarterial course (malignant) and may experience life-threatening manifestations. The mainstay of therapy according to the guidelines is surgical revascularization. Meanwhile, stenotic lesion in the coronaries made this case complicated to acknowledge the source of angina. From a pathophysiological point of view, percutaneous coronary intervention may be able not only to remove the lateral compression of the interarterial segment, but also to treat stenosis.

Case Illustration:


A 62 year-old female came with the main complaint of recurrent chest pain with comorbidities diabetes, dyslipidemia, and menopause. Vital signs and physical examinations within normal. Both electrocardiography and echocardiography examination showed no signs of ischemia and ventricular systolic function was good. However, stress test showed a positive ischemia response. A coronary computerized tomography angiography (CTA) was carried out with the results of interarterial R-ACAOS and severe stenosis in all three coronary vessels. Coroangiography results were accordance with the CTA report. Integrated modality using fractional flow reserve (FFR)-dobutamine, intravascular ultrasound (IVUS)-dobutamine, or ischemia non-invasive imaging are the tools to determine hemodynamic relevance of an apparent malignant ACAOS. Unfortunately, those modalities were not performed due to unavailability. Based on guideline in patients with significant hemodynamic changes related to interarterial R-ACAOS, who have significant stenosis, the preferred option is coronary artery bypass surgery. Otherwise, stent implantation might become the treatment of choice.

Conclusion:

Our report aims to seek the best management strategy of malignant R-ACAOS with stenotic lesions. Strong evidence of ischemia must be present before opting for surgery. A simultaneous approach of using dobutamine stress and FFR/IVUS might help in the decision-making in patients with coronary anomalies.

Keywords:

R-ACAOS, interarterial course, PCI, CABG, FFR-dobutamine, IVUS-dobutamine



Intermittent AIVR in MI with Non-Obstructive Coronary Arteries: What Is the Mechanism?

S. Haidar¹, E. Maharani², F. Hidayati²

¹Resident of Department of Cardiology and Vascular Medicine, Faculty of Medicine, Public Health and Nursing, Gadjah Mada University, Yogyakarta, Indonesia

²Staff of Department of Cardiology and Vascular Medicine, Faculty of Medicine, Gadjah Mada University

Background:

Accelerated idioventricular rhythm (AIVR) is a slow ventricular rhythm usually seen in reperfusion phase after myocardial infarction (MI). Presence of AIVR without MI is rarely discussed.

Case illustration:

A 53-year-old patient complained of chest pain and was frequently diagnosed with non-ST elevation MI in district hospital. Echocardiography showed inferoseptal hypokinesia, but coronary angiography only showed slow flow in RCA which conclude diagnosis of MI with non-obstructive coronary arteries. Patient was referred to our hospital for further investigation. Since ECG showed slurred upstroke of QRS complex resembling delta wave, ambulatory ECG was done. Interestingly the result showed complete right bundle branch block and intermittent AIVR with rate 80 bpm. The patient was asymptomatic during AIVR. Cardiac magnetic resonance imaging (CMR) showed subendocardial fibrosis in basal-apicoinferior segment, which still doesn't explain the patient's symptom. However, this incidental finding begs further questions, does intermittent AIVR correlate with CMR finding or is there a concealed accessory pathway that allows AV re-entry? We proceed by planning electrophysiology study to determine the presence of accessory pathway and to test inducibility of sustained arrhythmias.

Discussion:

AIVR is believed to be automatic and usually readily overdriven by faster supraventricular pacemakers. Because ventricular and sinus rate are often similar, isorhythmic dissociation is a common finding. AIVR is mostly seen in reperfusion phase after ACS. It's also seen in patients with other conditions, such as myocardial disease, hypertensive, rheumatic, and congenital heart disease. Meanwhile, preexcitation may mimic idioventricular rhythms. There was one case report about a patient with WPW in which electrophysiology study showed idioventricular rhythm. The opposite can also occur when presence of accessory pathway simulates ventricular complex. Electrophysiology study is needed to confirm the diagnosis.

Conclusion:

There are other aetiologies of AIVR besides MI. Further tests are needed to confirm diagnosis and appropriate management.

Keyword: AIVR, preexcitation syndrome



Indonesian Journal of Cardiology

Indonesian J Cardiol 2023;44:suppl_A
pISSN: 2830-3105 / eISSN: 2964-7304
doi: 10.30701/ijc.1537



Transient AV Block during VSD Device Closure Procedure: to Stop or Not to Stop?

P. Indrihapsari^{1,2}, V. Yogibuana^{1,2}

¹Department of Cardiology and Vascular Medicine Faculty of Medicine Universitas Brawijaya,

²Dr. Saiful Anwar General Hospital

Background:

Ventricular septal defect is the most common congenital cardiac defect accounting for more than 20% of all CHDs.¹ Perimembranous ventricular septal defects (PMVSDs) in infants and young children are the most common cause of a hemodynamically significant ventricular septal defect (VSD).² Percutaneous closure of VSDs is performed under general anesthesia and with fluoroscopic and transesophageal echocardiographic guidance is now a choice.³ Complete atrioventricular block (cAVB) has been deemed a rare complication after transcatheter closure for ventricular septal defect (VSD). However, this serious event appears to be underrecognized and is worth being investigated further.

Case Illustration:


A 19 years old male, presented with incidental finding of perimembranous VSD during an army selection. He was 170 cm tall and weighed 60 kg. Physical examination was suggestive of VSD. Baseline 12-lead electrocardiogram (EKG) showed normal sinus rhythm with no conduction delays. Transthoracic 2D echocardiography showed a 6-7 mm perimembranous VSD with normal pulmonary arterial diameter and all of the cardiac chambers. All pulmonary veins were draining into left atrium. Transcatheter device closure of VSD was carried out under general anesthesia with KONAR-MF VSD Occluder No 10-8 mm (Lifetech). During the procedure, a complete atrioventricular block was evident both on monitoring screen and echocardiography screen. It followed by chest discomfort, and resolved shortly after 1 mg of atropine administration, with stable haemodynamics. The procedure was resumed, and the device was placed with no evidence of residual VSD from the transesophageal echocardiography, nor recurrent atrioventricular block after the procedure.

Conclusion:

Atrioventricular block could be a risk while performing percutaneous VSD closure. Conduction system injury from mechanical trauma/compression by the delivery system or device causing acute intraprocedural atrioventricular block has a reasonable probability of early resolution. Immediate and long-term follow-up is essential in patients who have had these devices implanted.

Keywords:

Ventricular septal defect, Atrioventricular block, percutaneous device closure



Transcatheter Closure of Very Tortuous Patent Ductus Arteriosus Using Snaring Technique and Balloon Sizing: A Case Report

R. Rasaki¹, R. Prakoso², T. Heriansyah¹, M. Muqsith¹

¹Department of Cardiology and Vascular Medicine, Faculty of Medicine, Universitas Syiah Kuala, Banda Aceh, Indonesia.


²Department of Cardiology and Vascular Medicine, Faculty of Medicine, Universitas Indonesia, National Cardiovascular Center Harapan Kita, Jakarta, Indonesia

Background: Patent ductus arteriosus (PDA) is one of the most common congenital heart diseases in premature infants. PDA causes volume overload in the left heart and may lead to congestive heart failure, atrial arrhythmia, or pulmonary arterial hypertension. Recently, transcatheter device closure of PDA is an established and widely accepted treatment modality in adolescents, children, and older infants.

Case Illustration: We reported a 17-year-old boy was referred to the National Cardiovascular Center Harapan Kita hospital from South Sumatra with a chief complaint of dyspnea on exertion in the past 2 years. He had a history of recurrent respiratory tract infections when he was a baby. He was born spontaneously, premature at 32 weeks of gestation, with a birth weight of 2300 grams. On physical examination, we found a normal first heart sound and a normal split of the second heart sound with a continuous murmur in the upper left sternal border radiating to the left infraclavicular. The transthoracic echocardiography showed a PDA with the left to right shunt. We diagnose the patient with patent ductus arteriosus according to clinical findings, and transthoracic echocardiography and planned to perform transcatheter PDA closure. In the cath lab, transesophageal echocardiography evaluation showed the PDA morphology was very tortuous. So, we decided to perform transcatheter PDA closure using snaring technique and balloon sizing guided by transesophageal echocardiography minimal fluoroscopy technique. The procedure was performed successfully without major complications.

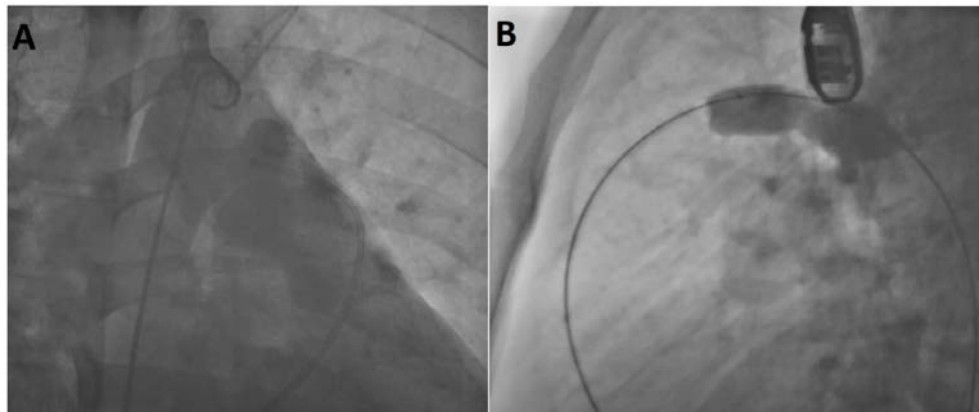
Conclusion: Transcatheter device closure of a very tortuous patent ductus arteriosus is feasible and safe with minimal fluoroscopy time. Careful patient selection and good imaging quality are essential for procedural success and avoiding complications.


Keywords: *Patent Ductus Arteriosus, Very Tortuous, Transcatheter Closure*



Indonesian Journal of Cardiology

Indonesian J Cardiol 2023;44:suppl_A
pISSN: 2830-3105 / eISSN: 2964-7304
doi: 10.30701/ijc.1537





TRANSCATHETER ATRIAL SEPTAL STENTING IN IDIOPATHIC PULMONARY ARTERIAL HYPERTENSION: A CASE REPORT

T.F. Hadi¹, R. Prakoso², T. Heriansyah¹, M. Muqsith¹

¹*Department of Cardiology and Vascular Medicine, Faculty of Medicine, Universitas Syiah Kuala, Zainoel Abidin General Hospital, Banda Aceh, Indonesia*

²*Department of Cardiology and Vascular Medicine, Faculty of Medicine, Universitas Indonesia, National Cardiovascular Center Harapan Kita, Jakarta, Indonesia*

Background : The treatment of severe idiopathic pulmonary arterial hypertension (IPAH) remains challenging, despite improved medical options to address this life threatening condition. Atrial septostomy is used as an additional therapeutic strategy for IPAH-associated right heart failure.

Case Illustration : A 36-year-old female was referred to National Cardiovascular Center Harapan Kita hospital with a chief complaint dyspnea on exertion, swelling in abdomen and lower extremity in the past 10 years. She has diagnosed with idiopathic pulmonary arterial hypertension since 8 years ago. She was planned to undergo transcatheter closure of PDA guided by TEE and fluoroscopy technique. However, before the procedure, TEE evaluation was carried out, obtaining RA-RV dilation, LV smallish, D-shape (+), good RV contractility, reduce LV contractility, intact IAS, IAS bulging to the left, TR mild (+), PR (-), LVOT VTI 9 cm. We performed atrial septal stenting with omnilink elite 10 mm x 29 mm x 135 cm. We performed TEE evaluation after procedure. It revealed stent in stowed position, flow (+), LVOT VTI 12 cm. Post-procedure, descending aorta pressure was 93/53 mmHg and peripheral saturation was 92%. The fluoroscopy time in this procedure was just approximately 11 minutes without major complications. The patient was discharged after 24 hours and the patient did not show any symptoms at the time of subsequent follow-up.

Conclusion : Transcatheter atrial septal stenting in idiopathic pulmonary arterial hypertension is feasible and safe. It reduced symptoms and increasing quality of life.

Keywords: Atrial Septal Stenting, Idiopathic Pulmonary Arterial Hypertension

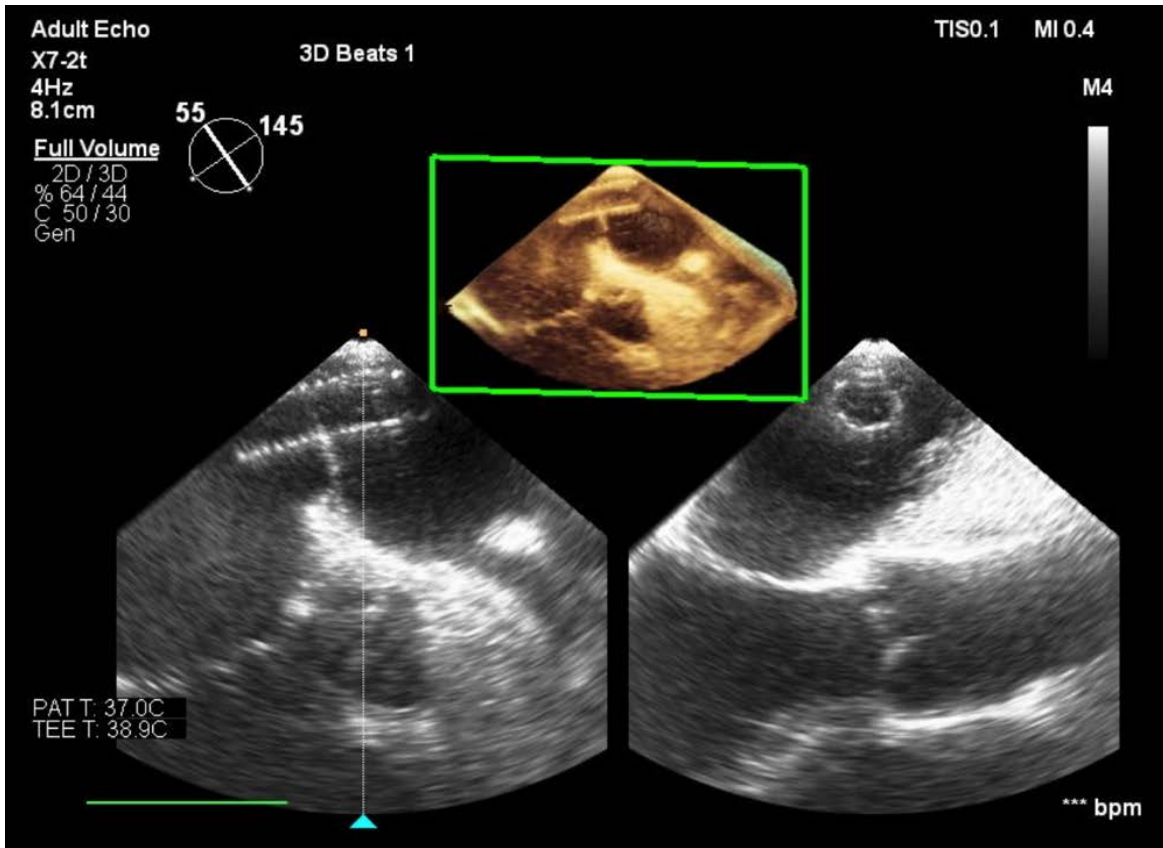



Figure 1. Omnilink elite 10 mm x 29 mm x 135 cm in stowed position



Electrophysiology Study and Ablation in Atypical Atrioventricular Nodal Reentrant Tachycardia (Slow-Slow)

N.G. Wara¹, P.N.P. Limen¹, B.M. Setiadi¹

¹Department of Cardiology and Vascular Medicine, Faculty of Medicine, Sam Ratulangi University, Manado

Background: Atrioventricular nodal reentrant tachycardia (AVNRT) was a subtype of supraventricular tachycardia (SVT). AVNRT was further divided into typical and atypical AVNRT. Atypical AVNRT occurred in 6-7% of all AVNRT cases, and Slow-Slow Pathway was rarer of the two subtypes.

Case illustration: A male patient, 60 years old, came to the Emergency Department with chief complaint of episodic palpitation since 1 month before admission. 2 weeks prior, patient was admitted to Prof RD Kandou General Hospital with the same complaint, and diagnosed with AV Nodal Re-entry Tachycardia (AVNRT). Physical examination was found to be unremarkable. ECG show paroxysmal supraventricular tachycardia rhythm (150 beats per minute), no P-wave visible, with normal axis. Laboratory examination was unremarkable aside from hyperuricemia (uric acid 8.5 mg/dL). Chest X-ray was within normal limits. Echocardiography result show mild regurgitation in mitral and pulmonic valve, other findings were within normal limits. Based on results from history-taking, physical examination, and diagnostic studies during current and previous admission, patient was diagnosed with AVNRT, controlled hypertension, hyperuricemia, and dyspepsia syndrome. Patient was given treatment of candesartan 8 mg, lansoprazole 30 mg/12 hours, allopurinol 100 mg, and atorvastatin 20 mg. Patient underwent Electrophysiology Study with result showing atypical AVNRT with slow-slow pathway, and had successful ablation of slow pathway afterward. After the procedure, patient was observed in the ICCU for the first 24 hours, then transferred to the common ward, and got discharged when condition confirmed to be stable.

Conclusion: Slow-slow AVNRT occurs because patient had an additional slow pathway contributing to re-entry phenomenon. Electrophysiology study and radiofrequency ablation show good outcome in this case.

Keywords: Atypical AVNRT, Electrophysiology Study, Ablation

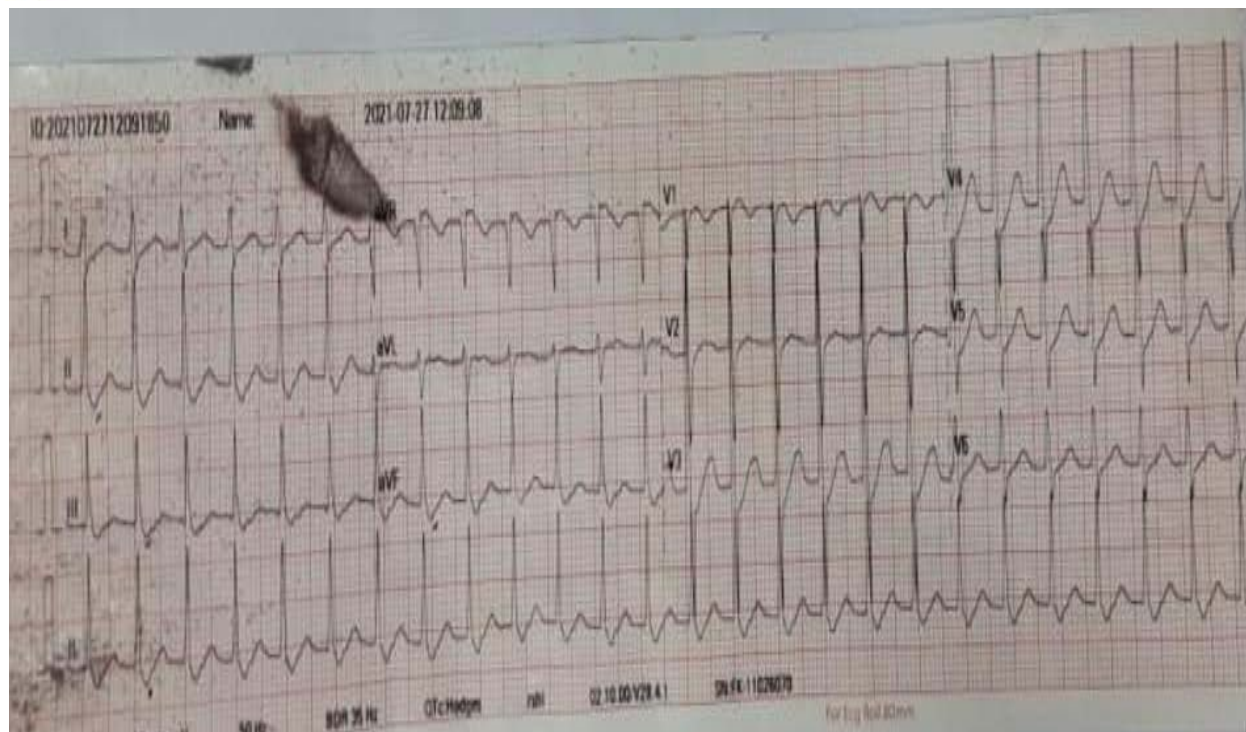


Figure 1 ECG during AVNRT episode



ATRIAL FIBRILLATION WITH THROMBOCYTOPENIA, UPPER GASTROINTESTINAL BLEEDING AND ELEVATED LIVER FUNCTION TEST IN OLD MALE WITH HIGH THROMBOEMBOLIC RISK: A CASE REPORT

D.A. Yafi¹, A.M.Z Ismail², A. Purnawarman², T. Heriansyah², M. Muqsith²

1) Faculty of Medicine, Universitas Syiah Kuala, Banda Aceh

2) Zainoel Abidin General Hospital, Banda Aceh, Indonesia

ABSTRACT

Background: Thrombocytopenia is estimated to account for 6-24% of patients with AF. Previous studies have reported that similar rates of stroke and death were observed in thrombocytopenic and normocytopenic patients. The mean platelet volume (MPV) also serves as an independent predictor of stroke and left atrial thrombus in patients with AF. Of note, several cases of NOAC-induced thrombocytopenia have been reported in various literature.

Case Illustration: A 78-year-old male with difficulty of breathing in the last ten days ago. Patient also reported feel easily tired in the last few years. Patients look pale, he had black-colored stool on his defecation last week. Upon examination revealed conjunctiva anemic and rales in basal lung. An electrocardiogram showed atrial fibrillation with a rapid ventricular response of 149 bpm. Blood work at first admission revealed anemia (10.3 gr/dL), thrombocytopenia ($65 \times 10^3/\text{mm}^3$), high MPV (13.2 fL) and unexplained high INR (2.49). Chest X-ray showed cardiomegaly and transthoracic echocardiogram (TTE) revealed all chamber dilatation with left and right ventricular systolic dysfunction. Patient had moderate mitral, tricuspid, and aortic regurgitation. The patient was treated with fresh frozen plasma on hospital day 1st to correct his high INR. Patient was started with 10mg of Rivaroxaban with intensive monitoring of serial platelets and bleeding diathesis. Serial platelets showed no improvement, liver function test elevated (SGOT/SGPT 201/185 U/L) and bruises appeared in IV-line catheter installation area. Rivaroxaban was switched to Clopidogrel on hospital day 2nd due to liver problems and for stroke prevention.

Conclusion: The need for anticoagulation in patients with thrombocytopenia is an intricate problem. Decision to administer or withhold anticoagulation depends on the assessed risks of thrombosis and bleeding. Several principles should be considered when deciding to start anticoagulation: 1) a low platelet count does not protect from thrombosis; and 2) in general, thrombotic complications are more dangerous than bleeding complications.

Keywords: Atrial Fibrillation, High Bleeding Risk, Anticoagulation, Thrombocytopenia, Mean Platelet Volume.

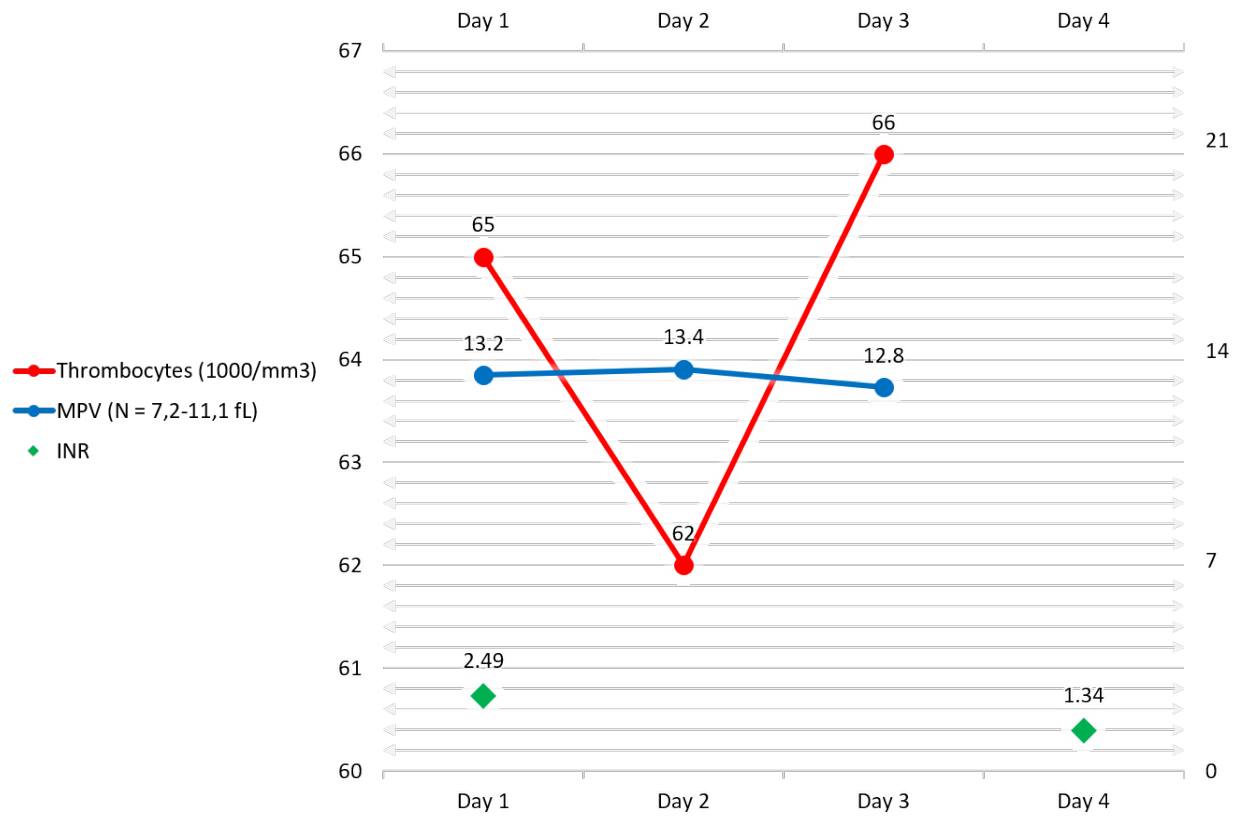



Figure 1. Patient's Trend of Thrombocytes, Mean Platelet Volume (MPV) and INR.



WELLENS' SYNDROME : PCI IS THE TREATMENT GOAL AND SHOULDN'T BE DELAYED

Taufiqurrahman¹, M. Fitra¹, T. Herianyah¹, M. Muqsith¹

¹Department of Cardiology and Vascular Medicine, Faculty of Medicine, Universitas Syiah Kuala, Banda Aceh, Indonesia

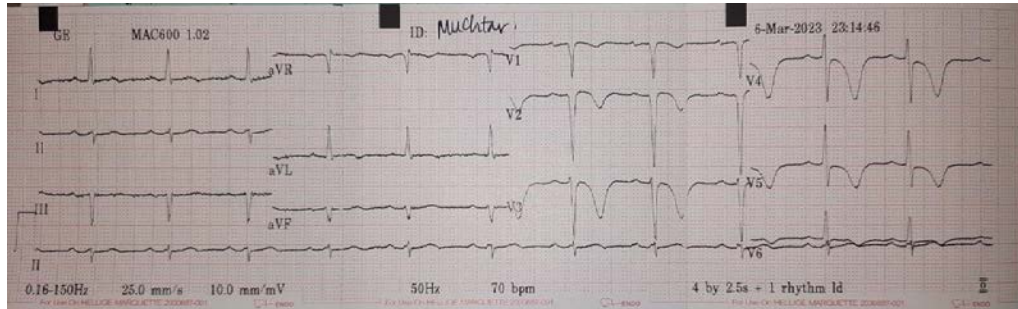
Background : Wellens' syndrome is a clinical manifestation of coronary artery disease developed as NSTEMI-ACS. It describes a pattern of electrocardiographic changes, particularly deeply inverted or biphasic T waves in leads V2-V3, that is highly specific for critical proximal stenosis of the left anterior descending coronary artery. It is important to recognize this ECG patterns because patients with wellens' syndrome are at high risk for impending large anterior wall acute myocardial infarction.

Case Illustration : A 57 years old male presented to ER with chief complaint of chest pain since 2 weeks prior admission. Chest pain was felt like a heavy sensation and radiated to the back and accompanied with cold sweat. Chest pain was felt again around 5-6 hours before admission to ER but patient was pain-free when he presented to our hospital. He was a known case of uncontrolled hypertension. On presentation, the vital signs were measured with BP 164/79 mmHg, HR 85 beats/minute and RR 20 breathes/minute. Physical examination was normal. ECG showed deep T wave inversion in V1-V6. Troponin T did not elevated. Echocardiography showed normal ventricles function (LVEF 71%, TAPSE 2.5 cm). Patient was diagnosed with Wellen Syndrome type B and treated as UAP and then he was sent to ICVCU for intensive monitoring. The next day patient was sent to cathlab to performed corangiography and revealed a subtotal stenosis of proximal LAD and installed 1 stent DES of LAD. The next day patient discharged with good condition.


Conclusion : Early recognizing from electrocardiography pattern of wellens' syndrome is pivotal due to it can predict critical stenosis in proximal LAD. Wellens' syndrome is very possibly to developed into STEMI, therefore early detection and prompt management is the key to prevent complication and mortality. Corangiography with PCI had to be immediately performed for further management.

Keyword : *Wellens' syndrome, Proximal LAD, PCI*

Figure 1.



ECG showed LAD with deep T wave inversion in V1-V6



Tetralogy of Fallot With Labiopalatoschizis : Let's Total Correction or Not?

F.H. Alkaf¹, A. Priyatno²

¹*Faculty of Medicine, Diponegoro University, Semarang, Indonesia*

²*Pediatric Department, Faculty of Medicine Diponegoro University, Dr Kariadi Hospital, Semarang*

Background

Tetralogy of Fallot is the most common cyanotic heart defect with an incidence of 5% to 10% of all CHD events. The four hallmark features of the malformation that consists of an interventricular communication, also known as a ventricular septal defect, obstruction of the right ventricular outflow tract, override of the ventricular septum by the aortic root, and right ventricular hypertrophy.

Case Illustration

An 8-year-old boy with Tetralogy of Fallot, polydactyly, history of 3-step surgery to the correction of labiopalatoschizis. With chief complaints of cyanotic, the body weight is difficult to gain, get tired easily, have speech disorders, and tend to squat in daily life as well. Saturation oxygen was 66%/65%/71%/74%. S1 normal, S2 weakened, systolic ejection murmur grade III/6 with punctum maximum at the left parasternal line SIC II. With nutritional status 16.5 kg, 117 cm, WAZ: -3.54, HAZ: -2.06, BMI: -3.42. Impression: Poor nutrition, very less weight. Laboratory haemoglobin 21.8 g/dL and hematocrit 68.7%. Chest x-ray CTR 48%, booth shaped, narrowed retrosternal space, RV cardiomegaly. EKG Sinus rhythm, 81x/min, RAD, RVH. Echo results: overriding aorta <50%, VSD malalignment, RV hypertrophy, severe PS with PG 75 mmHg. He was a successful total correction procedure and the condition was improved.

Conclusion

The management of patients with TOF has its own challenges both for diagnosis and management because not all areas have adequate human resources or equipment. It is now expected that the prognosis of TOF patients will improve substantially because of the advances in surgical and medical management that have occurred over the last few decades. As for all patients with congenital heart defects, the management of patients with tetralogy of Fallot does not end with complete improvement. Follow-up to the cardiologist needs to be carried out for further evaluation.

Keywords : Tetralogy Of Fallot, Labiopalatoschizis, Malnutrition, Total Correction

Coronary Artery Ectasia Presenting with STEMI Inferior, How About Invasive And Non-Invasive Therapy; A Case Report

Jefri.D.S¹, Haris M², M.Muqsith², M.Ichsan²

¹Faculty of Medicine, Syiah Kuala University/ Zainoel Abidin Hospital, Banda Aceh, Indonesia;

²Faculty of Medicine, Syiah Kuala University/ Zainoel Abidin Hospital, Banda Aceh, Indonesia;

Background: Clinical manifestations of coronary Artery Ectasia(CAE) are heterogeneous, and often it is occasionally recognized during coronary angiography or computed tomography (CT). However, CAE may become clinically overt through different possible scenarios, including ACS, effort angina, and exercise-induced ischemia. The optimal management of patients with CAE is largely unknown.

Case Illustration: a 59-year-old man was admitted to emergency department with complaint of chest pain since 3 Hours before admission. Patient has also history of Hypertension and Heavy Smoker. With blood pressure was 220/120 mmHg, pulse 42 beats per minute and respiratory rate was 22 times per minute. Electrocardiography (ECG) showed: Sinus rhythm, QRS rate 46 bpm ECG showed ST Elevation in lead II, III, and AVF (*Figure 1*). During percutaneous coronary intervention with result CAD 1 VD, total distal occlusion with thrombus (Grade V), impression of an aneurysm with a diameter of 8-10 mm in RCA(*Figure 2,a*), POBA has been done at RCA(*Figure 2,b*), good results with suggest double antiplatelet for 12 months, drip eptifibatide 12.0 ml/hours.

Discussion: Percutaneous treatment of CAE is a valuable option in patients with suitable anatomical and clinical features. However, PCI of ectasia lesions presents several challenges, starting from lack of specific indications, in patients even though a stent is not installed, the PCI results are still good and there are no complications after the patient is discharged.

KEYWORD: *Ectasia, STEMI, PCI*

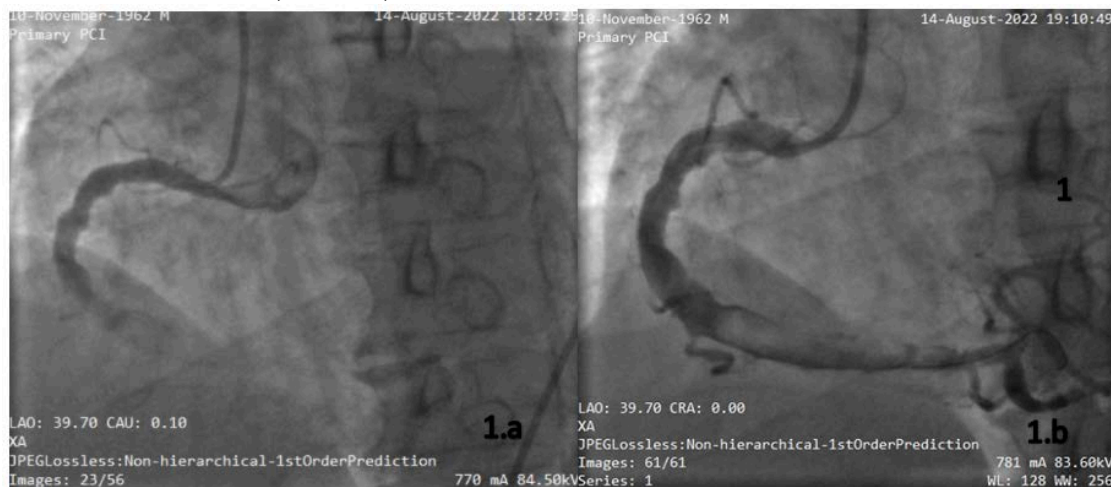




Figure 1.a. from PAC Total distal occlusion with thrombus (Grade V), impression of an aneurysm with a diameter of 8-10 mm,
1.b.POBA has been done at RCA, good results

A Case Of Fascicular Ventricular Tachycardia Previously Thought As Abberant SVT

R. Faradilla¹, M. Muqsith², T. Heriansyah³

¹ Cardiology Residen, Medical Faculty, Universitas Syiah Kuala

^{2,3}Department of Cardiology and Vascular Medicine, Medical Faculty, Universitas Syiah Kuala

ABSTRACT

Background: The majority of ventricular tachycardia (VT) episodes that are seen in emergency rooms are ischemic in nature. Fascicular VT is a rare kind of VT. Its distinctive electrocardiographic (ECG) pattern of wide-complex tachycardia (WCT) with a right bundle branch block (RBBB) and left axis deviation is caused by a re-entry circuit mechanism in the Purkinje fibers of this benign VT.

Case illustration: A 63-year-old female presented to emergency room (ER) for evaluation of palpitations, pleuritic chest pain and tightness. Physical examination were severe tachycardia. The remaining physical examination was unremarkable. Electrocardiographic (ECG) showed regular monomorphic ventricular tachycardia at 210 bpm with a wide QRS, complete right bundle branch block pattern and total posterior fascicular block. The patient was assessed as aberrant supraventricular tachycardia (SVT) and received a biphasic external electrical shock of 50 Joule, which was unsuccessful. However, later it was reassessed as fascicular VT and given 150 Joule shock, which reverted to sinus rhythm with multifocal premature ventricular contraction (PVC). Patient was also treated with verapamil and referred for catheter ablation.

Discussion: Fascicular ventricular tachycardia may occur in structurally abnormal heart and it could be life threatening. Fascicular ventricle tachycardia is frequently misdiagnosed as aberrant supraventricular tachycardia. Fascicular ventricle tachycardia is characterized by: atypical V1 morphology, QRS width ≤ 140 ms, R/S Ratio in V6 ≤ 1 , and positive aVR. Verapamil has become a cornerstone of treatment. Verapamil works by activating the slow inward calcium channel.

Conclusion: Prompt recognition of this arrhythmia is necessary, 2 lead ECG shows a right bundle branch block picture with left axis deviation, a diagnosis of fascicular tachycardia should be considered. Despite, this type of VT is typically sensitive to verapamil, when symptoms are severe or when medical treatment is inadequate or poorly tolerated, catheter ablation is a recommended treatment option.

Keywords: Fascicular Ventricle Tachycardia, aberrancy SVT, wide tachycardia, cardioversion

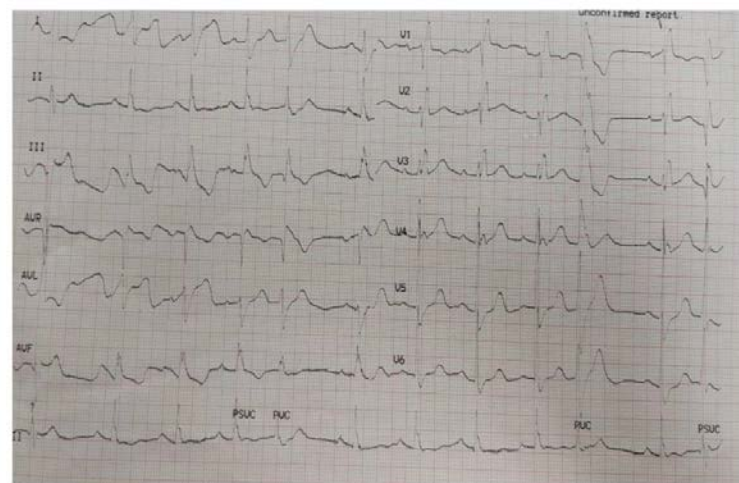
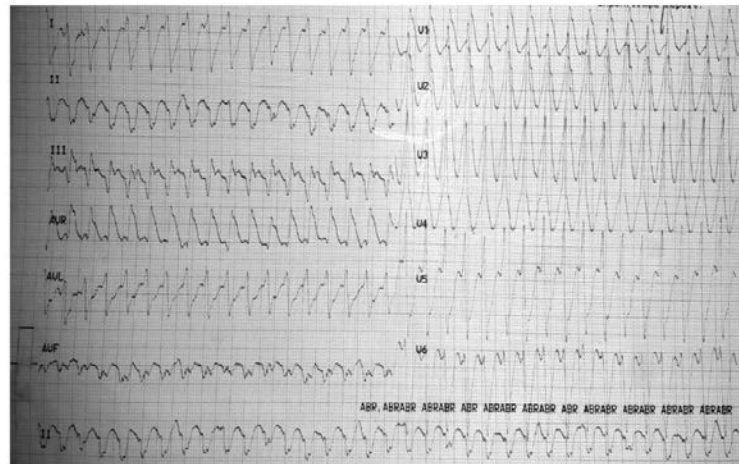



Figure 1. (Top) ECG indicating tachycardia as evidenced by a rate of 210 bpm with a wide QRS. Figure 2. (Bottom) ECG after synchronized defibrillator 150 J, showing sinus rhythm, and complete RBBB, multifocal PVC



Routine Interventional Closure of Patent Ductus Arteriosus after PH Treatment: A Case Report

M.A. Amanta¹, A.N. Nasution², C.A. Andra²

1 Cardiology Resident at H. Adam Malik Cardiac Center, Faculty of Medicine Universitas Sumatera Utara, Medan, Indonesia


2 Cardiologist at H. Adam Malik Cardiac Center, Faculty of Medicine Universitas Sumatera Utara, Medan, Indonesia

Background: Patients with congenital heart disease (CHD) now live well into adulthood because of advances in intervention techniques, improvements in medical management, and the development of novel therapeutic agents. Patent ductus arteriosus (PDA) occurs in 5% to 10% of all CHDs, excluding premature infants. PDA is an uncommon anomaly in adult patients, as it is usually identified in childhood. Patients can now receive therapies via nonsurgical and transcatheter techniques. In patients presenting with severe Pulmonal Hypertension (PH), transcatheter PDA closure combining with PH treatment will improve outcome of the procedure. There are few studies relating surgical and nonsurgical treatment to long-term prognosis in adults with patent ductus arteriosus.

Case Illustration : A Male, 30 years old, patient was referred to H. Adam Malik Cardiac Center with chief complain was previous history of shortness of breath. From clinical finding, ECG, chest x-ray, echocardiography, and cardiac catheterization, he was diagnosed PDA with severe PH. He underwent PH treatment sildenafil citrate for 1 year more. After 1 year, he was planned to undergo cardiac catheterization, and showed changes such as; FR: 3,65 □ 4,71 ; PAR: 7.88 □ 6,76 ; PARI: 5.47 □ 5. The estimation size of duct is 10.3 in isthmus diameter and 44.5 mm in ampulla. The procedure was done with amplatzer ductal occluder (ADO) size 20-22mm and placed successfully. A decrease in mPAP was found, 73 □ 56 mmHg. Sildenafil therapy is continued. After ADO, the patient felt more better than before.

Conclusion: In general, for the older adult with a PDA, transcatheter closure is the preferred approach due to the calcification that is routinely seen in the older adult aorta. Thus, any approach to close an adult PDA in the catheterization laboratory is likely to be of lower risk and safer.

Keywords: PDA, ADO, PH.



LA Myxoma; A Benign Primary Cardiac Tumor

S. Satwikajati*, A.F. Rahimah**

*Residen of Cardiovascular, Universitas Brawijaya, Saiful Anwar Hospital, Malang

** Cardiologist at Cardiovascular Departement of Saiful Anwar Hospital, Malang

Background

Cardiac myxoma (CM) is the most prevalence of adult benign primary cardiac tumor that derived from mesenchymal cell precursor which are most commonly found in the left atrium (LA) attached by a stalk to the fossa ovalis. Clinical manifestations of CMs may vary from asymptomatic cases to unexpected sudden death. Intracardiac flow obstruction may occur and potentially life-threatening. The diagnosis of a CM is mostly done with echocardiography. On echocardiogram, a myxoma presents as a echogenic polypoid or papillary mobile mass within the atrial cavity remaining attached to the interatrial septum through a stalk. Their prognosis is excellent when treated with prompt surgical resection.


Case Illustration

We reported three cases of LA myxoma. One case of fatal obstructive LA myxoma in female 39 years old who dead before the surgery, one case of successful surgery an obstructive LA myxoma in woman 52 years old, and one non obstructive LA myxoma that concomitant with coronary artery disease in male 77 years old.

Conclusion

Only timely diagnosis and prompt surgery can reduce the morbidity and mortality of cardiac myxoma patients.

Keywords : Myxoma, Cardiac tumor, Obstruction, Echocardiography



Left Main Coronary Artery Spasm (LMCAS): Not Always Manifest as Chest Pain R. Abimanyu¹, F. Habib², C.A. Andra²

¹Cardiology Resident at H. Adam Malik Cardiac Center, Faculty of Medicine Universitas Sumatera Utara, Medan, Indonesia

²Cardiologist at H. Adam Malik Cardiac Center, Faculty of Medicine Universitas Sumatera Utara, Medan, Indonesia

Background

Left Main Coronary Artery Spasm (LMCAS) is defined as a sudden vasoconstriction of Left Main coronary artery causing vessel occlusion or near occlusion. LMCAS commonly manifests as chest pain and transient ST elevation by coronary vasospasm, and generally follows a benign clinical course. Rarely, syncope induced by ventricular arrhythmia associated with transient myocardial ischemia can be developed by LMCAS. If the cause of syncope is not correctly diagnosed, patients are at risk of recurrent syncope. In particular, syncope without chest pain is an uncommon manifestation of coronary vasospasm. Thus, as in this case, it can be missed as the cause of syncope.

Case Illustration


A 49-year-old female patient with no significant cardiac history presented to the emergency department with history of syncope and palpitation. Initial Electrocardiogram (ECG) was within normal limit and stress tests are negative for inducible ischemia. Two dimensional (2D) echocardiogram showed no regional wall motion abnormalities with good biventricular function. There was no mitral or tricuspid regurgitation. During coronary-angiography showed a ventricular arrhythmia in ECG monitor. Conventional contrast coronary angiogram showed ostio-proximal LMCA 60 to 70% stenosis, with proximal left anterior descending coronary artery (LAD) 50% stenosis, and right coronary artery as normal. Percutaneous coronary intervention (PCI) was planned with intravascular ultrasound (IVUS) guidance. LMCA was normal in different views. Normalization of LMCAS suggests that there was completely only spasm in LMCA. On 24-hour Holter monitoring showed normal limit and there was no syncope and palpitation. Arrhythmia was not found, with minimal and maximal heart rate was 53 bpm and 69 bpm, respectively.

Conclusion

This case demonstrates that syncope and ventricular arrhythmia could be related to LMCAS. We missed the diagnosis of LMCAS during the first admission because the patient did not complain of chest pain and we did not identify abnormal ST-segment elevation. Thus, syncopal patient of LMCAS without typical chest pain may be misdiagnosed as in this case. Therefore, in the event of an unexplained syncope, it is important to interpret Holter monitoring carefully and to consider coronary spasm provocation test for the diagnosis of LMCAS, if clinically indicated.

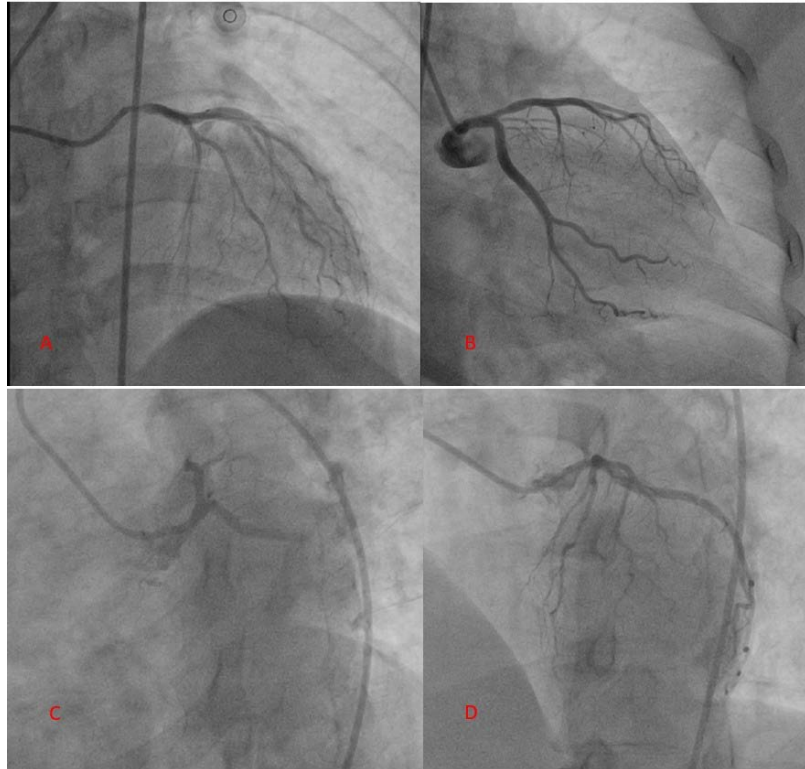
Keywords


LMCAS, Syncope, Ventricular Arrhythmia, Holter monitoring.



Indonesian Journal of Cardiology

Indonesian J Cardiol 2023;44:suppl_A
pISSN: 2830-3105 / eISSN: 2964-7304
doi: 10.30701/ijc.1537





Percutaneous Coronary Intervention of Infarct Related Artery vs Non Infarct Related Artery in Patient with Cardiogenic Shock

A.S. Pratama¹, N.Y. Kusumawardhani²

¹Faculty of Medicine, Padjadjaran University, Bandung, Indonesia

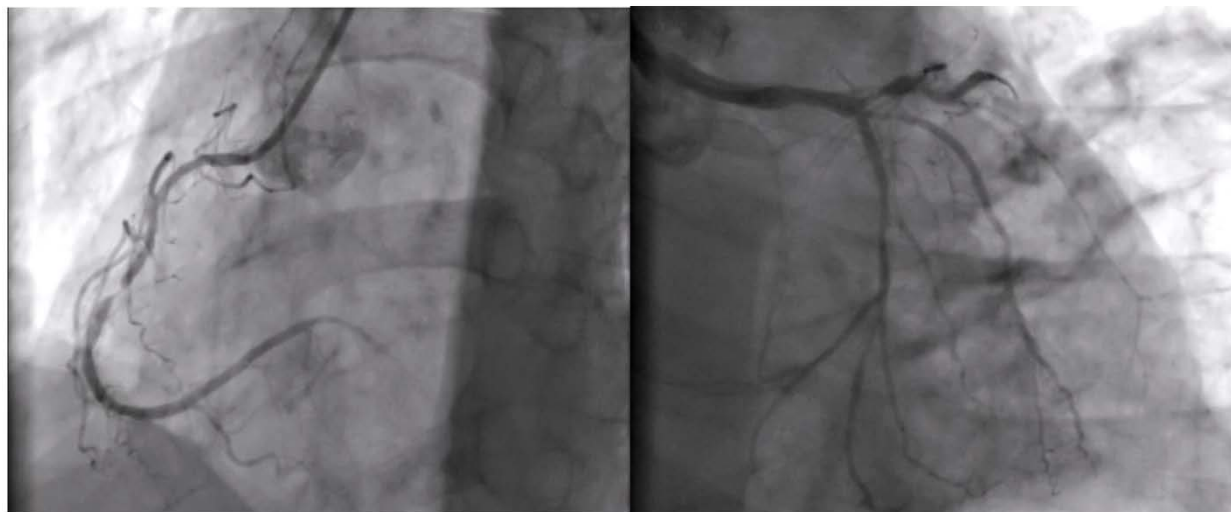
²Departement cardiology and Vascular Medicine, Hasan Sadikin Hospital, Bandung, Indonesia

Background : Multivessel disease (MVD) was observed 40-65% of patients with STEMI. Non-infarct related artery stenosis (non-IRA) in patient with MVD was associated with increased mortality and MACE. Complete revascularization in STEMI with cardiogenic shock patients was recommended by guidelines but the supporting evidence has been scarce and it was only based on expert consensus considerations.

Case Illustration : 63 years old male was admitted due angina. Onset 8 hours prior to admission. Patient appeared to be restless, hypotension with poor hypoperfusion on admission. ECG showed extensive anterior STEMI, CRBBB. Patient was diagnosed with extensive anterior STEMI with cardiogenic shock. After stabilization with inotropes, patient underwent cardiac catheterization. Angiographic findings showed acute total occlusion at LAD with severe calcification and significant lesion on ostial – distal LCx and ostial – distal RCA. PCI was performed in the proximal LAD as infarct related artery. On the next day, patient experienced another episode of angina. ECG monitor showed total AV block rhythm and patient was hemodynamically unstable. Another PCI procedure was performed to RCA. However, patient experienced cardiac arrest intra procedure, CPR was performed but to no avail.

Conclusion : Reperfusion of culprit is main treatment in the STEMI patients, although multivessel PCI in stable STEMI patients can be considered in non-complex lesions. Culprit only approach should be performed in hemodynamic unstable patients such as cardiogenic shock. Complete revascularization still have a significant benefit in terms of mortality but the existence of MVD itself has a poorer outcome regardless appropriate approach to the patient.

Keywords : STEMI, Cardiogenic Shock, Multi vessel disease, PCI, Non Infarct related artery



Rupture Sinus of Valsalva Aneurysm Associated With a Ventricular Septal Defect: The Importance of Intraoperative Transesophageal Echocardiography

D.P. Sejati¹, D.W. Anggraheni¹, Noormanto²

¹Department of Cardiology and Vascular Medicine, Dr Sardjito Hospital, Yogyakarta/Faculty of Medicine, Public Health and Nursing, Universitas Gadjah Mada, Yogyakarta, Indonesia

²Department of Pediatric Medicine, Dr Sardjito Hospital, Yogyakarta/Faculty of Medicine, Public Health and Nursing, Universitas Gadjah Mada, Yogyakarta, Indonesia


Background:

Sinus of Valsava Aneurysm (SOVA) is a rare heart defect and is an acquired heart defect and/or a congenital heart defect. This case has a prevalence of 0.09% in the general population and only about 1-3.5% of congenital heart defects. The rupture sinus of Valsava aneurysm (RSOVA) occurs most often towards RV(60%), then to RA(29%), LA(6%), LV(4%), and Pericardium(1%). Complications from a rupture that occurs suddenly can occur hemodynamic disorders that can lead to acute heart failure. The diagnosis of RSOVA can be established by multimodality imaging.

Case Illustration:

A 16-years-old male patient with an unconfirmed report of VSD since infancy, came with his parents to the outpatient clinic RSUP Sardjito, with the chief complaint of shortness of breath during sports activities and at rest. TTE showed RSOVA of Right Coronary Cuspis (RCC) into the right ventricle (RV) with a classic sign of *Windsock Appearance*, further confirmed by TEE. We further decide to proceed to for repair of the RSOVA. Unexpectedly, the preprocedural TEE revealed a Left to Right high PMO VSD that coexisted with the its RSOVA. Therefore, the surgical team proceeded to VSD closure along with the repair of RSOVA and it went successfully. During follow-up, the condition was improved with no complications and no residual defects was observed on TTE.


Discussion and Conclusion:



The prevalence of a coexisting VSD and SOVA is about 30-60%, in this case, the patient was late to come to our hospital and was diagnosed with RSOVA and High PMO VSD, and then we successfully repaired both lesion, with a good outcome. Performing TEE with and without sedation sometimes gives different flexibility in obtaining views, especially when certain maneuver is needed. Carefully caution is needed in looking at the results of multimodality imaging, especially if there were discrepancies in results to make a diagnosis of RSOVA with coexisting lesions.

Keywords:

rupture sinus of valsava aneurysm, ventricular septal defect, intraoperative transesophageal echocardiography



Patient with Patent Ductus Arteriosus and Infective Endocarditis Complicated with Worsening Left Ventricular Dysfunction Following Surgical Intervention

A.N. Nurman¹, C.J. Cool¹


¹Department of Cardiology and Vascular Medicine, Faculty of Medicine, Universitas Padjadjaran, Dr. Hasan Sadikin General Hospital, Bandung, Indonesia

Background: Patent ductus arteriosus (PDA) is a congenital heart disease that can cause left ventricular (LV) volume overload. PDA closure has been reported to cause deterioration of LV function.

Case Illustration: A 23-year-old female was admitted with recurrent fever three months prior to arrival. She had history of PDA but never had routine follow-ups. She had cardiomegaly with continuous murmur grade III/VI at the 2nd left intercostal space. Her electrocardiography (ECG) showed sinus tachycardia and left ventricular hypertrophy. Transthoracic echocardiography (TTE) showed PDA (7-8 mm) continuous flow, left ventricular ejection fraction (LVEF) 46% with mild global hypokinetic, and multiple vegetations at main pulmonary artery. Blood culture showed positive for *Staphylococcus hominis*, *Streptococcus anginosum*, and *Staphylococcus epidermidis*. After two weeks of antibiotics administration, blood culture remained positive despite reduced vegetations size. Vegetation evacuation and PDA ligation were performed successfully. However, TTE evaluation showed worsening systolic function (LVEF 39%) without vegetation and residual PDA shunt. She received heart failure medications and was discharged in stable condition. Ten months thereafter, TTE evaluation showed improved systolic function (LVEF 44%). The deterioration of LV function can be caused by sudden reduction of LV volume after PDA closure which reduces muscle fibers stretch and decreases LVEF. Another explanation is increased afterload because LV ejects blood only to high-resistance systemic circulation after PDA closure. Several parameters, such as large PDA size, reduced preoperative LVEF, low fractional shortening, and high left ventricular end-diastolic diameter, have been shown to predict LV dysfunction after PDA closure. After closure, LV reverse remodelling can occur, resulting in improved LV function.

Conclusion: PDA closure can cause deterioration of LV function. There are several parameters that can help to predict LV dysfunction. The LV dysfunction is mostly reversible and can take months to fully recover.

Keywords: *Infective Endocarditis, Patent Ductus Arteriosus, Left Ventricular Dysfunction*



Appropriate Management of Simultaneous Acute Cardio-Cerebral Infarction: Are We There Yet?

T.B. Prakoso¹, S. Sungkar², M.F. Ahnaf², Retnaningsih³

¹*Faculty of Medicine, Diponegoro University, Semarang, Indonesia*

²*Department of Cardiology and Vascular Medicine, Kariadi Hospital, Semarang, Indonesia*

³*Department of Neurology, Kariadi Hospital, Semarang, Indonesia*

Background

Both acute ischemic stroke (AIS) and acute myocardial infarction (AMI) are life-threatening medical diseases with a short therapeutic window and a poor prognosis if not treated quickly. Management of both AIS and AMI at the same time is challenging. A delayed intervention of one infarcted zone for the other could result in irreversible morbidity, disability, and even death.

Case Illustration

A 48 years old woman came to ER with a chief complaint of chest pain, difficulty speaking, and had weakness in the right limb that she never felt before 27 hours before being admitted. The ECG was sinus tachycardia with RBBB-type ST elevation in the anterior lead. Her blood lab results showed leukocytosis and increased troponin levels. The chest x-ray showed cardiomegaly. The head CT-Scan revealed extensive infarction with vasogenic edema in the left temporal-parietal-occipital lobe. She was assessed as evolved STEMI anterolateral and non-hemorrhagic stroke. The patient was admitted to ICCU and got dual antiplatelet (DAPT) therapy, heparin as an anticoagulant, and antibiotics. After 5 days of treatment in the ICU, chest pain was reduced, weakness of the right limb improved and she was able to speak with limited vocabulary.

Conclusion

Currently, there are no clinical trials or consensus guidelines for the management of CCI. It is necessary to identify the role of antiplatelet and thrombolytic drugs and a combination of percutaneous coronary and intravascular treatments of the brain. With current limited knowledge, the management approach needs to be individualized.

Keywords : *Stroke, Myocardial Infarction, Cardio-Cerebral Infarction*



A Rare Entity Of Right-Sided Infective Endocarditis as a result of Uncorrected Ventricular Septal Defect: A Case Report

I. Munawarah¹, T. Heriansyah¹, Novita¹

1) *Department of Cardiology and Vascular Medicine, Faculty of Medicine,
Universitas Syiah Kuala,
Zainoel Abidin General Hospital, Banda Aceh, Indonesia*

ABSTRACT

Background: Right-sided infected endocarditis (IE) has a lower prevalence and lower fatality rates as compared to left-sided IE. Infections of implantable cardiac devices, central venous catheters, and misuse of intravenous substances are commonly associated to right-sided IE. Congenital heart disease (CHD) are very less common to result in right-sided IE, among those, ventricular septal defects (VSD) has the highest percentage of up to two percent.

Case illustration: A 26-years-old male was presented to the emergency department with malaise, fever, fatigue and palpitation. The patient was diagnosed with CHD since a young age, but had refused surgical correction. Physical examination showed normal vital signs, abnormal auscultation: loud pansystolic murmur was heard at the lower left sternal border, systolic ejection murmur was heard in the upper left sternal border, and rales at the base of both lungs. Transthoracic echocardiography showed perimembranous VSD with left-to-right shunt and 24×10 mm vegetation on the septal leaflet of the tricuspid valve with mild tricuspid regurgitation. Heart failure treatment was given to the patient, IE was treated with ampicillin sulbactam 1 g t.i.d and gentamycin 80 mg b.i.d despite the blood culture results showed no bacteria were found. Uncorrected VSD is a predisposing factors of IE. In addition to the left-to-right shunt VSD contributes to the increased blood flow through pulmonary artery, promoting pathologic pulmonary vascular shear stress and circumferential stretch. This high flow causes endothelial disruption in the turbulence loci and triggers the vegetation formation during bacteraemia. The endothelial disruption facilitates fibrin deposition and aggregation, subsequently forming the vegetation.

Conclusion: Despite the patient's blood culture showed negative result, patient was still diagnosed with IE based on Modified Duke's Criteria. Common pathology of the right-sided IE, which proposes pathogen into the body, does not apply to this patient

Keywords: right-sided infective endocarditis, uncorrected ventricle septal defect, vegetation

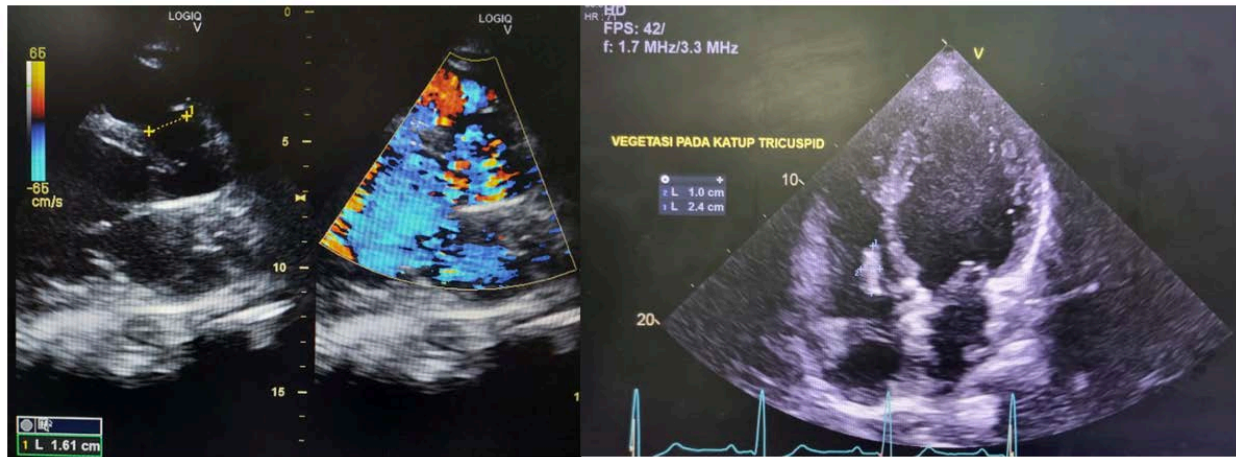



Figure 1. VSD Perimembranosus with flow L to R Shunt (left) and vegetation in septal leaflet of tricuspid leaflet (right).



PALPITATION IN YOUNG AND HEALTHY FEMALE : A CASE SERIES OF WOLFF-PARKINSON-WHITE SYNDROME

A. Izzuddin¹, T. Heriansyah², M. Muqsith²

1) *Cardiology Resident, Faculty of Medicine, Universitas Syiah Kuala, Banda Aceh.*

2) *Department of Cardiology and Vascular Medicine, Faculty of Medicine, Universitas Syiah Kuala*

ABSTRACT

Background: Wolff-Parkinson-White (WPW) syndrome refers to the presence of an overt (manifest) Accessory Pathways (AP), thus resulting in the so-called pre-excitation, in combination with usually recurrent tachyarrhythmias.

Case Illustration: *Case 1:* A 27-year-old female referred to ER with a chief complaint of shortness of breath that occurs since 2 hours. She had also experienced pre-syncope event that occurred earlier that day. Symptoms included intermittent dizziness, lightheadedness, weakness, and palpitations of a one-hour duration. Currently, she is pregnant with a gestational age of 8 months. Her ECG showed Delta wave at lead V1-V6, III, and aVF. One day after admission, she had an episode of tachycardia. Patient then treated with vagal maneuver, but the rhythm was not converted. We continued with IV Digoxin 0.5 mg, and the rhythm was converted to sinus completely. *Case 2:* A 31-year-old female referred to ER with a chief complaint of palpitation that occurs since 12 hours ago. Symptoms included intermittent dizziness, lightheadedness, and weakness. Her previously ECG showed a narrow complex tachycardia with retrograde P waves in II, III, aVF, and in V4 to V6. Patient treated with IV diltiazem, and after the rhythm converted, her ECG showed Delta wave at V2-V6, II, aVF.

Conclusion: The hemodynamic and electrophysiological changes facilitate the development of arrhythmias. Early diagnosis and adequate multidisciplinary management are key factors to avoid complications.

Keywords: Palpitation, Wolff-Parkinson-White Syndrome, Tachycardia, Accessories Pathway

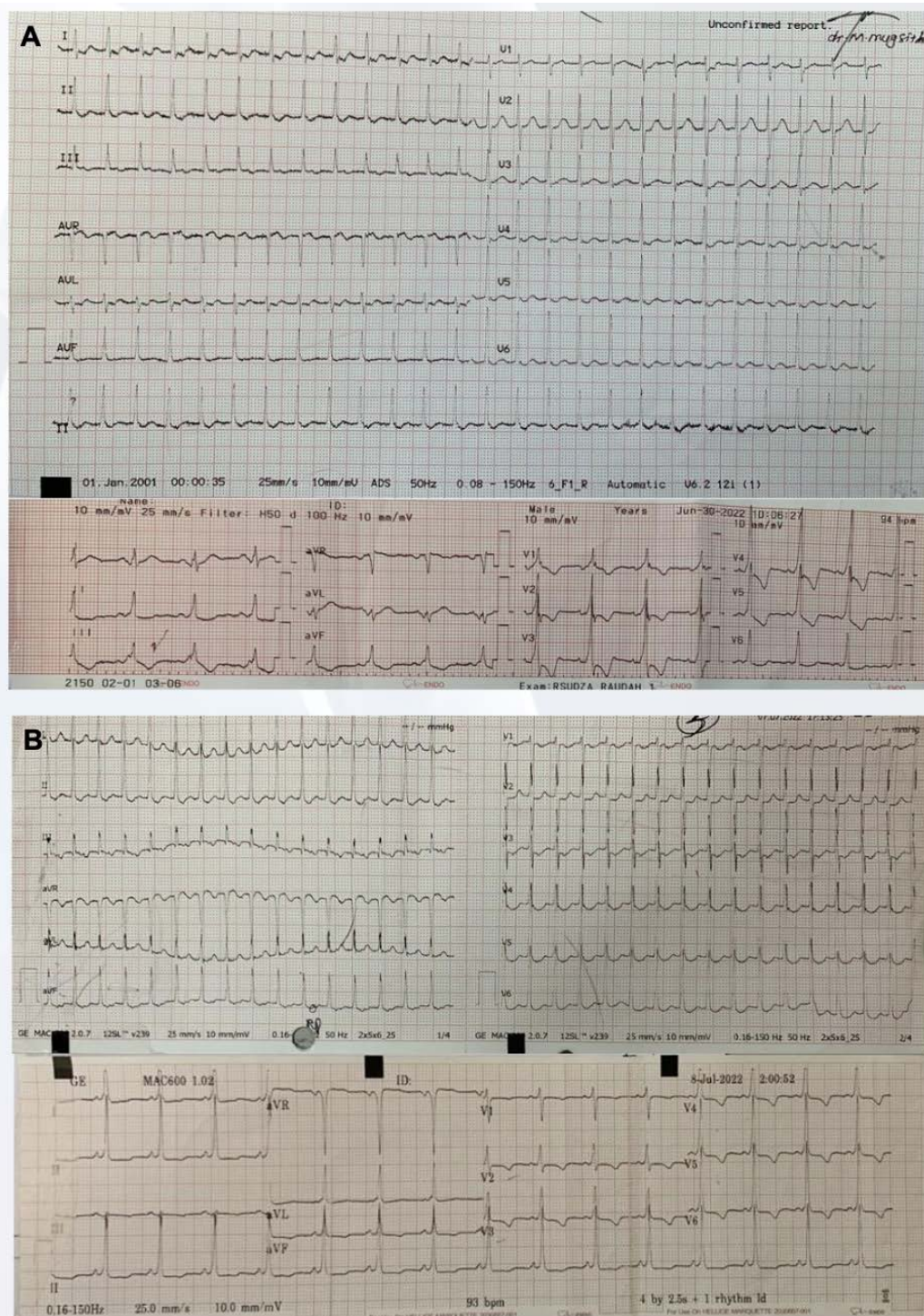



Figure A. Case 1; Left-Sided AP in Type A WPW Syndrome,
 B. Case 2; Right-Sided AP in Type B WPW Syndrome



ST ELEVATION MYOCARDIAL INFARCTION INFERIOR AFTER PCI WITH SMALL VESSEL AT RIGHT CORONARY ARTERY, WHAT SHOULD WE DO?

E. Mizwar¹, A.M.Z Ismail¹, A. Purnawarman¹, T. Heriansyah¹

1) Department of Cardiology and Vascular Medicine, Faculty of Medicine, Universitas Syiah Kuala, Zainoel Abidin General Hospital, Banda Aceh, Indonesia

Background: Cardiovascular diseases (CVDs) represents 31% of all global deaths. Acute Coronary Syndrome (ACS) constitute approximately 7 million deaths per year. Approximately 30% of ACS caused by ST Elevation Myocardial Infarction (STEMI). STEMI after Percutaneous Coronary Intervention (PCI) is completely rare and not yet reported.

Case Illustration: A 54-year-old woman was admitted to the hospital for elective PCI because of a history of recurrent chest pain since the previous 3 months. She had not previously undergone PCI because the onset was more than 12 hours and she was stable, so the patient was planned to undergo PCI in the next 3 months. The patient was admitted with a diagnosis of stable angina pectoris ec. Coronary Artery disease, acute on Chronic Kidney disease and hypertension. Lab results showed improvement in kidney function with serum creatinine 2.2 mg/dl. After corangiography, the results were CAD 2 VD with 70-80% stenosis in the proximal mid on the left anterior descendent (LAD) and small vessels with 80% stenosis on the right coronary artery (RCA). PCI 3 DES was performed in LAD. 6 days after PCI, she complained of severe chest pain. ECG showed ST elevation in II, III, AVF and reciprocal ST depression in I-AVL. We decided to perform fibrinolytic procedure using 1.5 million IU of streptokinase with close hemodynamic monitoring. After that, complaints of chest pain decreased and ST elevation decreased. she was discharged after hemodinamically stable and no chest pain.

Conclusion: STEMI management after PCI with small vessels has not been widely reported, fibrinolytics can be considered for daily practice.

Keywords: STEMI, small vessel, PCI, fibrinolitik

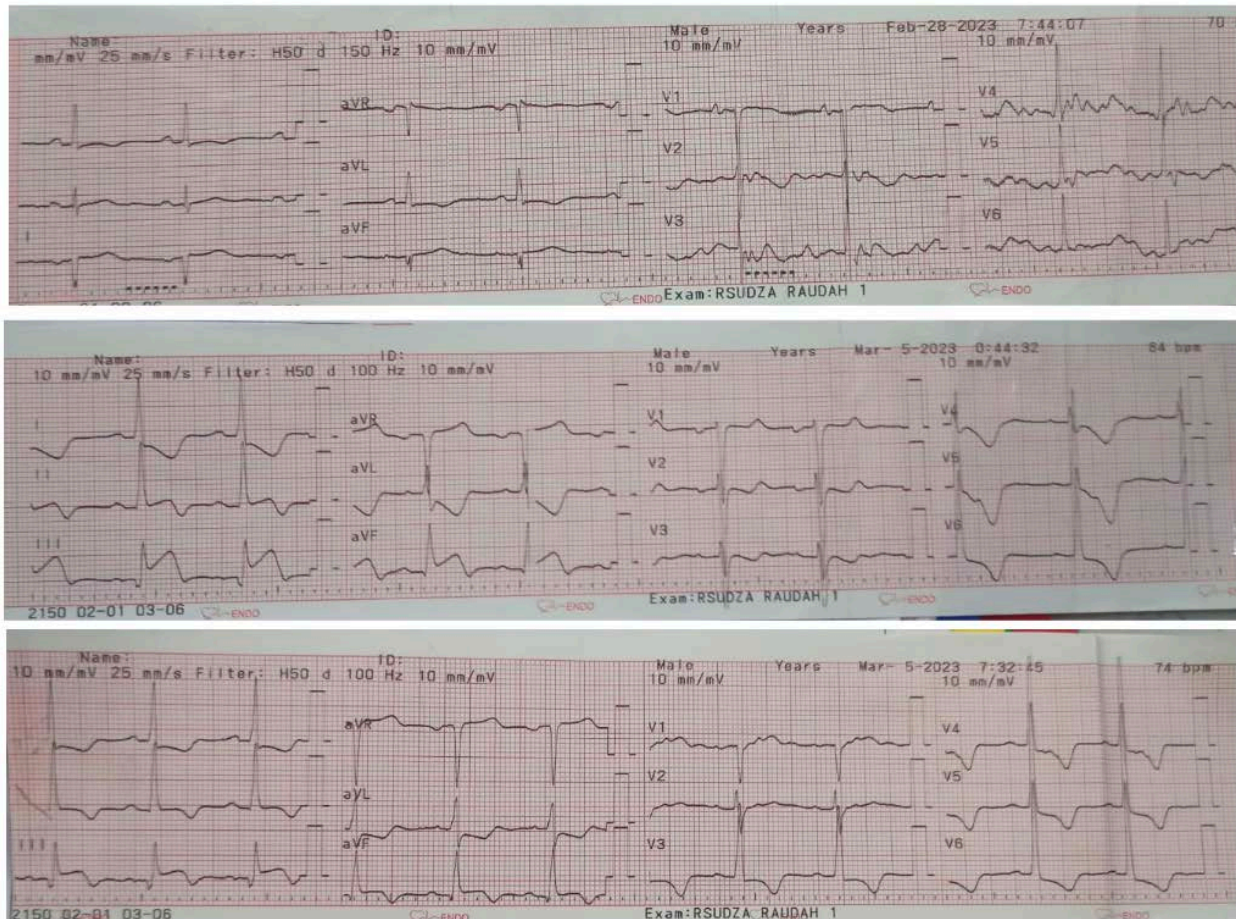


Figure 1. ECG at admission (above), ECG post PCI showing STEMI Inferior (Middle), and ECG 1 hour after fibrinolytic (below).



PERCUTANEOUS CORONARY INTERVENTION MANAGEMENT WITH THE BUDDY WIRE TECHNIQUE, A SOLUTION TO SEVERAL CHALLENGING CIRCUMSTANCES: A CASE REPORT

R. Novia¹, H. Munirwan²

1) Faculty of Medicine, Universitas Syiah Kuala 2) Department of Cardiology and Vascular Medicine, Faculty of Medicine, Universitas Syiah Kuala, Zainoel Abidin General Hospital, Banda Aceh, Indonesia

Background: Percutaneous coronary intervention (PCI) as an invasive strategy has increased in use and reduced the mortality rate to ischemic heart disease from 17.2% (1995) to 6.3% (2015). Not all cases can be easily carried out PCI; occasionally, the operator will face problems during complex lesions.

Case Illustration: A 60-year-old man was brought to the ED with a chief complaint of chest pain three days earlier. ECG showed complete RBBB, QS patterns in II, III, and AVF. Increased cardiac enzymes and decreased renal function in the laboratory. Echocardiography showed decreased LV function. An early invasive strategy performed, puncture through the dextra radial artery. Coronary angiography results; CTO of proximal RCA and distal LCx, 80-90% diffuse stenosis of proximal-distal LAD with severe calcification. PCI is conducted on the LAD, as it provides flow to the distal RCA. Balloon support was needed to allow the wire to penetrate the lesion, and coronary dilatation with a 2.5/12mm NC balloon to a pressure of 20 atm repeatedly. However, the stent could not pass through the lesion to the distal LAD. Stenting was performed first at the proximal LAD using a DES 2.75/29mm was inflated to a pressure of 16 ATM. Finally, a buddy wire technique was performed to stent the distal LAD, using a DES 2.5/16mm inflated to a pressure of 18 ATM. With results, TIMI 3 flow and stable hemodynamics. The patient was discharged in good condition with improved LV function and increased renal function. The method using a second 0.014-inch coronary guide wire can assist in delivering balloons and stents through calcified or tortuous vessels. It delivered through radial access is also safe, switching access to femoral is unnecessary.

Conclusion: The buddy wire technique is one of the simple solutions in assisting stent deployment in challenging situations, therefore improving PCI success.

Keywords: Buddy wire technique, PCI, Complex lesion.

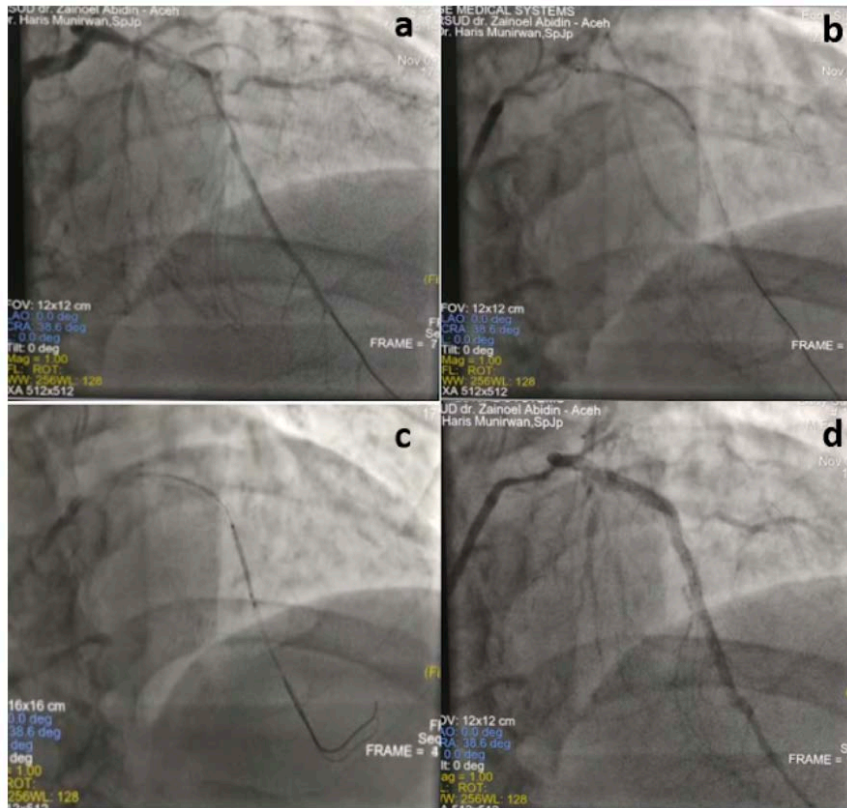



Figure 1 a. Diffuse stenosis of the LAD with severe calcification, b. stenting of the proximal LAD is carried out, c. Use of Buddy wire technique for mid-distal LAD stenting, d. TIMI 3 Flow final result.



Cardiac Magnetic Resonance to diagnose Coronary Microvascular dysfunction with chronic myocarditis

N. Widasari^{1,2}, T. Heriansyah¹, M. Muqsith¹, Elen²

¹Department of Cardiology and Vascular Medicine Universitas Syiah Kuala, Banda Aceh, Indonesia,

²Department of Cardiology and Vascular Medicine Universitas Indonesia/National Cardiovascular Centre Harapan Kita, Jakarta, Indonesia

Introduction

Microvascular dysfunction is responsible for chest pain in various clinical setting. Over 50% of symptomatic patients without flow-limiting coronary lesions have structural or functional abnormalities of the coronary microcirculation leading to impaired vasodilatation, which contributes to myocardial ischemia. In recent years, cardiovascular magnetic resonance have demonstrated to be emerging modalities for microcirculation assessment.

Case Illustration

A 72 years-old woman has been presented with frequent exertional chest pain since the last 2 months. Patient was breast cancer survivor with previous mastectomy and chemotherapy procedure 10 years ago. She also had history of hypertension. Coronary angiography revealed moderate stenosis on mid LAD, normal on other coronary arteries. CMR examination found hypokinetic at apico-anterior, basal apico-septal and basal apico inferior segments. Comparing rest and stress CMR sequences, there is a diffuse hypoperfusion at basal-apical LV on stress sequences. Intramyocardial LGE were found at basal-apico anterior, basal-mid septal, basal-mid inferior and basal inferolateral.

Coronary microvascular dysfunction is defined as the clinical syndrome of angina with electrocardiographic ischemic changes in the absence of obstructive CAD. Microvascular dysfunction (MVD) are divided into four clinical setting, MVD without obstructive CAD and myocardial diseases, MVD in myocardial disease, MVD in obstructive CAD, and iatrogenic. The etiology of myocardial inflammation include viral infection, post mRNA COVID-19 vaccination, and anthracycline used as chemotherapy regiment. Anthracycline-induced cardiotoxicity and subsequent heart failure is very common in breast cancer patients. Control of traditional CV risk factors is the main therapeutic objective to prevent progression of microvascular disease and to reduce the frequency and intensity of ischemic symptoms.

Conclusion

CMR has shown promising results to distinguish epicardial versus microvascular impairment compared to invasive FFR assessment. Identification of MVD is important to manage medical strategies and improve prognosis.

Keywords: Microvascular dysfunction, Myocarditis, CMR



Acute Heart Failure Caused by TR Severe and AF RVR with Congenitally Corrected Transposition of Great Arteries – A Case Report

Y.I. Taufik¹, R.M. Tamba², K.K. Ilyas³, A.N. Nasution⁴, C.A. Andra⁵

^{1,2}Cardiology Resident, Department of Cardiology and Vascular Medicine, Faculty of Medicine, Universitas Sumatera Utara, Medan, Indonesia

^{3,4,5}Cardiologist, Department of Cardiology and Vascular Medicine, Faculty of Medicine, Universitas Sumatera Utara, Medan, Indonesia

Background

Acute heart failure refers to rapid onset or worsening of symptoms and/or signs of heart failure, requiring urgent evaluation and treatment. Heart failure results from disturbances in the structure and/or function of the heart resulting in increased intracardiac pressure and/or inadequate cardiac output. Disorders of the valves, pericardium, endocardium and disturbances of heart rhythm and conduction can also contribute to causing heart failure. Congenitally Corrected Transposition of Great Artery or CCTGA both ventricles (pumping chambers) of the heart are reversed. Fortunately, the arteries are reversed too, so the heart actually "corrects" the abnormal development, thus the name "congenitally corrected transposition of the great arteries." However, CCTGA is a complex malformation in which the heart is far from being normal.

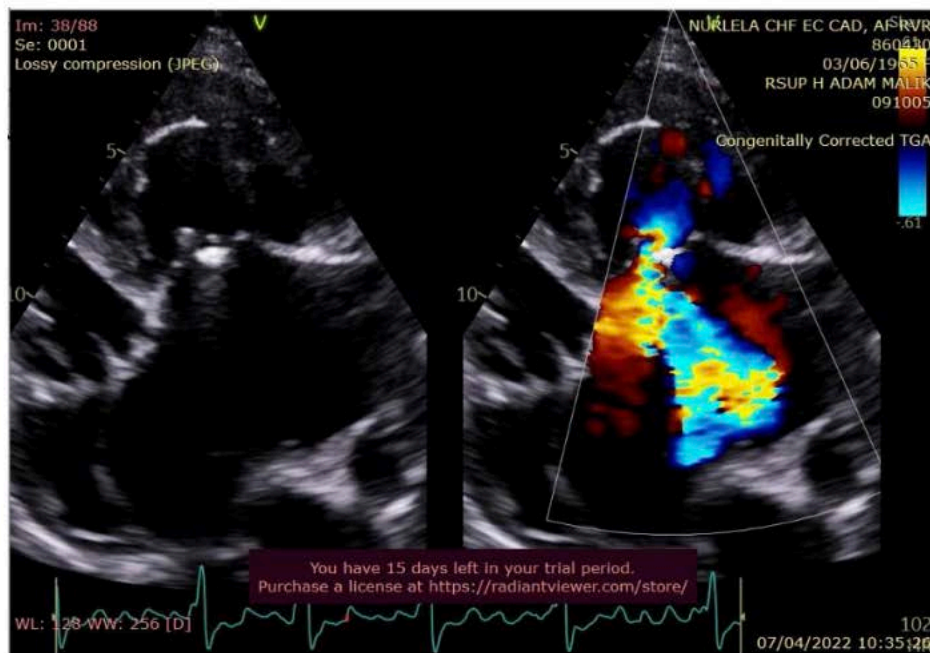
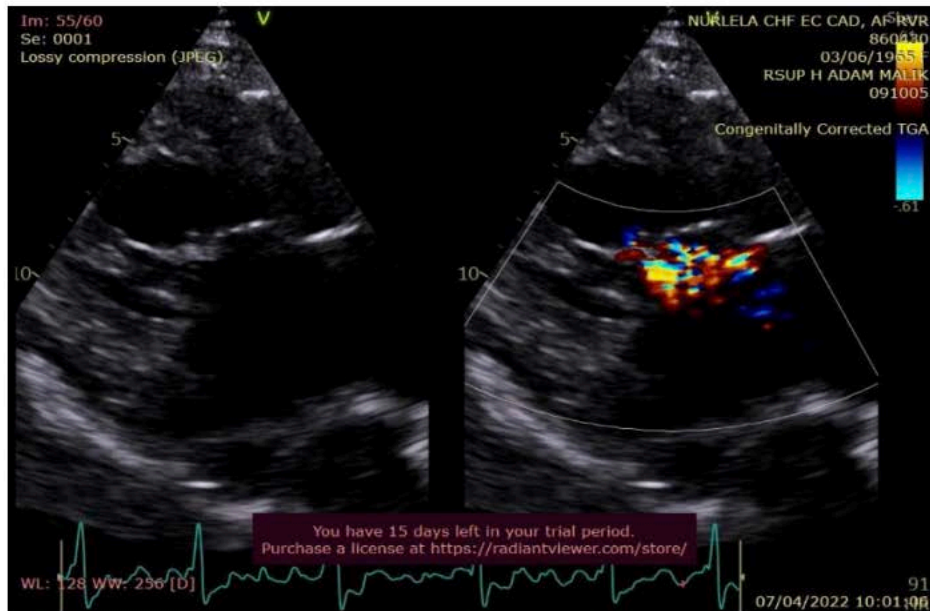
Case Illustration


Women, 56 years old, came with complaints of shortness of breath that felt even during light activity and at rest. The patient admits that he often wakes up at night due to shortness of breath and has to use 2-3 pillows to sleep. DOE (+), OP (+), PND (+). Complaints are also accompanied by swollen feet. On physical examination, an increase in jugular venous pressure is found as high as R+3 cmH₂O. On physical examination of the heart, there was irregular heart sound 1 and 2, accompanied by a murmur at the lower left sternal border which was difficult to assess, with a maximum punctum at LPAS. ECG results found atrial fibrillation rhythm with QRS rate 133x/i irregular, left anterior deviation, P wave difficult to assess, QRS duration 80 ms, Q path gel in III, avF, V1-V4, ST-T changes: T-inversion in I, avL. Impression: AF RVR + LAD. On the chest X-ray, a CTR of 76% was found, the Aortic segment was normal, Echocardiography results found: Atrial situs solitus, AV discordance, VA discordance, TR severe (PG 80 mmHg) and LA-RV dilatation. Patients were given treatment in the form of complete rest, IVFD NaCl 0.9% 10 tpm, inj furosemide 40 mg/8 hours, Spironolactone 1x25 mg, Digoxin 1x0.25 mg, Warfarin (2-3-2 mg), KSR 1x600 mg.

Conclusion

Woman, 56 years old, diagnosed with Acute Heart Failure caused by severe TR and AF RVR with congenitally corrected transposition of great arteries based on history, physical examination and additional examinations. The patient was given therapy according to clinical manifestation and allowed to go home after 7 days of treatment.

Keywords: Acute heart failure, Atrial fibrillation, CCTGA





Post Procedural Complication after PPM Implantation : What should we do.

S.S. Baskoro¹, T. Aryanugraha¹, M.A. Rosyidi¹, M. Herbani¹, I. Kamelia¹, S. Anjarwani², A. Rizal², A. Kurniawan¹,
F. Taufiq¹

¹Cardiology Resident, Faculty of Medicine Universitas Brawijaya- Saiful Anwar Hospital, Malang, Indonesia;

²Departement of Cardiovascular Medicine, Faculty of Medicine Universitas Brawijaya-Saiful Anwar Hospital, Malang, Indonesia

BACKGROUND

Permanent Pacemaker implantation is a lifesaving procedure usually used in conditions of life-threatening bradycardia. Permanent Pacemaker (PPM) was associated with more favorable outcome in patients with cardiac conduction issues. However, the procedure of PPM implantation still resulted in operative associated complication, from superficial hematoma, until pneumothorax and lead dislodgement, several of these complications might resulted in mortality Associated with PPM implantation. In this paper we presented a case in-hospital monitoring for the patient underwent complication after PPM implantation.

CASE ILLUSTRATION

A 62-year-old woman with chief complaint of syncope. Patient was having seizure multiple times on observation. From ECG was found with Total Atrioventricular Block (TAVB) with junctional escape rhythm and heart rate (HR) of 30-40 beats per minute (bpm). Due to unavailability of temporary or percutaneous pacemaker in the receiving hospital, epinephrine was used to increase the heart rate. After received in our hospital, patient was implanted with intravenous Temporary Pacemaker and previously administered epinephrine was stopped.

Patient was in stable condition with BP 131/75 mmHg, HR 70x/m regular, and had insertion temporary pacemaker (TPM) at 70-5-3 configuration. Subsequent Work up ruled out electrolyte abnormalities (Hypo-hyperkalemia), and there was no regional wall motion abnormality from echocardiography and also no risk factor of coronary artery disease (CAD). Due to lack of apparent reversible causes, medical team decided on PPM implantation. The procedure was done without complication. However, at recovery room, she complained of typical chest pain, shortness of breath accompanied with hypotension (77/54 mmHg with HR 60 bpm appropriate RV pacing rhythm). Her acral was cold and wet. Echocardiography evaluation showed appropriate lead placement with minimal pericardial effusion and no sign of pneumothorax. There was no sign of tamponade. Sublingual Nitrate and Fluid resuscitation was given to the patient. The symptom was reduced, and her blood pressure slowly recovered. She was observed in the ward and discharged 3 days after.

CONCLUSION

PPM implantation Is one of the core treatments for symptomatic bradycardia. Although its generally a safe procedure, complication regarding PPM Procedure needed to be anticipated in order to be treated accordingly. A close monitoring with trained personnel on standby is crucial to ensure patients well being after PPM implantation.




Indonesian Journal of Cardiology

Indonesian J Cardiol 2023;44:suppl_A
pISSN: 2830-3105 / eISSN: 2964-7304
doi: 10.30701/ijc.1537

KEYWORDS

Total Atrioventricular Block (TAVB), Permanent pacemaker, post procedural monitoring



Flaring Osteal to Bail Out Proximal RCA Dissection during CTO PCI: A Case Report

R.S. Bakry¹, H. Munirwan¹, T. Heriansyah¹

¹Department of Cardiology and Vascular Medicine, Faculty of Medicine, Universitas Syiah Kuala, Banda Aceh, Indonesia

Background: The separation between two layers of coronary artery is recognized as coronary dissection. Deep engagement during catheter manipulation can induce an iatrogenic coronary dissection. Although the reported incidence was quietly few, 0.02-0.15%, it can be life threatening and need prompt surgery. Dissection in ostium RCA is more frequent than LCA with percentage 85% of all.

Case Illustration: We reported a 57 years old age male with CAD 3VD post PCI 1 DES in LAD. Patient came for undergoing elective PCI. He has suffered chest pain during mild activities for last 6 months. His cardiovascular risk factor were hypertension and smoking. Physical examination revealed no abnormalities. ECG showed sinus rythm with rate 66 bpm, normoaxis, qs pattern in lead III aVF, and poor r wave progression in V1-4. We performed CTO PCI through femoral access. Angiography showed patent stent in LAD, diffuse stenosis 90% in osteal to distal LCx, and CTO with calcification in proximal RCA. Operator decided to perform CTO PCI in Proximal RCA using AL1 guide-catheter. During procedure, the dissection was occurred in proximal RCA. We performed flaring the ostium using noncompliant balloon, protruding into the aorta flare the aortic portion of the stent using the stent balloon. Then, the angiography showed that RCA dissection was improved. The results of PCI were CAD 3VD + Stent patent in LAD and PCI 2DES in RCA.

Conclusion: Flaring stent in the ostium of RCA by inflating balloon proximal to dissected segment was necessary for tack down the dissection flap resulting in flow improvement. It can be a solution for bailing out under the circumstances.

Keyword: Flaring Osteal, CTO PCI, Coronary Dissection

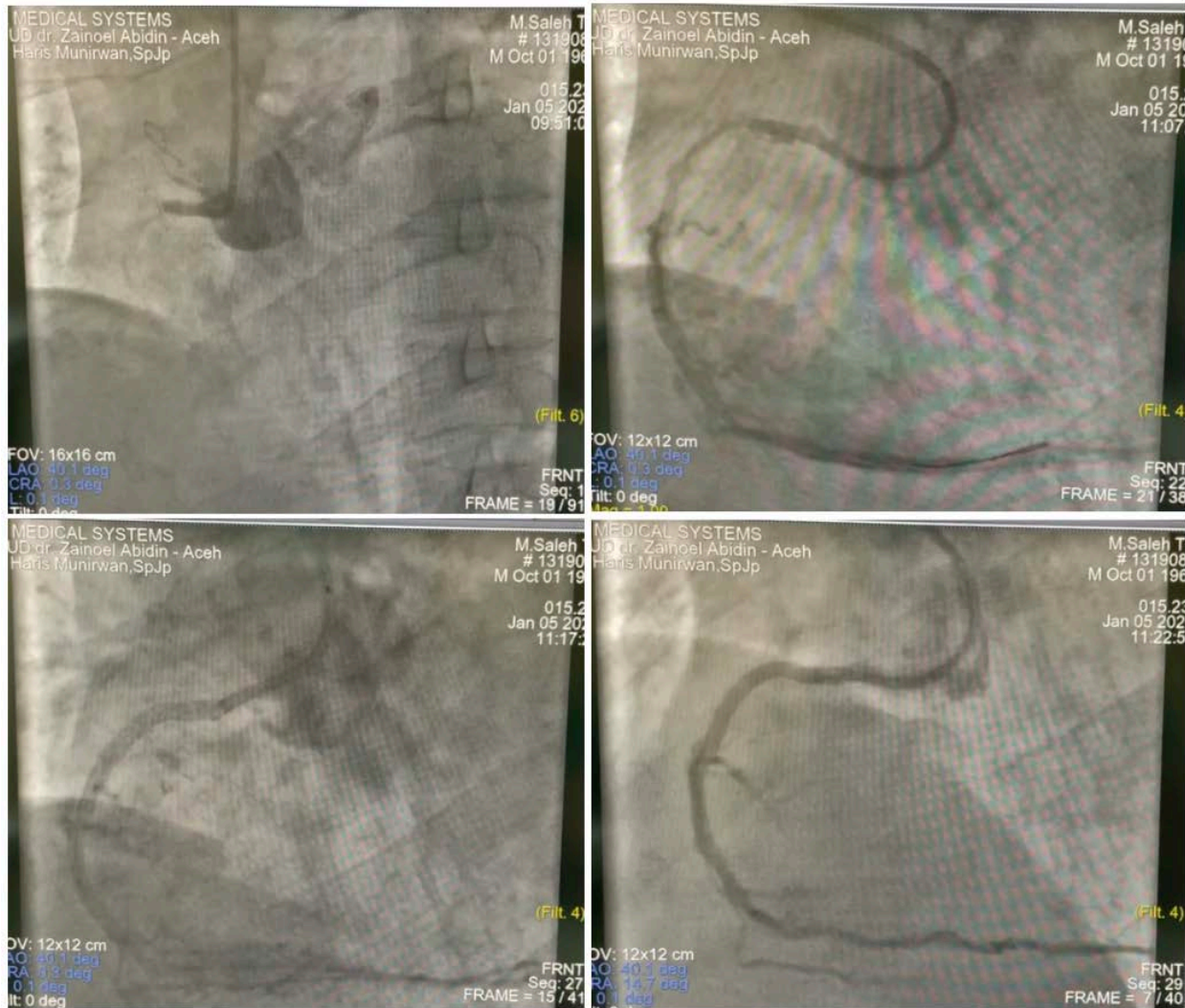


Figure 1. CTO in Proximal RCA with JCTO score 3, (A). Dissection In Proximal RCA, (B). Stenting in osteal-proximal RCA, (C). TIMI 3 Flow after flaring balloon in osteal RCA, (D).



Transcatheter Post Infarct VSR Closure Using ASD Device : An Alternative Option in Scarcity

A.M.A.A. Lubis¹, A.C. Lubis², A.N. Nasution³, C.A. Andra⁴, T.W. Ardini⁵, K.K. Ilyas⁶


¹Cardiology Resident, Department of Cardiology and Vascular Medicine, Faculty of Medicine, Universitas Sumatera Utara, Medan, Indonesia; ^{2,3,4,5,6}Cardiologist, Department of Cardiology and Vascular Medicine, Faculty of Medicine, Universitas Sumatera Utara, Medan, Indonesia

Background: Transmural MI is a predisposition for ventricular septal rupture which occurs more frequently after STEMI than NSTEMI. Without surgical repair or percutaneous closure, the mortality rate can reach 94%. Although surgical repair has been the gold standard to correct the structural anomaly, percutaneous closure may represent a valuable therapeutic alternative in selected patient, with the purpose of immediate shunt reduction to prevent further hemodynamic deterioration.

Case Illustration: A 60 – year – old woman with post infarction ventricular septal rupture and recent anterolateral STEMI was referred from Lhokseumawe with dyspnea as chief complaint which had been experienced for seventeen days before admission. At first, she refused a referral and eventually came with complicating pneumonia. She was admitted to the ICCU without hemodynamic instability and treated with afterload reduction strategy by using vasodilator. The CAG revealed a total occlusion in LAD after D2 and 70 – 80% stenosis in LCX after OM1. The left ventriculography showed VSR (Ø8 mm), L-R shunt. The TTE revealed a ventricular septal rupture Ø 6 x 12 mm. On the 21st day of the PI – VSR, she underwent a TEE and fluoroscopy guided transcatheter closure using the *ASO Occlutech* device No. 18 mm. The TEE showed that the device was well positioned with minimal central leakage. Shortly after the closure, the cardiac performance improved, proven by an increase of LVOT VTI from 6.3 cm to 13 cm. The patient then moved to the ward two days after the procedure. During the follow up, the patient unfortunately died of *Pseudomonas aeruginosa* infection four days after the closure despite a successful procedure and hemodynamic improvement.

Conclusion: It is not yet clear which device is the best option for the treatment of a VSR due to anatomical difference. The P.I. Muscular VSD Occluder was specifically designed for postinfarction VSD closure. However, when it is not available, other device can become an alternative.

Keyword : PI VSR, Transcatheter Closure



Dual Stent Strategy in Management of Bifurcation Lesion

C. Kurniawan¹, H.W. Rawung¹, S.H. Rampengan¹

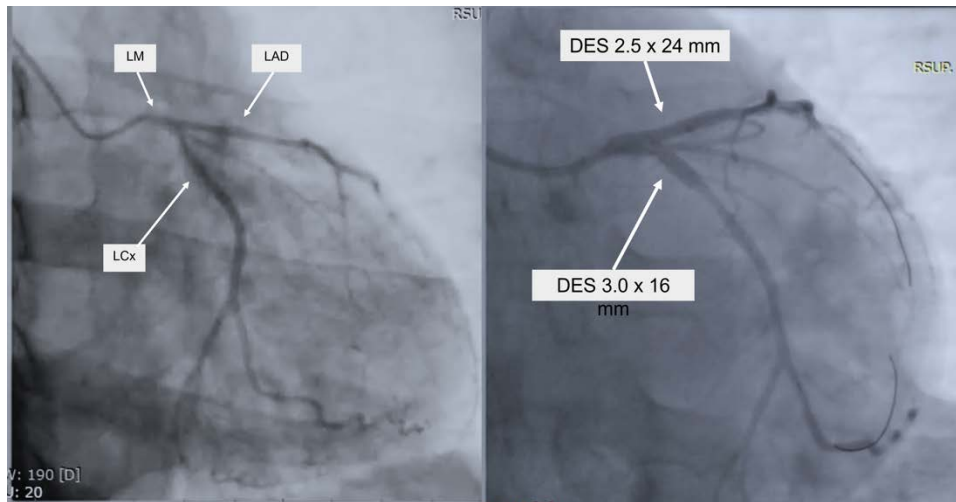
¹Department of Cardiology and Vascular Medicine, Faculty of Medicine, Sam Ratulangi University, Manado

Background: Complex coronary lesions are frequently found and present with higher complication rates. Complex lesion include bifurcation lesion, calcified lesion, chronic total occlusion, left main coronary artery lesion, and ostial lesion. There are many different ways in managing a bifurcation lesion, and a standard guidance is not yet found.

Case illustration: A male patient, 49 years old, was admitted with chief complaint of episodic chest pain with typical angina quality. Patient had a history of dyslipidemia, hypertension, and was a heavy smoker. Echocardiography 1 week prior show good left ventricular function. Treadmill test show positive ischemic response with high risk features. Laboratory examination show slightly increased LDL (102 mg/dL) and no remarkable increase in cardiac enzyme. ECG show T inversion in I and aVL. Chest X-ray was within normal limits. Based on history taking, physical examination, and diagnostic studies, patient was diagnosed with stable angina pectoris Canadian Cardiovascular Society (CCS) classification II-III, dyslipidemia, and hypertension. During the fourth day of admission, patient undergo coronary angiography revealing distal discrete stenosis 60% in Left Main (LM) with bifurcation lesion (medina 1-1-1), diffuse stenosis Left Anterior Descending (LAD) 90% ostial-proximal, diffuse stenosis Left Circumflex (LCx) 70-80% ostial-proximal, and normal RCA. Because of stenosis in LAD and LCx $\geq 50\%$ with diameter ≥ 2.75 mm, dual stent strategy was chosen for this patient, in which stenting were done in main and side branches simultaneously. Patient had 2 stent implanted in LM-LAD and LM-LCx. Angiographic evaluation reveal TIMI Flow 3, no residual thrombus.

Conclusion: Bifurcation lesion is a complex lesion with high complication during PCI procedure. Dual stent strategy is shown to be a safe technique in this case report, with acceptable long-term prognosis.

Keywords: CHD, bifurcation lesion, PCI



Rupture of Large Aortic Root Aneurysm Presenting as Acute Coronary Syndrome: The Importance of Triple Rule Out Computed Tomography

F.A. Sihotang¹, V. Mayangsari², S. Anjarwani², N. Kurnianingsih²

¹Resident of Cardiology and Vascular Medicine, Faculty of Medicine Universitas Brawijaya, Malang, Indonesia


²Department of Cardiology and Vascular Medicine, Saiful Anwar General Hospital, Malang, Indonesia

Introduction

Chest pain is a common complaint in the emergency department that prompts accurate diagnosis and treatment. Aortic dissection (AD) and non-ST segment elevation acute coronary syndrome (ACS) are two of the most life-threatening diseases encountered in the emergency department that presented with chest pain. The failure in differentiating the two might result in improper and potentially harmful treatment. Here we presented a case of patient with acute chest pain diagnosed with ACS that turned out to be a large aortic root aneurysm with impending rupture.

Case Illustrations

A 45-year old man with risk factors of active smoker and history of alcohol consumption presented to ER with acute de novo chest pain that occurred while the patient was resting accompanied with palpitation. At the ER, patient was tachycardic with electrocardiogram demonstrated a narrow complex tachycardia of 185 bpm suggestive of atrioventricular re-entry tachycardia. Patient was given electrical cardioversion and returned to sinus rhythm with ST elevation at aVR and ST depression at I, II, aVF, V4-V6 suggestive of very high risk NSTEMI and WPW pattern suggestive of right anteroseptal accessory pathway. An invasive strategy was performed that surprisingly demonstrated a normal coronary angiography. Echocardiography showed an aortic root aneurysm with moderate to severe aortic regurgitation without intimal flap and reduced left



ventricular ejection fraction. A CT-angiography of the aorta was suggestive of impending rupture of aneurysm. Patient was treated conservatively and was planned for referral to higher centre for surgical management of the aortic root aneurysm. Unfortunately, on the fifth day of care, an acute type A aortic dissection that extent superiorly to the carotid and inferiorly to the iliac occurred. Patient went into hypovolemic shock, oliguria and later acute lung oedema of cardiac type occurred. Breathing was managed with non-invasive ventilation and when the respiratory failure became severe and patient was planned for invasive ventilation, he went into cardiac arrest with unsuccessful resuscitation.


Discussion

In the setting of very high risk NSTEMI/ACS, the need of immediate revascularization is of utmost importance. However, this case demonstrated that aortic aneurysm can be falsely diagnosed as ACS; with the two are very different in the terms of treatment approach. Triple rule out computed tomography (TRO-CT) that noninvasively evaluates the coronary circulation, pulmonary arteries and thoracic aorta within a single scan might be of value in this scenario.

Summary

Triple rule out computed tomography (TRO-CT) should be considered in cases where the diagnosis of acute coronary syndrome and aortic dissection cannot be differentiated from clinical presentation and standard diagnostic tests.

Keywords: *acute coronary syndrome, aortic dissection, triple rule out CT*



Echocardiography Found Pulmonary Hypertension, Eisenmenger Syndrome in Adult Woman with Diminished Signs of Patent Ductus Arteriosus: A Case Report

R. Hilman¹, Novita¹, T. Heriansyah¹, M. Muqsith¹

¹ Department of Cardiology and Vascular Medicine, Medical Faculty, Syiah Kuala University

Background: Patent Ductus Arteriosus is common congenital heart disease, commonly recognized and treated in childhood. However, 2% CHD patients did survive to adulthood undiagnosed. Prolonged patency of ductus arteriosus will cause pulmonary artery remodelling lead to pulmonary arterial hypertension and further into Eisenmenger Syndrome. In Eisenmenger Syndrome murmur, disappeared causing difficulty in diagnosis. Echocardiography can assess pulmonal hypertension severity, and PDA flow, since PDA closure might beneficial in pulmonary arterial hypertension setting, while not in Eisenmenger Syndrome.

Case Illustration: A 29 years old women came to outpatient clinic with complain shortness of breath since 10 years ago and gradually worsen, and patient sometimes became cyanotic during exertion. Patient catch a cold often since her childhood and her symptoms got worsen during cold. The patient was the 7th alive child in her family, her mother experienced natural abortion 3 times. She was born during her mother 7th months of pregnancy. Physical examination found clubbing finger and no murmur was heard. ECG found incomplete RBBB with right axis deviation. Chest X-ray found increased vascularization in the central and widened intercostal space. Echocardiographic assessment found PDA bidirectional shunt, dominant right to left shunt with normal LV systolic and diastolic function, normal RV function and normal cardiac dimension. Pulmonary pressure was calculated by estimating systolic and diastolic pressure gradient with CW doppler and substracting this value from systemic systolic and diastolic pressure, Pulmonary pressure was found 117/65 mmHg which suggest severe pulmonary hypertension. Qp:Qs was 0.49 which represent Eisenmenger Syndrome.

Conclusion: The presence of PDA was very obscured in this patient, because of the Eisenmenger syndrome, murmur was no longer heard. Without TTE, we could only notice the presence of cyanotic heart disease with pulmonary hypertension. Transthoracic echocardiography is reliable in finding congenital heart defect and its possibility for correction.

Keyword: Adult Patent Ductus Arteriosus, Eisenmenger Syndrome, Pulmonary Hypertension, Transthoracic Echocardiography.

Undetected Large Patent Ductus Arteriosus from Transthoracic Echo

I.G.B.B Wijaksana¹, L.O.S Suastika², N.L.M.A.W Sari²

I. B.R. Wibhuti², M.S.Y. Dewangga² E. Gunawijaya², N. P.V.K Yantie²

Faculty of Medicine, Udayana University, Bali, Indonesia

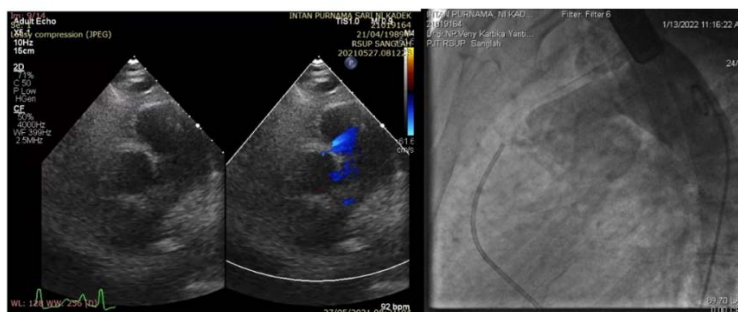
Prof. dr. I.G.N.G Ngoerah, Bali, Indonesia General Hospital

Background: Patent ductus arteriosus (PDA) presents as a persistent communication between the proximal descending aorta and the roof of the main pulmonary artery. Late presenting large PDA is a rare finding and could be undetected from initial transthoracic echocardiography (TTE).

Case Illustration: We present a 32 y.o women with dyspnea on effort and orthopnea increasing in the past year. She had history of heart disease since childhood but did not seek medical attention. She had physical examination significant for differential cyanosis. ECG showed SR, RAE, RVH and T Inversion inferior and anterior leads. Chest X-ray showed cardiomegaly and signs of pulmonary conus dilatation. TTE showed RV dilatation, Mild MR, Mild TR with high probability of PH, Global hypokinetic with decreased LV and RV systolic function (EF BP 36.8% TAPSE 16 mm) and small muscular VSD with bidirectional shunt. Our working diagnosis was RHF caused by PH caused by suspected PDA, but no PDA was visible from initial TTE. Our next diagnostic approach was heart catheterization due to unavailability of CT scan at the time and to evaluate hemodynamic and feasibility of defect closure. Aortography revealed a large type A1 PDA with isthmus of 17 mm. Hemodynamic studies showed high pulmonary vascular resistance (PARI 24 WU.m2) which improved to 9 WU.m2 after acute vasoreactivity testing. PDA closure using ASO no 24 was successfully performed. Difficulty in PDA visualization from echocardiography could be explained by high PA pressure and resistance, poor echo view, or anatomic variation. In cases of conflicting clinical and TTE findings, heart catheterization (aortography) can be considered.

Conclusion: TTE evaluation of PDA in late stages of presentation could be difficult. Differential cyanosis and unexplained signs of PH could be used as a clinical clue. Heart catheterization can be considered in cases with conflicting clinical and TTE findings

Keywords: *Patent Ductus Arteriosus, Differential Cyanosis, Transthoracic echo*



Initial TTE showing no PDA from PSAX view meanwhile heart catheterization at LAO 90°, Cranial 0° showing large PDA